

Case Report

Misinterpretation of Hypostasis Does not Identify Death from Carbon Monoxide Poisoning and Does not Avoid another Five Deaths

Ivan Dieb Miziara¹, Renata Schwed Razaboni^{2*},
Carmen Silvia Molleis Galego Miziara³,
Wagner dos Santos Moraes⁴, Helio Rodrigues
Ramacciotti⁵, Ana Cristina Mielli⁶, Vilma Leyton⁷
and Daniel Romero Muñoz⁸

¹Associate Professor - Department of Legal Medicine, Medical Ethics, Social Medicine and Occupational Health, University of Sao Paulo, Brazil

²Resident - Medical Residency in Legal Medicine and Medical Expertise, Faculty of Medicine, University of Sao Paulo, Brazil

³Assistant Professor - Discipline of Legal Medicine and Bioethics, ABC School of Medicine, Santo André, Brazil

⁴Coroner - Institute of Legal Medicine of Sao Paulo, Brazil

⁵Forensic Expert - Scientific Police of Sao Paulo, Brazil

⁶Biologist - Laboratory of Toxicology in the Department of Legal Medicine, Medical Ethics, Social Medicine and Occupational Health, University of Sao Paulo, Brazil

⁷Associate Professor - Department of Legal Medicine, Medical Ethics, Social Medicine and Occupational Health, University of Sao Paulo, Brazil

⁸Chairman - Department of Legal Medicine, Medical Ethics, Social Medicine and Occupational Health, University of Sao Paulo, Brazil

*Corresponding author: Renata S. Razaboni, Faculty of Medicine, University of Sao Paulo, Brazil, Email: renata.razaboni@uol.com.br

Received: March 12, 2015; Accepted: June 21, 2015;

Published: June 30, 2015

Abstract

This article aims to describe the deaths of six people from the same family due to monoxide carbon (CO) poisoning caused by the failure of the heater exhaust equipment to gas. The diagnosis was confirmed by autopsy at the Institute of Legal Medicine of Sao Paulo, and the carboxyhemoglobin (COHb) levels were determined by spectrophotometric method. The six autopsies were from the same family and had only hypostases with a red carmine color. The results of COHb determination were: 84%, 88%, 94%, 87% and 88%. CO poisoning is the leading cause of death by poisoning worldwide. In order to suspect CO poisoning, in the presence of deaths with an apparent undetermined cause even without the presence of a suggestive history of exposure to CO, the medical examiner should question the family about the possibility of abnormal exposure of CO. In addition to searching for other physical changes associated with this context, the professional should request laboratory determinations of this compound.

Introduction

Carbon monoxide (CO) is a colorless, odorless, and nonirritant toxic gas produced by the incomplete combustion of hydrocarbons, and can be found in the exhaust gases of motor vehicles, inadequate heating systems, and fires [1,2,3]. In the body, CO is a byproduct of oxidative catabolism of the heme complex by heme oxygenase enzymes; CO acts as a neuromodulator and regulates cell proliferation, platelet aggregation, and apoptosis [4].

Inhaled exogenous CO diffuses through pulmonary capillaries and, given its high affinity for hemoglobin, forms the carboxyhemoglobin (COHb) complex. This complex reduces the ability of hemoglobin to transport oxygen (O₂), which leads to tissue hypoxia [5].

Several lesions and clinical manifestations result from exposure to CO, including headaches, irritability, blurred vision [3], cognitive impairment [6], urinary incontinence, agnosia, ataxia, apraxia, epilepsy, amnesia, seizures, coma [7,5], and neurological sequelae [8, 9].

The indicated treatment for neurological symptoms or a concentration of COHb greater than 25% consists of exposure to 100% or hyperbaric oxygen, which facilitates the dissociation of CO from hemoglobin [10]. The ensuing autopsy findings after CO poisoning include blood fluidity, clear hypostasis, and organs with carmine red coloring [1].

This article aims to describe the deaths of six people from the same family due to CO poisoning caused by the failure of the heater exhaust equipment to gas. The diagnoses was confirmed by autopsy at the Institute of Legal Medicine of Sao Paulo, and the COHb levels were determined by spectrophotometric method, as previously described by [11] and modified by [12].

This study was approved by the Ethics Committee of Institute of Legal Medicine of Sao Paulo under number 022/14.

Case Series

Six people belonging to the same family (LPN, VCVS, CSL,

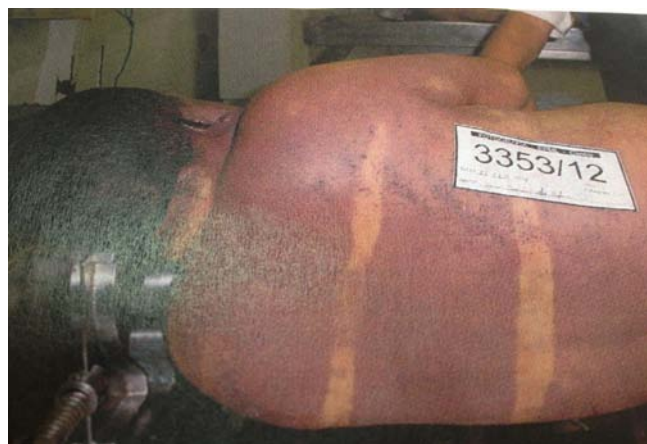

Figure 1: Hypostases with a red carmine color in dorsal region.

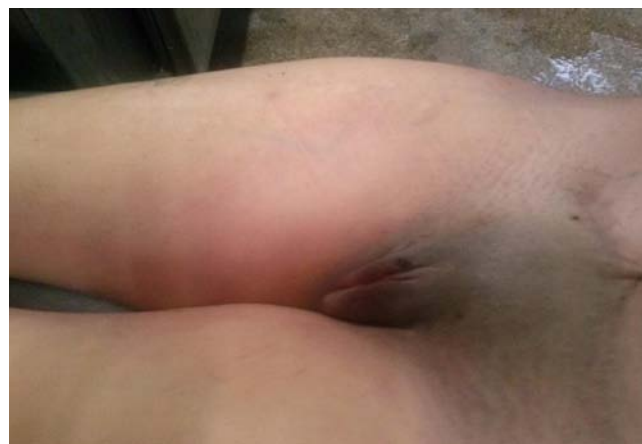


Figure 2: Hypostases with a red carmine color in inguinal region.

CDSL, KRSL, and DVS) were found dead in an apartment located in the suburb of Sao Paulo, Brazil.

The first death (LPN) occurred on August 16, 2013 on the bathroom floor of the apartment. An autopsy performed 12 hours post-mortem revealed no injury or changes in either the internal or external examination that would suggest an etiology. Consequently, the autopsy indicated the cause of death as unknown. The victim had no external signs suggestive of CO poisoning; only he had a slight pink color which was considered hypostasis.

Thirty days later (September 16, 2013), the other victims (five) were brought to the IML; according to the criminal report, they were found closely on the floor of an apartment room. The 5 autopsies were performed 14 hours postmortem, there were no descriptions of traumatic injury however; there were descriptions of focal cherry-red areas in various regions of the bodies. Some of these areas were found in dorsal region (Figure 1), upper and lower limbs, and in the inguinal region (Figure 2). The internal examination, there were no descriptions of the following changes: increased rigidity; higher blood fluidity; frothy secretions in the airways; signs of exposure to coal combustion (soot in the lower airways); hemorrhagic subcutaneous infiltration; visceral congestion; or pinkish vessels, muscles, and organs.

In the first autopsy, which occurred 30 days before the others, the attenuated manifestations of rosy coloring were cited only in the external examination and equated to the hypostasis; the family did not report on the possibility of exposure to the gas; the cause of death was established as unknown. However, the five deaths from the same family with the same descriptive characteristics raised the suspicion of intoxication, and a toxicological evaluation was requested. For the first autopsy (LN) the result of COHb determination was 70%, and in the other victims was: 84%, 88%, 94%, 87%, and 88% (VCVS, CSL, CDSL, KRSL, and DVS, respectively). In addition to determining COHb levels, a quantitative cyanide determination in all deceased blood samples were performed and yielded negative results.

According to the criminal report, the heater inside this family's apartment had several irregularities. The heater did not have an exhaust pipe for the combustion gases, the function of which would be to release the combustion gases outside of the apartment; in other



Figure 3: Gas heater.

words, in its absence, the gases were produced and released into the apartment. The heater was suitable for natural gas, but the domestic distribution network provided by the condominium used liquefied petroleum gas. This difference increased the output by 73% and as there was not enough surplus air to feed the burner, there was an increase in incomplete combustion, thus increasing the production of CO, carbon dioxide, and soot. Soot had impregnated the kitchen wall, indicating of the formation of CO (Figure 3). The assessment of the impregnated soot along with the draining pattern of condensed water from the ambient air indicated that all windows and doors of the apartment had been closed. Therefore, the evaluation of the autopsy and laboratory findings and the technical analysis of the inadequate heater, together with the confined environment, confirmed the finding that the victims succumbed to fatal CO poisoning.

Discussion

CO poisoning is the leading cause of death by poisoning worldwide [13] and as CO is an odorless, tasteless, and colorless agent; it is imperceptible to an exposed person [14]. According to [3], 140, 490 CO-related deaths occurred in 28 countries between 1980 and 2008; these deaths occurred predominantly in males aged 25–64 years [3]. CO exposure is caused by fires, burning wood stoves, confinement with released gases from fuel combustion, or defective heaters [15]. In this case report, the heater installation failure, making it impossible to exhaust gas was the cause of six deaths. Unfortunately, the first death, which occurred thirty days prior to the other five were not suspected

of the possibility of CO poisoning, since the external signals were not typical and there was no history of exposure to CO. Even without typical signs, the level of COHb was performed but the result did not arrive in time to prevent further deaths.

The 6 cases reported herein had high levels of COHb, with lowest and highest values of 70% (LPN) and 94% (CDSL), respectively; as there was a delay in diagnosing the first case of CO poisoning, the 70% value determined at 1 month post mortem was probably an underestimation.

Despite the high COHb concentrations, during the autopsy the only signs indicative of CO poisoning were the pinkish foci described in the external examination.

Conclusion

Therefore, in the presence of deaths with an apparent undetermined cause even without the presence of a suggestive history of exposure to CO the medical examiner should question the family about the possibility of abnormal exposure of CO. In addition to searching for other physical changes associated with this context, the professional should request laboratory determinations of this compound.

References

1. Dimaio DJ, Dimaio VJM. Carbon Monoxide Poisoning, in: Forensic Pathology; II Edition; Elsevier Science Publishing Co. Inc. New York. 2001: 389-398.
2. Prockop LD, Chichkova RI. Carbon monoxide intoxication: an updated review. *J Neurol Sci.* 2007; 262: 122-130.
3. Braubach M, Algoet A, Beaton M, Lauriou S, Héroux ME, Krzyzanowski M. Mortality associated with exposure to carbon monoxide in WHO European Member States. *Indoor Air.* 2013; 23: 115-125.
4. Szeremeta M, Petelska AD, Kotyńska J, Niemcunowicz-Janica A, Figaszewski ZA. The effect of fatal carbon monoxide poisoning on the surface charge of blood cells. *J Membr Biol.* 2013; 246: 717-722.
5. Cetin M, Ornek E, Murat SN, Cetin ZG, Oksuz F, Gokcen E. A case of carbon monoxide poisoning presenting with supraventricular tachycardia. *Intern Med.* 2011; 50: 2607-2609.
6. Gandini C, Prockop LD, Butera R, Locatelli C, Manzo L. Pallidoreticular-rubral brain damage on magnetic resonance imaging after carbon monoxide poisoning. *J Neuroimaging.* 2002; 12: 102-103.
7. Song IU, Chung SW. Chorea as the first neurological symptom of delayed encephalopathy after carbon monoxide intoxication. *Intern Med.* 2010; 49: 1037-1039.
8. Chang CC, Chang WN, Lui CC, Huang SH, Lee CC, Chen C, et al. Clinical significance of the pallidoreticular pathway in patients with carbon monoxide intoxication. *Brain.* 2011; 134: 3632-3646.
9. Adam J, Baulac M, Hauw JJ, Laplane D, Duyckaerts C. Behavioral symptoms after pallido-nigral lesions: a clinico-pathological case. *Neurocase.* 2008; 14: 125-130.
10. Lawson-Smith P, Jansen EC, Hilsted L, Hyldegaard O. Effect of hyperbaric oxygen therapy on whole blood cyanide concentrations in carbon monoxide intoxicated patients from fire accidents. *Scand J Trauma Resusc Emerg Med.* 2010; 18: 32.
11. Beutler E, West C. Simplified determination of carboxyhemoglobin. *Clin Chem.* 1984; 30: 871-874.
12. Luchini PD, Leyton JF, Strombeck Mde L, Ponce JC, Jesus Md, Leyton V. Validation of a spectrophotometric method for quantification of carboxyhemoglobin. *J Anal Toxicol.* 2009; 33: 540-544.
13. Hampson NB. Trends in the incidence of carbon monoxide poisoning in the United States. *Am J Emerg Med.* 2005; 23: 838-841.
14. Varon J, Marik PE, Fromm RE Jr, Gueler A. Carbon monoxide poisoning: a review for clinicians. *J Emerg Med.* 1999; 17: 87-93.
15. De-Giorgio F, Grassi VM, Miscusi M, Mancuso C, d'Aloja E, Pascali VL. Subarachnoid hemorrhage and carbon monoxide exposure: accidental association or fatal link? *J Forensic Sci.* 2013; 58: 1364-1366.