

Review Article

Flatfoot in Children: A Review of Literature (Point of View)

Bernardino S*

Department of Orthopaedic and Trauma Surgery, ASL Bari, Italy

***Corresponding author: Bernardino S**

Department of Orthopaedic and Trauma Surgery, Orthopedics and Traumatology Clinic, ASL Bari, Italy

Received: February 01, 2023; **Accepted:** March 14, 2023; **Published:** March 21, 2023**Abstract**

Flatfoot (pes planus) is described as a reduction or absence of the Medial Longitudinal Arch (MLA) of the foot, with or without additional deformities of the foot and ankle. It is a very common orthopedic manifestation in infants and children and usually resolves by adolescence. Flatfoot is usually flexible and painless with no functional compromise so that described as physiologic.

In some rare cases flatfoot can become painful or rigid and may be a sign of pathology such as vertical talus or tarsal coalition.

Although it is very common, there is no standard definition and no universally accepted classification system for pediatric flatfoot.

Furthermore there are no large, prospective studies comparing the natural history of flatfoot in response to various treatments during the developmental period. Current literature suggests that it is safe and appropriate to simply observe an asymptomatic child with flatfoot. Painful flexible flatfoot may benefit from orthopedic intervention such as physical therapy, orthosis or sometimes a surgical procedure.

Keywords: Flatfoot; Children; Foot; Surgery; Child**Definition, Prevalence and Etiopathology**

Pes planus is defined as the flattening of the medial longitudinal arch of the foot that becomes evident with weight bearing. It is common in pediatric orthopedic clinics with the prevalence from 1% to 28% at certain age groups [1]. In most of the children normal longitudinal arch develops at 3-5 years of age and in only 4% of them flatfoot persists after 10 years of age. It is considered physiological as it usually resolves during adolescence. This is because it is generally flexible, painless and does not cause impaired functioning. Arches of the feet often develop with age; however, there is a wide range of normal variation. The shape of the medial arch is related to the shape of the bones and flexibility in the ligaments. All infants have pes planus at birth and the medial longitudinal arch may not be seen in the feet of healthy infants until 3 years of age.

With age, the development of the bones and joints and the strengthening of the ligaments form the medial arch. As an orthopedic terminological definition, pes planus is defined as co-existence of the following findings;

- Valgus of the hindfoot
- Disappearance of the medial longitudinal arch in the midfoot and
- Supination of the forefoot relative to the hindfoot while standing

Rigid pes planus is rare but usually starts from childhood; tarsal coalition, accessory navicular bone, congenital vertical talus, or other forms of congenital hindfoot pathology are usually the underlying factors.

In fact, the family's concerns about the shape of the foot and gait disturbance in the future are at the forefront rather than the child's complaint or clinical symptoms. Many studies indicate that the basic elements in the formation of the medial longitudinal arch are ligamentous and bony structures. Biomechanical studies have shown that the most important structure contributing to the stability of the medial arch is the plantar fascia, while other important structures are the talonavicular ligaments and the spring ligament [2]. The function of muscles in arc stabilization is still a controversial issue.

Classification

There is no universally accepted classification of the pes planus. Staheli had suggested to evaluate pes planus into two groups as physiological and pathological [3,4]. Physiological pes planus involves a developmental process. In this group, the foot is hypermobile due to the flexible talocalcaneal joint and is often not accompanied by Achilles tendon contracture. If joint hypermobility is accompanied by low muscle tone or ligamentous laxity, it is not considered physiologically. Pathological pes planus develops due to structurally rigid deformities such as vertical talus and tarsal coalition. In these cases, pes planus has been shown to be associated with significant gait abnormalities.

Assessment

A true history of the patient with pes planus should include:

- Developmental stages of the child, such as the age at which the child first stood and walked
- Pain in the feet or legs or easy fatigability
- Decrease in mobility, play and athletic performance such as running, jumping and hopping
- The presence of significant comorbidities or syndromes, which may be related to the presenting problem
- Family history of flat feet.

The physical examination should begin with gait pattern and then the inspection of the barefoot. It is important to examine the barefoot anteriorly, posteriorly and laterally; both while standing and during walking. Particular attention should be paid to evaluation of heel valgus, the foot progression angle and any rotational deformity [5-8]. Achilles tendon usually has a valgus angulation as it approaches the calcaneal insertion, as well as calcaneal valgus deformity. Hyperpronation of the foot can be demonstrated with the 'too many toes' sign. Usually the fifth digit and some of the fourth digit can be seen laterally when viewing the foot from behind; visibility of more toes indicates abduction and external rotation of the foot, which occurs with pes planus [6]. There may be navicular prominence anteroinferior to the medial malleolus (Figure 1).

If the medial longitudinal arch is flattened during loading at stance phase, but the patient forms a dynamic arch when standing up on their metatarsal heads, this indicates that the deformity is flexible flat foot. On the other hand if the arch does not form when standing up on the metatarsal heads, this indicates the restriction at the subtalar joint so that means rigid flat foot and may be associated with an underlying neuromuscular problem [8-10].

To differentiate between the two conditions (flexible and rigid) easily, following tests can be performed.

1. Tiptoe standing test: In flexible flatfoot, medial longitudinal arch of the foot collapses in various degrees during weight-bearing.

However during raising up one's body on tiptoe test foot arch forms again. When weight-bearing forces on feet are relieved this arch can be observed. If the foot is not bearing any weight, still medial longitudinal arch is not seen, then it is called rigid (fixed) flatfoot.

2. Jack's test: While the patient is standing, he or she puts weight on the foot with the foot flat on the ground, and the clinician dorsiflexes the hallux, monitoring the increased concavity of the arches of the foot. A positive result (arch formation) results from the flatfoot being flexible. A negative result (lack of arch formation) results from the flatfoot being rigid.

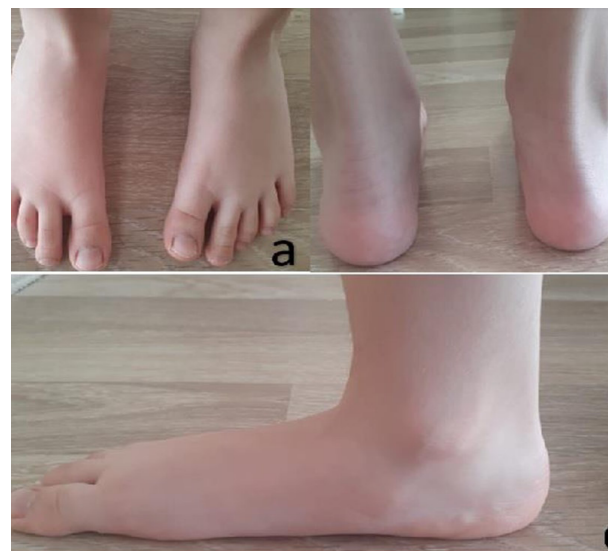

Figure 1: Anterior (a), posterior (b) and medial (c) images of a flat-foot.

Pain is a very common symptom in patients with pes planus and usually in the medial midfoot because of the pressure on the collapsed talar head where callus formation may be evident. Pain also can be located in the lateral foot at the sinus tarsi due to impingement from excessive subtalar joint eversion. Improvement in pain associated with flat feet may be seen with the use of foot orthoses. Balance has also been shown to improve with the use of foot orthoses [11-14].

Although radiological confirmation is rarely required in uncomplicated cases, it may be necessary in some cases to rule out the pathological conditions such as vertical talus, tarsal coalition etc.

In order to define the medial arch, many techniques such as a) radiological imaging methods, b) evaluation with photographs, c) height of the medial arch from the ground, d) footprint and e) sole pressure analysis can be used. Although studies on this subject have examined the shape and Radiology of the foot in detail, they do not contain sufficient information about the long-term course of the shape of the foot and its clinical importance.

- Assessment of the height of the medial arch from the ground; the distance of the navicular tubercle from the ground plane when standing.

- Assessment of the footprints; the ratio of the footprint's

size of the midfoot to the size of the footprint at the heel (medial arch index) is calculated [15].

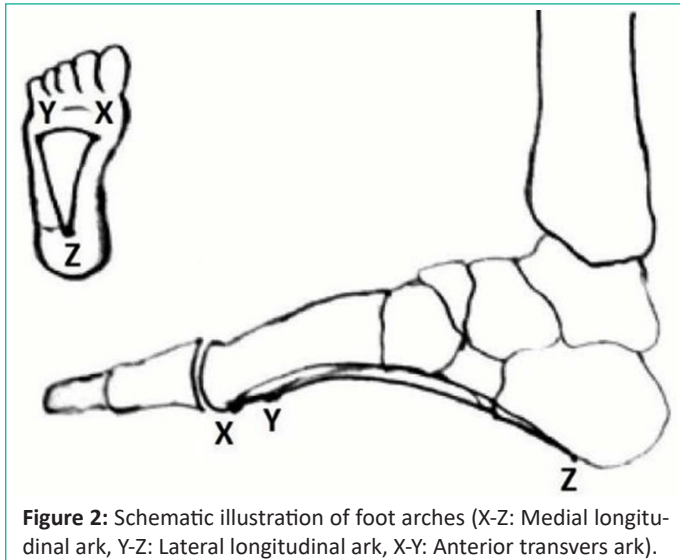


Figure 2: Schematic illustration of foot arches (X-Z: Medial longitudinal arch, Y-Z: Lateral longitudinal arch, X-Y: Anterior transverse arch).

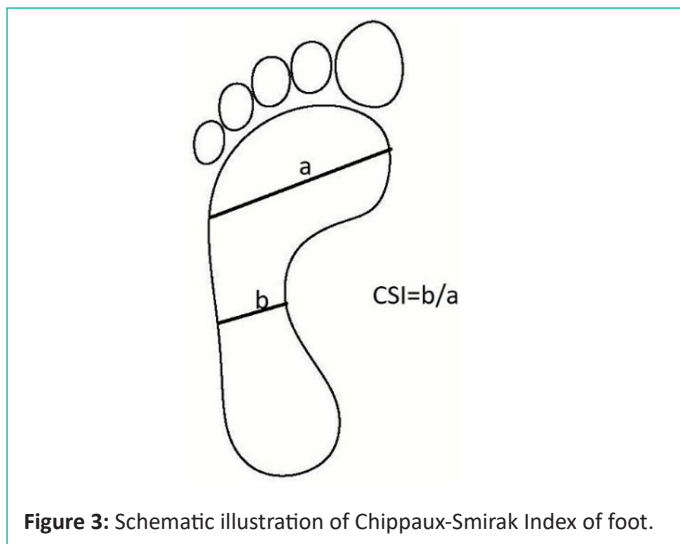


Figure 3: Schematic illustration of Chippaux-Smirak Index of foot.

Chippaux-Smirak Index (CSI): CSI is the ratio between the widest (segment a) and the narrowest (segment b) areas with borders passing through metatarsal heads as estimated from podographic measurements of footprints [13].

CSI=

- 0, Cavus foot
- 0.01 – 0.29, Normal foot
- 0.30 – 0.39, Intermediate foot
- 0.40 – 0.44, Collapsed foot
- ≥ 0.45 , Flatfoot

The medial longitudinal arch consists of the calcaneus, navicular, talus, first three cuneiform and first three metatarsals. This arch is supported by posterior tibial tendon, plantar calcaneonavicular ligament, deltoid ligament, plantar aponeurosis, and flexor hallucis longus and brevis muscles. Dysfunction or injury of any of these structures can cause acquired pes planus.

Management

There is no clarity in the literature about which children need treatment or the efficacy of the intervention. For patients with

pain-free, flexible flat feet, there is no concrete evidence that any available intervention can alter the natural course of foot shape development and in the absence of pain, neither operative nor non-operative management is superior to observing the patient. Observation is the best course.

A major debate in the management of patients with asymptomatic flexible flatfoot has been the role of accessory shoe supports and orthotics. A prospective study performed by Wenger et al [16] studied the efficacy of shoe modifications in altering the development of the longitudinal arch of the foot in 129 patients aged 3 to 5 years and found no significant difference in foot development between patients with shoe wear modifications compared with healthy controls after at least 3 years of follow-up. Whitford and Esterman [17] compared generic orthoses, custom orthoses, and a control group in children aged 7 to 11 with flat feet. There were no significant differences between the groups in reported pain, gross motor proficiency, self-perception, or exercise efficiency. Some studies have reported that wearing shoes had harmful effects on the formation of longitudinal arch of the foot [18]. Also previous study that evaluated footprints of 2300 children aged between 4 and 13 years, indicated that in barefooted children normal MLA formed at a higher frequency, and stated that shoe-wearing habit might adversely affect the development of MLA [19]. Since modifications of shoe design, and sole insoles are ineffective in the treatment of flatfoot [16,20] the main objective in the treatment of flatfoot should be to convince the patient's relatives that this deformity will resolve with time, and use of orthosis is not necessary.

Physiotherapy is aimed to improve the strength of the extrinsic and intrinsic foot musculature. An exercise program to increase strength in the muscles that stabilize the arches may be advised to the patient. Specific exercises include walking up on the metatarsal heads ('tip-toes'), walking on the heels, walking barefoot on soft sand, flexing the toes, rolling a ball under the arch of the foot while sitting, great toe dorsiflexion, and encouraging climbing [5,6]. The initial treatment of painful flexible flatfoot is also nonoperative. Conservative treatment includes rest, massage, activity modification and nonsteroidal anti-inflammatory drugs for pain reduction. In patients with a tight heel cord, because the talus remains plantarflexed, orthosis may increase pain due to pressure against the talar head [8]. A home physical therapy program consisting of Achilles tendon stretching and calf muscle strengthening should be advised. A recent study by Blitz et al [21] showed that stretching of the Achilles tendon may help counteract an equinus deformity, but there is still no definitive evidence to prove that physical therapy alters the clinical symptoms or structure of flat feet. Nonetheless, it is a reasonable starting point for management.

Surgery is rarely indicated in idiopathic pes planovalgus especially in patients with persistent pain despite a period of observation and nonsurgical management. Main aim of the surgical intervention is not to correct the deformity but to resolve the foot pain. Achilles tendon lengthening, restoration of the hind foot and correction of the forefoot abduction are the main objectives of the surgery. Soft tissue procedures, bony procedures or combination of these procedures may be the options.

Soft Tissue Procedures:

- Lengthening of Achilles tendon
- Tibialis Posterior tendon plication

- Tibialis Posterior tendon transfer
- FDL transfer
- Peroneal tendons lengthening
- Talonavicular capsulorrhaphy

Isolated soft tissue surgical options usually have poor results with high failure rates because the underlying structural anatomy of the foot is not altered [22]. Therefore, these procedures are usually performed in conjunction with osteotomies, cutting bones and repositioning them in a more anatomic position to help restore normal foot anatomy.

Bony Procedures:

- Medial Cuneiform Flexion Osteotomy
- Lateral Column lengthening
- Posterior Calcaneal Sliding Osteotomy
- Transverse calcaneal osteotomy
- Arthrodesis (Subtalar, Naviculocuneiform, Triple)
- Arthroereisis

Osteotomies address the underlying deformities in flexible flatfoot. Postsurgical series have demonstrated significant improvement of foot shape along with improvements in fatigue symptoms in 90% of patients [23,24]. Overall, positive outcomes after surgical management are possible when performed on the appropriate patient. A recent study by Oh et al [25] demonstrated a significantly increased mean American Orthopedic Foot and Ankle Society clinical outcome score at mean 5.2 years after certain osteotomy procedure.

Conclusions

Based on current literature, prophylactic treatment of an asymptomatic, painless flatfoot with expensive orthotics or surgery is not justified. On the other hand treatment of flexible pes planus in children is indicated only for those who have painful symptoms. Both orthotic and surgical treatments can improve pain levels and function.

References

- Pfeiffer M, Kotz R, Ledl T, Hauser G, Sluga M. Prevalence of flat foot in preschool-aged children. *Pediatrics*. 2006; 118: 634-9.
- Huang CK, Kitaoka HB, An KN, Chao EY. Biomechanical evaluation of longitudinal arch stability. *Foot Ankle*. 1993; 14: 353-7.
- Staheli LT. Evaluation of planovalgus foot deformities with special reference to the natural history. *J Am Podiatr Med Assoc*. 1987; 77: 2-6.
- Staheli LT, Chew DE, Corbett M. The longitudinal arch. A survey of eight hundred and eighty-two feet in normal children and adults. *J Bone Joint Surg Am*. 1987; 69: 426-8.
- Dare D, Dodwell ER. Pediatric flatfoot: Cause and epidemiology, assessment and treatment. *Curr Opin Pediatr*. 2014; 26: 93-100.
- Carr JB, Yang S, Lather LA. Pediatric pes planus: A state-of-the-art review. *Pediatrics* 2016; 137: 2015-20.
- Galli M, Cimolin V, Pau M, Costici P, Albertini G. Relationship between flatfoot condition and gait pattern alterations in children with Down Syndrome. *J Intellect Disabil Res*. 2014; 58: 269-76.
- Mosca VS. Flexible flatfoot in children and adolescents. *J Child Orthop*. 2010; 4: 107-21.
- Banwell H, Paris M, Mackintosh S, Williams C. Paediatric flexible flat foot: How are we measuring it and are we getting it right? A systematic review. *J Foot Ankle Res*. 2018;11:21.
- Ford SE, Scannell BP. Pediatric flatfoot: Pearls and pitfalls. *Foot Ankle Clin*. 2017; 22: 643-56.
- Kane K. Foot orthoses for pediatric flexible flatfoot: Evidence and current practices among Canadian physical therapists. *Pediatr Phys Ther*. 2015; 27: 53-9.
- Dars S, Uden H, Banwell HA, Kumar S. The effectiveness of non-surgical intervention (foot orthoses) for paediatric flexible pes planus: A systematic review: Update. 2018; 13: 1-5.
- Hsieh R, Peng H, Lee W. Short-term effects of customised arch support insoles on symptomatic flexible flatfoot in children: A randomized controlled trial. *Medicine (Baltimore)*. 2018; 97: 106-9.
- MacKenzie AJ, Rome K, Evans A. The efficacy of non-surgical interventions for pediatric flexible flat foot: A Critical Review. *J Pediatr Orthop*. 2012; 32: 830-4.
- Forriol F, Pascual J. Footprint analysis between three and seventeen years of age. *Foot Ankle*. 1990; 11: 101-4.
- Wenger DR, Mauldin D, Speck G, Morgan D, Lieber RL. Corrective shoes and inserts as treatment for flexible flatfoot in infants and children. *J Bone Joint Surg Am*. 1989; 71: 800-10.
- Whitford D, Esterman A. A randomized controlled trial of two types of in-shoe orthoses in children with flexible excess pronation of the feet. *Foot Ankle Int*. 2007; 28: 715-23.
- Sachithanandam V, Joseph B. The influence of footwear on the prevalence of flat foot. A survey of 1846 skeletally mature persons. *J Bone Joint Surg Br*. 1995; 77: 254-7.
- Sim-Fook L, Hodgson AR. A comparison of foot forms among the non-shoe and shoe-wearing Chinese population. *J Bone Joint Surg Am*. 1958; 40: 1058-62.
- Gould N, Moreland M, Alvarez R, Trevino S, Fenwick J. Development of the child's arch. *Foot Ankle* 1989; 9: 241-5.
- Blitz NM, Stabile RJ, Giorgini RJ, DiDomenico LA. Flexible pediatric and adolescent pes planovalgus: conservative and surgical treatment options. *Clin Podiatr Med Surg*. 2010; 27: 59-77.
- Sullivan JA. Pediatric flatfoot: evaluation and management. *J Am Acad Orthop Surg*. 1999; 7: 44-53.
- Koutsogiannis E. Treatment of mobile flatfoot by displacement osteotomy of the calcaneus. *J Bone Joint Surg Br*. 1971; 53: 96-100.
- Mosca VS. Calcaneal lengthening for valgus deformity of the hindfoot. Results in children who had severe, symptomatic flatfoot and skewfoot. *J Bone Joint Surg Am*. 1995; 77: 500-12.
- Oh I, Williams BR, Ellis SJ, Kwon DJ, Deland JT. Reconstruction of the symptomatic idiopathic flatfoot in adolescents and young adults. *Foot Ankle Int*. 2011; 32: 225-32.