

Case Report

A Different Kind of Parkinson: Case Report

Chu E, Deschamps J, Safaeipour M, Bhat P, and Jaqua EE*

Department of Family Medicine, Loma Linda University Health, USA

*Corresponding author: Ecler Ercole Jaqua, Department of Family Medicine, Loma Linda University Health, USA

Received: August 04, 2022; Accepted: August 20, 2022; Published: August 27, 2022

Case Presentation

A 16-year-old female presented to the primary care physician to establish care for a well-child visit. She did not have any significant past medical history or take any medications. However, the patient reported intermittent lightheadedness and dizziness occurring about four times a month for the past six months. These episodes occur while sitting or even when she stands up. In addition, she reported palpitations, room spinning sensation, and feeling “hot and shaking” during these events. She denied strenuous exercise and had no particular triggers before her episodes. There is no significant family history of cardiac diseases or personal history of heart murmurs. The patient has had two to three episodes of passing out in her lifetime—no episodes associated with her menstrual periods or bowel movements.

Physical Exam/EKG

Physical exam and vitals were unremarkable. However, an Electrocardiogram (EKG) showed delta waves on multiple contiguous leads (Figure 1). Therefore, the patient was diagnosed with Wolf-Parkinson-White Syndrome (WPWS). Urgent pediatric cardiology referral was requested, and the patient was recommended to abstain from strenuous exercise. No cardiac medications were started.

Specialty Clinic

While in the pediatric cardiology clinic, EKG findings were likely secondary to the right septal pathway. Suspected vasovagal, but unable to differentiate from tachyarrhythmia associated with syncope. Orthostatic vitals were performed during the clinic, supporting postural tachycardia syndrome for increased heart rate from 68 bpm lying down to 89 bpm standing. The specialist ordered a transthoracic echocardiogram, Holter monitor 8–14-day patch, and exercise stress test for further risk stratification. In addition, the patient was instructed to increase fluid intake to at least 80oz of water daily and increase sodium intake. No cardiac medications were prescribed at the visit.

Follow up

A transthoracic echocardiogram showed no left or right ventricular outflow tract obstruction. The right coronary artery arises from the aortic root in a clockwise orientation but cannot rule out if it comes from the left aortic cusp. Normal biventricular systolic function with no evidence of elevated pulmonary artery pressure. Cardiac Computed Tomography (CT) was ordered for further evaluation. However, the pediatric cardiologist suspected that her symptoms

Abstract

Lightheadedness and dizziness are common chief complaints in a primary care clinic. These symptoms affect a person's life in multiple ways and have a wide range of differential. We present a case of a teen female with these symptoms whom we diagnosed with having Wolff-Parkinson-White Syndrome, but we could not pinpoint whether this entirely caused her symptoms. Wolff-Parkinson-White Syndrome-associated dysrhythmias remain a significant differential amongst people presenting with lightheadedness.

were secondary mainly to vasovagal syncope. Unfortunately, the patient didn't show up for her following appointment.

Discussion

Supraventricular Tachycardias (SVTs) are a subset of tachyarrhythmias resulting from irregular pacemaker activity or abnormal conduction of the myocytes of the atria or the Atrioventricular (AV) node [1]. Wolff-Parkinson-White syndrome results from the most common congenital accessory pathway, the bundle Kent [1,2]. This pathway anomaly allows supraventricular impulses to bypass the AV node, which causes abnormal conduction and ventricular preexcitation, ultimately leading to distinctive preexcitation patterns and tachyarrhythmias seen on EKG [1,2]. On EKG, characteristic signs are delta waves and ST segment changes. Therefore, if WPWS manifests without symptoms, but its pattern is picked up on EKG, it is known as the WPWS pattern [2].

Classic symptoms of WPWS are similar to symptoms of SVTs, such as episodes of tachycardia with dizziness, dyspnea, chest pain, and syncope, which may be self-limiting, though in some cases may progress to hemodynamic instability and Sudden Cardiac Death (SCD) [3]. Furthermore, WPWS syndrome is associated with other arrhythmias, most commonly atrioventricular reentrant tachycardia, which occurs in 80% of cases, followed by atrial fibrillation (15–35% of cases), a trial flutter (5%), and even more rarely, ventricular fibrillation or multifocal atrial tachycardia [3].

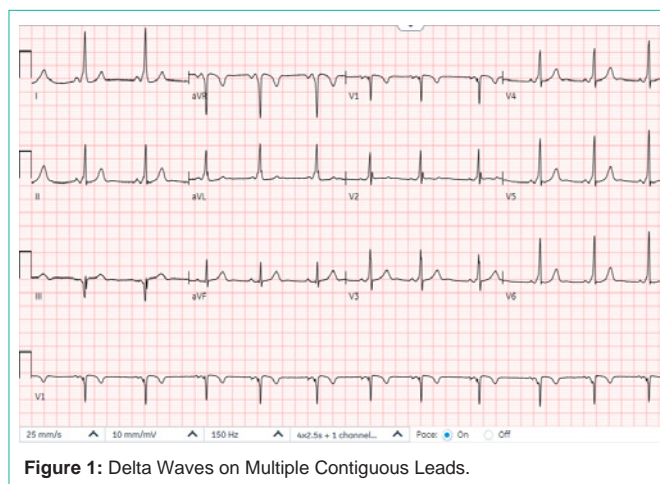


Figure 1: Delta Waves on Multiple Contiguous Leads.

The prevalence of WPWS varies between 0.1-0.2% in the general population and approximately 0.55% in first-degree relatives [4]. WPWS is more prevalent in males, and symptom onset generally begins between 20-40 years of age [3,5].

WPWS may be associated with structural abnormalities of the heart, in particular the Ebstein anomaly [3]. Also, 10% of patients with WPWS have multiple accessory pathways, particularly in patients with coexisting structural heart disease [2,6]. WPWS can also be inherited in an autosomal-dominant genetic disorder that causes conduction abnormalities and may cause hypertrophic cardiomyopathy [7]. Furthermore, the PRKAG2 gene was identified as a possible inherited gene mutation associated with WPWS [8].

The standard diagnostic workup includes a comprehensive history, physical exam, and a 12-lead EKG to identify the type of SVT [1]. Due to the paroxysmal nature of WPWS, continuous recording with a Holter monitor is often needed for diagnosis, and in some cases, invasive electrophysiological studies may be necessary [1,9].

In sinus rhythm on an EKG, a WPWS pattern is typically recognized by a short PR interval (<0.12 seconds), a widened QRS complex (>0.12 seconds), and a delta wave with a slurred upstroke at the start of the QRS indicative of preexcitation [9]. WPWS may also be seen with a trial fibrillation or flutter, with a heart rate reaching over 200 beats per minute as the accessory pathway bypasses the AV node [10]. The differential diagnosis for WPWS includes atrial fibrillation, atrial flutter, atrial tachycardia, Atrioventricular Nodal Reentry Tachycardia (AVNRT), disease, and polymorphic ventricular tachycardia [11].

Acute episodes of WPWS in cases of hemodynamic instability require emergent cardio conversion [5]. In contrast, acute episodes in hemodynamically stable patients may benefit from vagal maneuvers and intravenous antiarrhythmic medication, depending on the underlying rhythm. Long-term management includes curative catheter ablation or antiarrhythmic medications [5].

Risk stratification is necessary for proper treatment based on clinical findings, electrophysiological parameters, Holter monitor or exercise stress test results, and EKG patterns [12,13]. Concerning clinical features include syncope, atrial fibrillation, atrial tachycardia, or atrial flutter [12,13]. Accordingly, high-risk patients may benefit from catheter ablation of the accessory pathway, while asymptomatic low-risk patients may require no treatment [14]. The overall risk of SCD in WPWS syndrome is low, estimated at 0.1% in asymptomatic patients and 0.3% in symptomatic patients per year [15].

Conclusion

In summary, Wolff-Parkinson-White Syndrome remains a critical differential to consider in people presenting with light headedness.

Early detection and treatment may improve the quality of life of the patient. A thorough history, review of systems, and examination assist the clinician in determining the cause of patient symptoms. The pathology discovered allows the clinician to plan further assessment and management options and provide reassurance. Unfortunately, our patient was at a loss to follow up despite our systemic measures in place to enhance patient retention.

References

- Chhabra L, Goyal A, Benham MD. Wolff Parkinson White Syndrome. In: Stat Pearls. Stat Pearls Publishing; 2022.
- Chrispin J, Calkins H. Accessory pathways-related tachycardias: Wolff-Parkinson-White syndrome and atrioventricular reentrant tachycardias. Published online. July 1, 2018.
- Essence of Anesthesia Practice - 4th Edition. Accessed July 26, 2022.
- Crawford MH, Di Marco JP, Paulus WJ. Cardiology E-Book. Elsevier Health Sciences; 2009.
- Braunwald's Heart Disease: A Textbook of Cardiovascular Medicine, 2-Volume Set - 11th Edition. 2022.
- Chou's Electrocardiography in Clinical Practice - 6th Edition. 2022.
- Sidhu J, Roberts R. Genetic basis and pathogenesis of Familial WPW Syndrome. Indian Pacing and Electrophysiology Journal. 2003; 3: 197-201.
- Zhang L, Hui B, Gao B. High risk of sudden death associated with a PRKAG2-related familial Wolff-Parkinson-White syndrome. Journal of electrocardiology. 2011; 44: 483-486.
- Silva G, Morais GPD, Primo J, Sousa O, Pereira E, Ponte M, et al. Aborted sudden cardiac death as first presentation of Wolff-Parkinson-White syndrome. Revista portuguesa de cardiologia: orgao oficial da Sociedade Portuguesa de Cardiologia = Portuguese journal of cardiology: an official journal of the Portuguese Society of Cardiology. 2013; 32: 325-329.
- Hollenberg SM, Heitner S. Cardiology in Family Practice: A Practical Guide. Springer Science & Business Media; 2011.
- Sapra A, Albers J, Bhandari P, Davis D, Ranjit E. Wolff-Parkinson-White Syndrome: A Master of Disguise. Cureus. 2020; 12.
- Brugada J, Keegan R. Asymptomatic Ventricular Pre-excitation: Between Sudden Cardiac Death and Catheter Ablation. Arrhythmia & electrophysiology review. 2018; 7: 32.
- Electrophysiological Disorders of the Heart E-Bo - 9781437709711 | Elsevier Health. MEA Elsevier Health. 2022.
- ACC/AHA/HRS Guideline for the Management of Adult Patients With Supraventricular Tachycardia | Circulation. 2022.
- Laaouaj J, Jacques F, O'Hara G, Champagne J, Sarrazin J, Nault I, et al. Wolff-Parkinson-White as a bystander in a patient with aborted sudden cardiac death. HeartRhythm Case Reports. 2016; 2: 399-403.