

## Case Report

# Herpes Zoster Reactivation in Patients on Methotrexate: An Important Consideration

Garg N<sup>1\*</sup>; Jones R<sup>2</sup>; Cohen E<sup>3</sup>; Garg S<sup>4</sup><sup>1</sup>Boston University Chobanian & Avedisian School of Medicine, Boston, Massachusetts, USA<sup>2</sup>Wake Emergency Physicians, PA, Cary, North Carolina, USA<sup>3</sup>Department of Rheumatology, Boston Medical Center, Boston, Massachusetts, USA<sup>4</sup>Carolina Rheumatology & Internal Medicine, Fayetteville, North Carolina, USA**\*Corresponding author: Garg N**Boston University Chobanian & Avedisian School of Medicine, 72 East Concord St, Boston, MA 02118, USA  
Tel: 910-920-8293

Email: ngarg720@bu.edu

**Received:** December 26, 2023**Accepted:** January 20, 2024**Published:** January 27, 2024**Abstract**

Rheumatoid arthritis frequently necessitates treatment with Disease Modifying Anti-Rheumatic Drugs (DMARDs). Methotrexate (MTX), a commonly prescribed DMARD, has known immunosuppressive properties along with various side effects. We report a case of an adult with rheumatoid arthritis on MTX, who experienced herpes zoster reactivation due to MTX's immunosuppressive properties. Furthermore, we emphasize the importance of Shingles vaccination in patients on MTX and thorough examination to prevent delayed diagnosis. We describe the case of a 76-year-old male with a history of rheumatoid arthritis who presented to multiple healthcare settings with constant chest pain with radiation to the left shoulder and upper back. Laboratory results and imaging ruled out potential cardiac and pulmonary etiologies of pain. On presentation to his rheumatologist, examination revealed a truncal polyphasic rash, affecting multiple dermatomes. After complete examination, the chest pain was attributed to postherpetic neuralgia secondary to herpes zoster reactivation, and treatment consisted of Gabapentin. Postherpetic neuralgia improved within two weeks, however, the rash persisted. This report presents a rare case of herpes zoster reactivation secondary to MTX immunosuppression. This case report aims to emphasize the importance of increased monitoring and thorough examination in patients treated with immunosuppressive agents and administration of Shingrix vaccine prior to initiating immunosuppressive therapy.

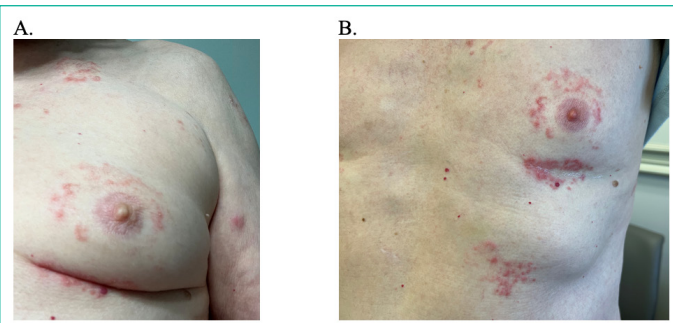
**Keywords:** Methotrexate; Herpes Zoster; Shingles; Immunosuppression**Introduction**

Rheumatoid arthritis is a common chronic inflammatory joint disease in today's society, often necessitating treatment with Disease-Modifying Anti-Rheumatic Drugs (DMARDs) [1]. The most frequently prescribed conventional synthetic DMARD is Methotrexate (MTX) whose mechanism involves inhibition of DNA synthesis via dihydrofolate reductase antagonism [2]. Notably, side effects of MTX include hepatotoxicity, pulmonary toxicity, and immunosuppression, which can place patients at a higher risk for opportunistic infections and reactivation of latent infections [3]. In this report, we describe a patient taking MTX who was misdiagnosed on multiple occasions before ultimately being diagnosed with herpes zoster reactivation due to MTX's immunosuppressive properties.

**Case Report**

Informed consent was obtained and signed from the following patient regarding the use of patient health information for the purposes of writing a case report publication.

The patient is a 76-year-old male with a history of rheumatoid arthritis who presented to a local Emergency Department (ED) with a 1-day history of constant chest pain with radiation to the left shoulder and upper back. Medical history includes coronary artery disease requiring percutaneous intervention, chronic kidney disease (stage 3), chronic obstructive pulmonary disease, hypertension, and rheumatoid arthritis on 20 mg of MTX weekly.



**Figure 1:** (A) Polyphasic rash at initial appointment with rheumatologist (B) Rash 2 weeks later (right).

In the ED, his musculoskeletal and cardiopulmonary physical exam were unremarkable. His cardiac workup including cardiac enzymes, stress testing, and imaging returned within normal limits. The patient was discharged home with recommendations to follow-up with cardiology. However, upon presentation to his cardiologist, no abnormalities were found. Nine days following the initial ED presentation, the patient presented to a tertiary care hospital due to persistent pain. There, the pain was attributed to musculoskeletal causes. Given his history of rheumatoid arthritis, the patient was recommended to follow up with outpatient rheumatology.

Upon presentation to his rheumatologist's clinic, he continued to report persistent, sharp chest pain. A thorough history and review of systems revealed that the patient had developed a new rash at approximately the same time of onset as his chest pain. A complete physical exam was performed, which was remarkable for a polyphasic rash in various stages of healing, affecting multiple dermatomes on the left side of the chest (Figure 1A). Given the patient's history of MTX use, a diagnosis of postherpetic neuralgia secondary to herpes zoster reactivation was made. The patient was treated with Gabapentin 100 mg daily with instruction to gradually increase to 300 mg daily. Upon follow-up, the patient noted significant improvement in chest pain caused by postherpetic neuralgia, however, endorsed a persistent rash (Figure 1B).

### Discussion

Although cases of reactivation tuberculosis and hepatitis B have been previously described in patients on MTX in the literature [4], here we describe a case of a patient who was diagnosed with herpes zoster reactivation due to MTX's immunosuppressive properties. Herpes zoster, also known as shingles, is caused by reactivation of a latent virus, Varicella Zoster Virus (VZV), which typically remains latent in the dorsal root ganglion after a primary infection [5]. We hypothesize that VZV reactivation in this patient was likely multifactorial, with MTX use being the largest contributing factor. In addition to its immunosuppressive properties, MTX can decrease cell-mediated immunity and slow the body's healing processes, leaving patients more vulnerable to reactivation of latent infection such as herpes zoster [6]. It is imperative that patients on a regimen of MTX are made aware of these risks and are appropriately vaccinated prior to MTX initiation. Since its Food and Drug Administration (FDA) approval in 2017 [7], the Shingrix vaccine has had a significant

impact on the landscape of herpes zoster prevention and management. The two-dose vaccine series has been approved for adults aged 50 years and older as well as immunocompromised individuals aged 18 years and older. It is known to have long lasting protection against shingles and significantly reduces the risk of postherpetic neuralgia [8,9], making it an important vaccine for both healthy individuals and specifically for patients taking immunosuppressive agents such as methotrexate. In this case report, our goal is to emphasize the importance of obtaining a thorough medical history and physical examination in patients with autoimmune diseases who are taking MTX. These patients must be carefully monitored for any signs of infection to minimize not only the burden of disease, but also to reduce the risk of secondary complications, such as postherpetic neuralgia in this case. Delayed diagnosis caused this patient undue and protracted pain from postherpetic neuralgia that could have been avoided if properly diagnosed and treated initially with antiviral medication. By maintaining a high index of suspicion and expediting proper management, healthcare providers can ultimately improve patient reported outcomes and reduce complications associated with opportunistic infections in this population. In effect, this may also lead to a reduction in unnecessary healthcare testing and overall healthcare costs. It is our hope that this case serves as a reminder to healthcare professionals to consider the possibility of alternative diagnoses during patient assessment to provide efficient and effective care to patients taking MTX and other immunosuppressive medications.

### References

1. Radu AF, Bungau SG. Management of rheumatoid arthritis: an overview. *Cells*. 2021; 10: 2857.
2. Zhao Z, Hua Z, Luo X, Li Y, Yu L, Li M, et al. Application and pharmacological mechanism of methotrexate in rheumatoid arthritis. *Biomed Pharmacother*. 2022; 150: 113074.
3. Wang W, Zhou H, Liu L. Side effects of methotrexate therapy for rheumatoid arthritis: A systematic review. *Eur J Med Chem*. 2018; 158: 502-16.
4. Lamb SR. Methotrexate and reactivation tuberculosis. *J Am Acad Dermatol*. 2004; 51: 481-2.
5. Saguil A, Kane S, Mercado M, Lauters R. Herpes zoster and postherpetic neuralgia: prevention and management. *Am Fam Phys*. 2017; 96: 656-63.
6. Pourcher V. Can patients on methotrexate receive live vaccines? *Joint Bone Spine*. 2019; 86: 415-7.
7. Harpaz R, Ortega-Sanchez IR, Seward JF, Advisory Committee on Immunization Practices (ACIP), Centers for Disease Control and Prevention (CDC). Prevention of herpes zoster: recommendations of the Advisory Committee on Immunization Practices (ACIP). *MMWR Recomm Rep*. 2008; 57: 1-30.
8. Singh G, Song S, Choi E, Lee PB, Nahm FS. Recombinant zoster vaccine (Shingrix®): a new option for the prevention of herpes zoster and postherpetic neuralgia. *Korean J Pain*. 2020; 33: 201-7.
9. Sly JR, Harris AL. Recombinant zoster vaccine (Shingrix) to prevent herpes zoster. *Nurs Womens Health*. 2018; 22: 417-22.