

Editorial

Industrial Fluoride Emissions are Dangerous to Animal Health, but Most Ranchers are Unaware of it

Choubisa SL*

Department of Advanced Science and Technology,
National Institute of Medical Science and Research, NIMS
University Rajasthan, Jaipur & Former Post Graduate
Department of Zoology, Government Meera Girls
College, India

***Corresponding author: Shanti Lal Choubisa**

Department of Advanced Science and Technology,
National Institute of Medical Science and Research, NIMS
University Rajasthan, Jaipur, Rajasthan 303121, & Former
Post Graduate Department of Zoology, Government
Meera Girls College, Udaipur, Rajasthan 313002, India

Received: December 13, 2022; **Accepted:** February 03,
2023; **Published:** February 10, 2023

Abstract

No doubt, industrialization is relatively more important and necessary for the sustainable development and economy for any country or geographical region. That is why many types of factories or industrial activities work day and night for different types of production. But there are many of these factories which continuously emit fluoride in the gaseous and particulate/dust forms into their surrounding environments and contaminate diverse natural resources such as soil, air, reservoirs, herbage, vegetation, ecosystem etc. In the world or in different countries, the major and most common sources of industrial fluoride emissions are coal-fired power plants and industrial activities, such as the production of steel, iron, aluminium, zinc, phosphorus, chemical fertilizers, oil refineries, bricks, glasses, plastic, cement, and hydrofluoric acid. When domestic animals viz. cattle (*Bos taurus*), water buffaloes (*Bubalus bubalis*), sheep (*Ovis aries*), goats (*Capra hircus*), horses (*Equus caballus*), donkeys (*Equus asinus*), and dromedary camels (*Camelus dromedarius*) exposed to industrial fluoride emissions or pollution over a long period of time, it becomes highly toxic and poses a threat to animal health. In the world, thousands of domestic animals have been found to be suffering from a dangerous disease called industrial fluorosis due to chronic exposure of industrial fluoride. In fact, this fluoride affects the teeth and bones and soft organs as well. Due to its chronic toxicosis, teeth become weak and mottled (dental fluorosis) and animals develop lameness (skeletal fluorosis) when fluoride toxicosis becomes more severe. However, immature and bovine animals are found to be more prone to fluorosis. Apart from the health of animals, industrial fluorosis in domestic animals also affects the economy of the livestock farmers. But most ranchers or livestock farmers are unaware of it. In present editorial, the most common sources of industrial fluoride emissions, chronic industrial fluoride toxicosis or industrial fluorosis in domestic animals, and the possible ways for how to prevent animals from this disease have been highlighted. Through this article, it is also to attract the attention of the responsible people so that this health problem caused by industrial fluoride pollution can be prevented in economically important animals.

Keywords: Dental Fluorosis; Domestic Animals; Fluoride; Food-Borne Fluorosis; Hydrofluorosis; Industrial Fluoride Emissions; Industrial Fluorosis; Non-Skeletal Fluorosis; Skeletal Fluorosis

Introduction

It is well known, an excessive ingestion and/or inhalation of fluoride through water, food, and air causes the dreaded fluorosis disease not only in human beings [1-9] but also in diverse species of domestic animals [10-18]. This slow progressing disease is more prevalent or common in those areas where fluoride is endemic. In more than 25 countries this disease is endemic with varying prevalence and severity [1]. When fluorosis develops after drinking water containing fluoride, it is called "hydrofluorosis" which is natural and more prevalent and wide spread in nature as well [19-22]. Generally, this form of fluorosis develops when the fluoride in drinking water exceeds the threshold level or maximum permissible level of 1.5 ppm [1]. In contrast, "industrial fluorosis" is anthropogenic, relatively less prevalent, restricted to a particular location or herd, and caused by the long-term exposure to fluoride being emitted from various industrial operations [23-26]. In the world or in diverse countries coal-burning power stations and the manufacture or production of steel, iron, aluminium, zinc, phosphorus, chemical fertilizers, bricks, glass, plastic, cement, oil refineries, and hydrofluoric acid are the most common and major sources for releasing of fluoride into their surrounding environments, in both gaseous and particulate/dust forms [1]. Ultimately, this emitted industrial fluoride contaminates diverse natural resources such as soil, air, reservoirs, agriculture crops, herbage/vegetation, food chains, and ecosystem. The inhalation of fluoride polluted air and ingestion of fluoride contaminated herbage, vegetation, and agriculture forage for a prolonged period develops fluorosis disease in all kind of domestic animals [1]. However, in these animals, fluorosis can develop through water, air, and food, as all three media are commonly contaminated with industrial fluoride.

Almost all kinds of fluoride emitting factories are usually located far away from the human populated area or cities, villages and towns, around which there are enough pastures for grazing animals. In these pastures, there are green or dry herbage, small and big shrubs and plants of many species, which are sources of food for domesticated animals. But all these contaminated by fluorinated gases released from different factories. Animals grazing in these pastures are exposed not only to fluoride-contaminated foods such as green and dry fodder, fodder crops, leaves, legumes, and fruits of trees and shrubs, etc. but also to fluoridated air and water. If fluorosis in animals develops due to consumption of food only then it is generally termed as "food-borne fluorosis". Fluorosis may be due to any reason, whether it is in humans or animals, but its symptoms are almost the same. Only its intensity and prevalence remain different.

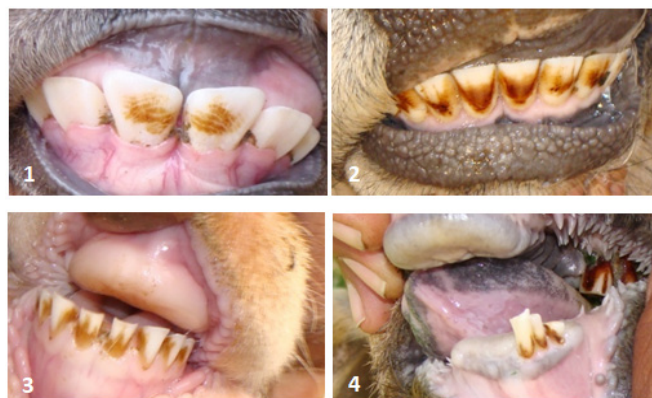Industrial fluorosis was recognized for the first time in 1932 by Møller and Gudjonsson in Danish cryolite workers [27]. Upon subsequent thorough investigation, several cases of fluorosis have been identified by Rohm as having been caused by inhalation of F dust [28]. Industrial fluorosis has been reported in both human beings [29-33] and diverse species of domestic animals [34-42] from several countries including Germany, USA, Great Britain, Soviet Union, Norway, France, Switzerland, China, and India. Despite having a number of different types of industrial activities in the world, only limited reports on industrial fluorosis in animals [34-42] are available, while it helps in making animal health related projects.

Industrial Fluoride and its Chronic Toxicosis in Animals

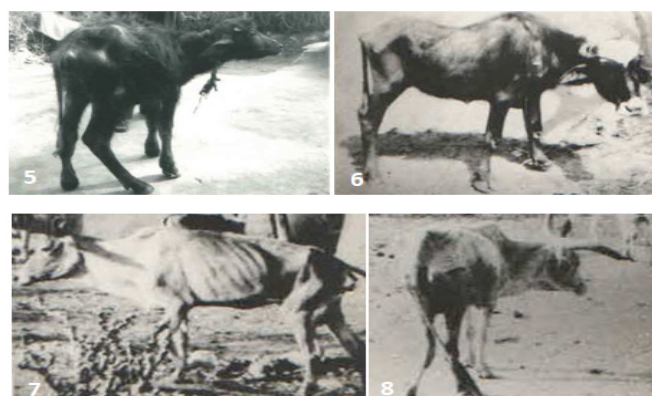
When domestic animals, viz. cattle (*Bos taurus*), water buffa-

loes (*Bubalus bubalis*), sheep (*Ovis aries*), goats (*Capra hircus*), horses (*Equus caballus*), donkeys (*Equus asinus*) and dromedary camels (*Camelus dromedarius*) are exposed to industrial fluoride over a long period of time, it becomes toxic to the health of the animals and causes a mild to severe industrial fluorosis. Due to chronic industrial fluoride toxicosis, teeth of animals become weak and mottled or discoloured characterised with light- to deep-brownish staining and excessive abrasion of teeth (as in Figures 1-4). This staining on the enamel of the teeth usually appears in bilateral, striated, and horizontal compact streaks and can be seen by necked eyes. These fluoride-induced toxic changes in teeth are, generally, collectively known as dental fluorosis. In its severe state, the teeth become weak and break or fall out sooner in early age of animals. Dental fluorosis is an early diagnostic or clinical sign for evidence of chronic fluoride toxicosis in both humans and animals [43,44]. Hence, dental fluorosis is also ideal biomarkers of chronic fluoride poisoning [45,46].

In fluorosed animals intermittent lameness, swollen joints, debility, morbidity, wasting of body muscles and bony lesions in the mandibles, ribs, metacarpus, and metatarsus regions are the resultant of severe form of chronic fluoride poisoning (as in Figures 5-8). Fluoride-induced these pathological bony changes are collective known as skeletal fluorosis, which is more dangerous and highly painful in early of age of animals. In this condition, the animal is neither able to walk properly nor can get up and sit. Such animals also cannot move their neck properly up-down and right-left. Generally, fluoride-induced deformities in the teeth and bones remain for the whole life of animals and they are not cured by any medicines. In fact, once these deformities develop, they never reverse [44].



Figures 1-4: Moderate and severe form of dental fluorosis in bovine calves (Figure 1) and adult (Figure 2) and adult sheep (Figure 3) and old goat (Figure 4) animals.



Figures 5-8: Skeletal fluorosis in bovines revealed lameness, enlarged joints, debility, invalidism, wasting of body muscles and bony lesions in ribs, metacarpus and metatarsus regions.

Due to chronic industrial fluoride toxicosis in domestic animals their soft organs are also affected (non-skeletal fluorosis) and cause many health problems. In animals, the most common fluoride-induced health problems are found to be intermittent diarrhoea or constipation, abdominal pain, flatulence, urticaria, anaemia, frequent tendency to urinate (polyuria), excessive thirst (polydipsia), lethargy, muscle weakness, irregular reproductive cycles, abortion, still birth, etc. [44]. These health effects are temporary and can be reverse in few days after the discontinuation fluoride exposure. This is not necessary that all these health consequences are found at the same time in the animal [44].

Among different species domestic animals, bovine animals are relatively more susceptible to fluoride toxicity [47-49]. However, immature animals have relatively less tolerance to fluoride exposure. Therefore, they are highly susceptible to fluoride toxicity and are also considered as endemic bio-indicators of fluoride and fluorosis [45]. Nevertheless, the prevalence and magnitude or severity of fluorosis in animals depends on several factors such as the concentration of fluoride and its duration or frequency of exposure, the density or rate of bio-accumulation of fluoride, food nutrients, species, age, environmental factors, individual fluoride susceptibility or tolerance, genetics, etc. [50-57].

Industrial fluoride pollution not only causes many types of physical deformities in animals, but also causes economic loss to ranchers or livestock owners [17,18,20]. Most villagers are unknown about the worst aspect of dental fluorosis is that it decreases the life span of animals. In its severe state, it causes a serious problem in grazing and mastication of food which may leads mortality in animals from starvation and frailness [1,47]. Death of animals before the age due to having of severe dental fluorosis causes much economic losses for animal keepers [17,18,20]. Apart from diverse fluoride-induced adverse health consequences, due to chronic fluoride toxicosis, milk production also decreases in animals, due to which livestock owners also suffer a lot of economic loss [17,18]. But most villagers or ranchers are unaware about the economic losses. In spite of huge economic losses, there are not many specialized research studies on industrial fluorosis in different species of domestic animals in the world, whereas these studies are very much needed in the formulation of animal health projects. Interestingly, the special thing is that most of the cattle herders do not even know why their animals are walking with a limp. They don't even know that the smoke coming out of factories is causing serious fluorosis disease in their animals. They are not even aware that they may also have fluorosis from industrial fluoride pollution. That's why it is necessary to create awareness among animal parents to avoid fluorosis in animals, which is definitely challenging but not difficult. It is almost impossible to displace factories from any area, but animals can be prevented from grazing in the pastures around these factories. This can eliminate the problem of industrial fluorosis in animals.

Acknowledgement

The author thanks to Dr. Pallavi Choubisa, Obstetrics and Gynaecology, Pannadhay Zanana Hospital, R.N.T. Medical College, Udaipur 313002, Rajasthan, India for cooperation.

References

- Adler P, Armstrong WD, Bell ME, Bhussry BR, Büttner W, Cremer H-D, et al. Fluorides and human health. World Health Organization Monograph Series No. 59. Geneva: World Health Organization; 1970.
- Choubisa SL, Sompura K. Dental fluorosis in tribal villages of Dungarpur district (Rajasthan). *Poll Res.* 1996; 15: 45-47.
- Choubisa SL. Fluorosis in some tribal villages of Udaipur district (Rajasthan). *J Environ Biol.* 1998; 19: 341-352.
- Choubisa SL, Choubisa DK, Joshi SC, Choubisa L. Fluorosis in some tribal villages of Dungarpur district of Rajasthan, India. *Fluoride.* 1997; 30: 223-228.
- Choubisa SL. Endemic fluorosis in southern Rajasthan (India). *Fluoride.* 2001; 34: 61-70.
- Choubisa SL, Choubisa L, Choubisa DK. Endemic fluorosis in Rajasthan. *Indian J Environ Health.* 2001; 43: 177-189.
- Choubisa SL. Fluoride in drinking water and its toxicosis in tribals, Rajasthan, India. *Proc Natl Acad Sci, India Sect B: Biol Sci.* 2012; 82: 325-330.
- Choubisa SL. Status of chronic fluoride exposure and its adverse health consequences in the tribal people of the scheduled area of Rajasthan, India. *Fluoride.* 2022; 55: 8-30.
- Choubisa SL. Chronic fluoride intoxication (fluorosis) in tribes and their domestic animals. *Intl J Environ Stud.* 1999; 56: 703-716.
- Choubisa SL, Pandya H, Choubisa DK, Sharma OP, Bhatt SK, et al. Osteo-dental fluorosis in bovines of tribal region in Dungarpur (Rajasthan). *Journal of Environmental Biology.* 1996; 17: 85-92.
- Choubisa SL. Some observations on endemic fluorosis in domestic animals of southern Rajasthan (India). *Vet Res Commun.* 1999; 23: 457-465.
- Swarup D, Dwivedi SK. Environmental pollution and effects of lead and fluoride and animals health. New Delhi: Indian Council of Agriculture Research; 2002.
- Choubisa SL. Fluoridated ground water and its toxic effects on domesticated animals residing in rural tribal areas of Rajasthan (India). *Intl J Environ Stud.* 2007; 64: 151-159.
- Choubisa SL. Osteo-dental fluorosis in horses and donkeys of Rajasthan, India. *Fluoride.* 2010; 43: 5-10.
- Choubisa SL. Fluorosis in dromedary camels of Rajasthan, India. *Fluoride.* 2010; 43: 194-199.
- Choubisa SL. Fluorotoxicosis in diverse species of domestic animals inhabiting areas with high fluoride in drinking waters of Rajasthan, India. *Proc Natl Acad Sci, India Sect B: Biol Sci.* 2013; 83: 317-321.
- Choubisa SL. Chronic fluoride exposure and its diverse adverse health effects in bovine calves in India: an epitomised review. *Glob J Biol Agric Health Sci.* 2021; 10: 1-6. Or 10:107.
- Choubisa SL. A brief and critical review of chronic fluoride poisoning (fluorosis) in domesticated water buffaloes (*Bubalus bubalis*) in India: focus on its impact on rural economy. *J Biomed Res Environ Sci.* 2022; 3: 96-104.
- Choubisa SL. A brief and critical review on hydrofluorosis in diverse species of domestic animals in India. *Environ Geochem Health.* 2018; 40: 99-114.
- Choubisa SL. A brief and critical review of hydrofluorosis in Rajasthan, India. *Fluoride.* 2018; 51(1): 13-33.
- Choubisa SL. Endemic hydrofluorosis in cattle (*Bos taurus*) in India: an epitomised review. *Int J Vet Sci Technol.* 2023; 8(1): 001-007.

22. Choubisa SL. A brief review of fluorosis in dromedary camels (*Camelus dromedarius*) and focus on their fluoride susceptibility. *Austin J Vet Sci & Anim Husb.* 2023; 10(1): id1117.
23. Choubisa SL, Choubisa D, Choubisa A. Fluoride contamination of groundwater and its threat to health of villagers and their domestic animals and agriculture crops in rural Rajasthan, India. *Environ Geochem Health.* 2022. doi.org/10.1007/s10653-022-01267-z.
24. Choubisa SL, Choubisa D. Neighbourhood fluorosis in people residing in the vicinity of superphosphate fertilizer plants near Udaipur city of Rajasthan (India). *Environ Monit Assess.* 2015;187(8):497. doi: 10.1007/s10661-015-4723-z.
25. Choubisa SL, Choubisa D. Status of industrial fluoride pollution and its diverse adverse health effects in man and domestic animals in India. *Environ Sci Pollut Res.* 2016; 23(8): 7244-7254. doi: 10.1007/s11356-016-6319-8.
26. Choubisa SL. A brief review of industrial fluorosis in domesticated bovines in India: focus on its socio-economic impacts on livestock farmers. *J Biomed Res.* 2023; 4(1): 8-15.
27. Møller PF, Gudjonsson SV. Massive fluorosis of bones and ligaments. *Acta Radiol (Stockholm).* 1932; 13: 269-294.
28. Roholm K. Fluorine intoxication: a clinical-hygienic study with a review of the literature and some experimental investigations. London: HK Lewis and Co; 1937.
29. Carnow BW, Conibear SA. Industrial fluorosis. *Fluoride.* 1981; 14: 172-181.
30. Zhang Y, Cao SR. Coal burning induced endemic fluorosis in China. *Fluoride.* 1996; 29: 207- 211.
31. Desai VK, Saxena DK, Bhavsar BS, Kantharia SL. Epidemiological study of dental fluorosis in tribal residing in fluorspar mines. *Fluoride.* 1988; 21: 137-141.
32. Samal UN, Naik BN. Dental fluorosis in school children in the vicinity of an aluminum factory in India. *Fluoride.* 1988; 21: 142-148.
33. Sharma R, Pervez S. Study of dental fluorosis in subjects related to phosphatic fertilizer plant environment in Chhattisgarh state. *J Scient Indust Res.* 2004; 63: 985-988.
34. Murray MM. Industrial fluorosis. *British Med Bull.* 1950; 7: 87-89.
35. Burns KN, Allcroft R. Fluorosis in cattle. I. Occurrence and effects in industrial areas of England and Wales 1954-57, Ministry of Agriculture, Fisheries and Food, Animal Disease Surveys Report, no. 2, Part I, London: Her Majesty's Stationary Office; 1964. pp.1-51.
36. Rosenberger G, Grunder HD. The effect of fluoride emission near HF factory. *Fluoride.* 1968; 1: 41-49.
37. Shupe JL. Fluorine toxicosis and industry. *American Ind Hyg Assoc J.* 1970; 3: 240-247.
38. Riet-Correa F, Carmen MM, Schild AL, Oliviera JA, Zenebon O. Dental lesions in cattle and sheep due to industrial pollution caused by coal combustion. *Vet Bull.* 1987; 57: 600.
39. Findaci UR, Sel T. The industrial fluorosis caused by a coal-burning power station and its effects on sheep. *Turkey J Vet Anim Sci.* 2001; 25: 735-741.
40. Ray SK, Behra SK, Sahoo N, Dash PK. Studies on fluorosis in cattle of Orissa due to industrial pollution. *Indian J Anim Sci.* 1993; 67: 943-945.
41. Patra RC, Dwivedi SK. Bhardwaj D, Swarup D. Industrial fluorosis in cattle and buffalo around Udaipur, India. *Sci Total Environ.* 2000; 253: 145-150.
42. Choubisa SL. Industrial fluorosis in domestic goats (*Capra hircus*), Rajasthan, India. *Fluoride.* 2015; 48: 105-115.
43. Choubisa SL. The diagnosis and prevention of fluorosis in humans. (Editorial). *J Biomed Res Environ Sci.* 2022; 3: 264-267.
44. Choubisa SL. How can fluorosis in animals be diagnosed and prevented? (Editorial). *Austin J Vet Sci & Anim Husb.* 2022; 9: 1-5, id1096.
45. Choubisa SL. Bovine calves as ideal bio-indicators for fluoridated drinking water and endemic osteo-dental fluorosis. *Environ Monit Assess.* 2014; 186: 4493-4498.
46. Choubisa SL, Choubisa A. A brief review of ideal bio-indicators, bio-markers and determinants of endemic of fluoride and fluorosis. *J Biomed Res Environ Sci.* 2021; 2: 920-925.
47. Wang JD, Zhan CW, Chen YF, et al. A study of damage to hard tissue of goats due to industrial fluoride pollution. *Fluoride.* 1992; 25: 123-128.
48. Choubisa SL. Fluoride toxicosis in immature herbivorous domestic animals living in low fluoride water endemic areas of Rajasthan, India: an observational survey. *Fluoride.* 2013; 46: 19-24.
49. Choubisa SL, Mishra GV. Fluoride toxicosis in bovines and flocks of desert environment. *Intl J Pharmacol Biol Sci.* 2013; 7: 35-40.
50. Choubisa SL, Choubisa L, Choubisa D. Osteo-dental fluorosis in relation to nutritional status, living habits and occupation in rural areas of Rajasthan, India. *Fluoride.* 2009; 42: 210-215.
51. Choubisa SL, Choubisa L, Choubisa D. Osteo-dental fluorosis in relation to age and sex in tribal districts of Rajasthan, India. *J Environ Sci Engg.* 2010; 52: 199-204.
52. Choubisa SL. Natural amelioration of fluoride toxicity (fluorosis) in goats and sheep. *Curr Sci.* 2010; 99: 1331-1332.
53. Choubisa SL, Choubisa L, Choubisa D. Reversibility of natural dental fluorosis. *Intl J Pharmacol Biol Sci.* 2011; 5: 89-93.
54. Choubisa SL, Mishra GV, Sheikh Z, Bhardwaj B, Mali P, Jaroli VJ. Food, fluoride, and fluorosis in domestic ruminants in the Durgapur district of Rajasthan, India. *Fluoride.* 2011; 44: 70-76.
55. Choubisa SL. Osteo-dental fluorosis in relation to chemical constituents of drinking waters. *J Environ Sci Engg.* 2012; 54: 153-158.
56. Choubisa SL, Modasiya V, Bahura CK, Sheikh Z. Toxicity of fluoride in cattle of the Indian Thar Desert, Rajasthan, India. *Fluoride.* 2012; 45: 371-376.
57. Choubisa SL. Why desert camels are least afflicted with osteo-dental fluorosis? *Curr Sci.* 2013; 105: 1671-1672.