

## Case Report

# Ovarian Thecoma: A Very Unusual Cause of Postmenopausal Metrorrhagia

Arteaga E<sup>1\*</sup>, Valenzuela F<sup>1</sup>, Martinez A<sup>1</sup>, Huete A<sup>2</sup> and Aspee M<sup>3</sup>

<sup>1</sup>Department of Endocrinology and Centro Traslacional de Endocrinología (CETREN-UC), Pontificia Universidad Católica de Chile, Chile

<sup>2</sup>Department of Radiology, Pontificia Universidad Católica de Chile, Chile

<sup>3</sup>Pathology Service, Hospital Dr. Luis Tisne, Chile

\*Corresponding author: Arteaga E, Department of Endocrinology and Centro Traslacional de Endocrinología (CETREN-UC), Pontificia Universidad Católica de Chile, Chile

Received: July 13, 2020; Accepted: August 11, 2020; Published: August 18, 2020

## Abstract

**Purpose:** The aim of this report is to present a woman with an ovarian thecoma as an unusual cause of postmenopausal metrorrhagia.

**Methods:** We describe a 67 years old woman who was referred to our unit because of postmenopausal metrorrhagia having ceased estrogen plus progestogen therapy 9 months before.

**Results:** Transvaginal ultrasonography showed adenomyosis and a 13 mm endometrial thickening with normal ovarian appearance. Hormone studies revealed high estradiol and inhibin B levels while androgens and adrenal hormones were within the normal postmenopausal range. Endometrial biopsy confirmed hyperplasia. A pelvic magnetic resonance was done demonstrating a 13 mm left ovarian tumor. Hysterectomy and bilateral salpingo-oophorectomy were performed, and the pathological study revealed an 8 mm ovarian thecoma.

**Conclusions:** This case illustrates a very unusual cause of postmenopausal metrorrhagia. We suggest a study protocol and discuss the differential diagnosis of this case.

**Keywords:** Thecoma; Metrorrhagia and menopause

## Abbreviations

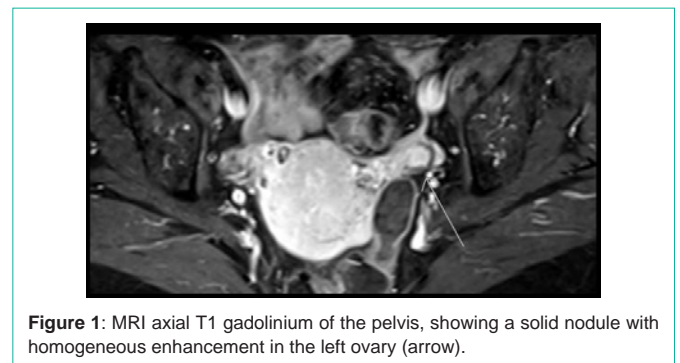
Granulosa cell tumors (GCTs); Estrogen plus progestogen therapy (EPT); magnetic resonance image (MRI); Steroid cell tumors (SCTs)

## Introduction

Ovarian neoplasms are classified into surface epithelial stromal, sex cord-stromal, germ cell and miscellaneous tumors [1]. Among them, sex cord-stromal tumors may be hormone-producing tumors. Thecomas and Granulosa Cell Tumors (GCTs) are considered primarily as estrogen-producing tumors [2], although occasionally they secrete androgens and cause virilization [3]. On the other hand, Sertoli stromal cell tumors and steroid cell tumors are characterized by testosterone production [4,5]. Furthermore, ovarian tumors other than sex cord-stromal tumors, even those metastatic, can have functioning stromata [6]. The management of thecoma tumors remains surgical and has a good prognosis as they usually present as stage 1 neoplasms [7]. We would like to share a case of a postmenopausal woman with metrorrhagia and high plasma levels of estradiol caused by a small ovarian thecoma. We discuss the differential diagnosis of this case and suggest a protocol to study the origin of the abnormal estrogen secretion.

## Case Report

A 67 years old female visited the endocrinology outpatient clinic with postmenopausal metrorrhagia. Her past medical history only revealed a compensated primary hypothyroidism treated with levothyroxine 50 µg daily. The previous gynecological record was unremarkable with menarche at 12 years of age, three normal pregnancies, followed by normal menstrual cycles, ending up with

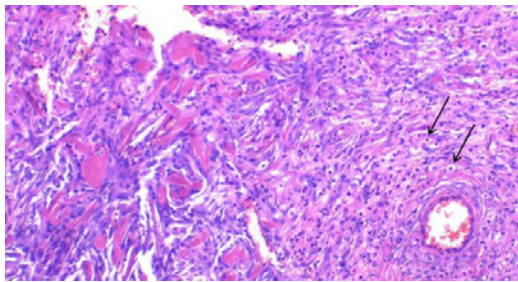


**Figure 1:** MRI axial T1 gadolinium of the pelvis, showing a solid nodule with homogeneous enhancement in the left ovary (arrow).

menopause at 52 years of age.

One year before our consultation she was seen in another medical center following an episode of moderate postmenopausal metrorrhagia while she was being treated with Estrogen Plus Progestogen Therapy (EPT) consisting of 1 mg of estradiol and 2 mg of drospirenone in a continuous combined regimen for the previous twelve years. Her vaginal ultrasonography revealed an irregular 13mm endometrial thickness and adenomyosis. Endometrial curettage was performed, and the biopsy revealed a proliferative endometrium that was initially attributed to the prolonged EPT, therefore, hormone therapy was changed to dienogest 2 mg daily for three months, which resulted in amenorrhea and no further thickening of the endometrium.

Nine months later, she consulted us due to a second episode of metrorrhagia. The physical examination showed a patient in good clinical condition. She had neither hirsutism nor signs of virilization nor Cushing syndrome. The gynecologic examination revealed an enlarged uterus compatible with adenomyosis and bloody discharge.



**Figure 2:** Hematoxylin-Eosin staining, 10x magnification. Tumor consisting of dense sheets of round to oval cells, with inconspicuous edges, abundant pale cytoplasm with lipid droplets and central nuclei without atypia (arrows) and scarce stroma with focal hyaline plaques.

The general laboratory workup showed normal results including red blood cell count and the vaginal ultrasonography showed a 13 mm endometrial thickness and adenomyosis without any abnormality in the ovaries. An endometrial curettage was performed again demonstrating hyperplasia. The hormonal profile demonstrated an inappropriately high level of plasma estradiol (261 pmol/L) and inhibin B (7.9 ng/L), only mildly elevated FSH for a postmenopausal woman (16.2 IU/L) and normal androgens levels corresponding with being postmenopausal (total testosterone 0.76 nmol/L, free androgen index 1.16, DHEAS 0.90  $\mu$ mol/L and androstenedione 4.5 nmol/L). The lack of a Cushingoid appearance and normality of adrenal hormone levels allowed us to rule out an adrenal etiology [4]. She was treated with 2 mg dienogest daily for 15 days every month for two months that induced mild vaginal withdrawal bleeding. Considering the possibility of an ovarian source of estradiol and inhibin B, a pelvic magnetic resonance image (MRI) was performed revealing a 13 mm nodule in the left ovary with an intermediate signal in T2, moderate diffusion restriction and homogeneous enhancement after the use of intravenous paramagnetic contrast (Figure 1).

After the localization of the source of abnormal estrogen secretion, she underwent a total hysterectomy and bilateral salpingo-oophorectomy. The pathology report described an 8 mm thecoma in the left ovary (Figure 2) in addition to adenomyosis and a normal right ovary.

Following surgery, the estradiol levels returned to postmenopausal levels and the patient complained of mild climacteric symptoms that did not require any treatment.

## Discussion and Conclusion

We present a very unusual case of a healthy postmenopausal woman with metrorrhagia and high plasma estrogen levels due to an ovarian thecoma which was treated by hysterectomy and bilateral salpingo-oophorectomy. This unusual ovarian tumor represented a real diagnostic challenge.

In patients with postmenopausal metrorrhagia, the first diagnosis to be excluded is endometrial pathology, with special emphasis on ruling out endometrial carcinoma. In our case, this diagnosis was ruled out with an endometrial biopsy in two occasions. While the patient was on EPT, metrorrhagia can be associated with prolonged hormonal therapy, and accordingly the biopsy demonstrated endometrial hyperplasia. However, the persistence of metrorrhagia

and endometrial hyperplasia after having ceased EPT for 9 months, led us to look for another explanation.

The most important element that allowed us to direct the differential diagnosis was the abnormally high level of estradiol. In the absence of exogenous hormone therapy in a postmenopausal woman, estradiol must originate directly from ovarian or adrenal secretion, in addition to peripheral conversion of androgens produced by the same sources. Normal plasma levels of DHEAS, androstenedione, ACTH and cortisol and the lack of Cushingoid stigmata, made the adrenals highly unlikely as the origin of the hormonal disorder [4]. Nonetheless, there are sparse reports of estrogen secreting adrenal carcinomas, although they characteristically co-secrete DHEAS and cortisol [8-10]. On the other hand, the high level of Inhibin B pointed out to an ovarian origin of the estradiol excess [11], although we were aware of a very unusual case report of an adrenal carcinoma secreting inhibin B and estradiol [12]. Considering that androstenedione, testosterone and the free testosterone index were in the postmenopausal range, it could be ruled out that they were the source of the excess production of estrogen. Therefore, we could infer that the origin of the high estrogen level would be direct ovarian secretion. The appropriate action then was to obtain images of the ovaries. It has been demonstrated that MRI is the best option when images of the ovaries are required, better than computed tomography or transvaginal sonography [13]. Consistent with this, several transvaginal sonograms had not shown any ovarian abnormality in this patient, but MRI was successful in doing so.

Once established that our patient had an estradiol-secreting ovarian tumor, there were two possible etiologies: a thecoma or a granulosa cell tumor both belonging to the Steroid Cell Tumors (SCTs). They occur mainly in postmenopausal women, although there is a juvenile variant of GCT that typically develops before puberty. Another entity, a sclerosing stromal tumor, can also produce estrogens but it was not considered in our case as it exclusively affects women younger than 30 years of age [14]. It is interesting to note that thecomas have shown immune-staining positive for inhibin B [15] and there is a case report of a fibrothecoma secreting Inhibin A and B [16]. Total hysterectomy with bilateral salpingo-oophorectomy was performed. Pathology examination revealed a normal right ovary and a left ovary with an 8 mm diameter yellowish nodule compatible with an ovarian thecoma. In order to classify this unusual tumor, it is important to highlight that there are three main types of ovarian neoplasms: epithelial tumors (65%), germ cell tumors (20-25%) and sex-cord stromal tumors (6%) [17]. Among the ovarian sex cord-stromal tumors, thecoma belongs to the subgroup of pure stromal tumors and its frequency does not exceed 1% of all ovarian neoplasms. In the largest series of thecomas to date, the patients ranged from 16 to 81 years of age (average 49.6 years), with the sixth decade containing the greatest number. All the tumors were unilateral with a diameter ranging from 0.5 to 22.5cm (average 4.9 cm), although two third were less than 5 cm and all the tumors secreted estrogens [18].

In conclusion, we present a very unusual case of a healthy woman with postmenopausal metrorrhagia induced by abnormal ovarian secretion of estradiol due to a small ovarian thecoma and we recommend a simple laboratory work-up in order to establish the abnormal source of estrogen secretion, discussing the differential

diagnosis. We also suggest that MRI is the best imaging approach to study the ovarian morphology. Considering the low malignant potential of this type of tumor, it is anticipated that the patient will have been cured by the surgery.

## References

1. Lee KR, Tavassoli FA, Prat J, et al. Surface epithelial-stromal tumors. In: Pathology and genetics, tumors of the breast and female genital organs. IARC Press. 2003; 117-45.
2. Scully RE, Young RH, Clement PB. Sex cord-stromal tumors, granulosa cell tumors. In: Tumors of the ovary, maldeveloped gonads, fallopian tube and broad ligament, Third Edition. Armed Forces Institute of Pathology. 1998; 169-88.
3. Siekierska-Hellmann M, Sworczak K, Babińska A, Wojtylak S. Ovarian thecoma with androgenic manifestations in a postmenopausal woman. *Gynecol Endocrinol.* 2006; 22: 405-8.
4. Arteaga E, Martinez A, Jaramillo J, Villaseca P, Cuello M, Valenzuela P, et al. Postmenopausal androgen-secreting ovarian tumors: challenging differential diagnosis in two cases. *Climacteric.* 2019; 22: 324-8.
5. Young RH, Scully RE. Sex cord-stromal, steroid cell, and other ovarian tumors with endocrine, paraendocrine and paraneoplastic manifestations. Kurman RJ, editor. In: Blaustein's pathology of the female genital tract, Fourth Edition. Springer-Verlag. 1993; 37: 783-847.
6. Scully RE, Young RH, Clement PB. Tumors with functioning stroma. In: Tumors of the ovary, maldeveloped gonads, fallopian tube, and broad ligament, Third Edition. Armed Forces Institute of Pathology. 1998; 373-8.
7. Scully RE, Young RH, Clement PB. Sertoli-stromal cell, mixed and unclassified sex-cord stromal tumors. In: Tumors of the ovary, maldeveloped gonads, fallopian tube and broad ligament. Armed Forces Institute of Pathology, 1998; 169-226.
8. Jeong Y, Cho SC, Cho HJ, Song JS, Kong J, Park JW, et al. Estrogen-secreting adrenocortical carcinoma. *Yeungnam Univ J Med.* 2019; 36: 54-8.
9. Chentli F, Chabour F, Bouchibane D, Nouar N. Feminizing adrenocortical carcinoma without gynecomastia. *Oman Med J.* 2017; 32: 349-51.
10. Advani A, Johnson SJ, Nicol MR, Papacleovoulou G, Evans DB, Vaikkakara S, Mason JI, Quinton R, et al. Adult-onset hypogonadotropic hypogonadism caused by aberrant expression of aromatase in an adrenocortical adenocarcinoma. *Endocr J.* 2010; 57: 651-6.
11. Shearer JL, Salmans N, Murphy DJ, Gama R. Postmenopausal hyperandrogenism: the under-recognized value of inhibins. *Ann Clin Biochem.* 2017; 54: 174-7.
12. Frago MC, Kohek MB, Martin RM, Latronico AC, Lucon AM, Zerbini MC, et al. An Inhibin B and estrogen-secreting adrenocortical carcinoma leading to selective FSH suppression. *Horm Res.* 2007; 67: 7-11.
13. Tanaka YO, Saida TS, Minami R, Yagi T, Tsunoda H, Joshikawa H, et al. MR findings of ovarian tumors with hormonal activity, with emphasis on tumors other than sex cord-stromal tumors. *Eur J Radiol.* 2007; 62: 317-327.
14. Kurman RJ, Carcangiu ML, Herrington CS, Robert JK, Maria LC, Simon HC, et al. World Health Organization Classification of Tumours of Female Reproductive Organs, fourth edition. Lyon: International Agency for Research on Cancer, 2014.
15. Hanley KZ, Mosunjac MB. Practical review of ovarian sex cord-stromal tumors. *Surg Pathol Clin.* 2019; 12: 587-620.
16. Hugon-Rodin J, Kalhorpour N, Borghese B, Bordonne C, Just PA, Gompel A, et al. Inhibin A and inhibin B producing ovarian fibrothecoma revealed by suppression of follicle stimulating hormone (FSH) in a post-menopausal woman: report of the first case. *Gynecol Endocrinol.* 2016; 32: 872-4.
17. Coleman R, Ramirez PT, Gershenson DM. Neoplastic Diseases of the Ovary. Screening, benign and malignant epithelial and germ cell neoplasms, sex-cord stromal tumors. Lobo RA, Gershenson DM, Lentz GM, Valea FA, editors. In: Comprehensive gynecology, Seventh Edition. Elsevier. 2017; 733-80.
18. Burandt E, Young RH. Thecoma of the ovary: A report of 70 cases emphasizing aspects of its histopathology different from those often portrayed and its differential diagnosis. *Am J Surg Pathol.* 2014; 38: 1023-32.