

Research Article

A Ten-Year Experience of Radiotherapy, With or Without Immunosuppression, in the Management of Active, Moderate-to-Severe Thyroid Eye Disease

Teh GH¹, Tan SW², Yong K¹, Sommat K³, Yang M¹, Khoo Tan HS³, Seah LL¹, Looi A^{1*}

¹Department of Singapore National Eye Centre, Third Hospital Avenue, Singapore

²Department of Indah Specialist Eye Centre, Malaysia

³Department of National Cancer Centre, Singapore

*Corresponding author: Audrey Looi, Department of Singapore National Eye Centre, Third Hospital Avenue, Singapore

Received: March 18, 2018; Accepted: May 09, 2018;

Published: May 16, 2018

Abstract

Purpose: To investigate the mid-term outcomes and safety profile of radiation therapy for thyroid eye disease in an Asian population

Methods: A retrospective case review of patients with active, moderate-to-severe thyroid eye disease from Singapore National Eye Centre who underwent orbital radiotherapy from 1st January 2002 to 31st December 2011. Clinical parameters consisting of best-corrected visual acuity, exophthalmometry, ocular motility and inflammatory index were studied before, six months post-radiotherapy and at latest follow-up. Radiotherapy-related complications including cataract, radiation retinopathy and secondary head and neck tumours were documented.

Results: Thirty-eight patients with mean follow-up of 55±34.9 months were identified. Fifty-three percent were female, 47% male. Mean age was 54.7±10.5 years. Eighteen percent had radiotherapy alone, 82% received concurrent immunosuppression. Ninety percent of patients with compressive optic neuropathy had improvement in vision after treatment. There was significant reduction in disease activity ($p<0.001$) and ocular motility improvement ($p<0.05$) following radiotherapy. After excluding patients who underwent surgical decompression, a small but significant reduction in proptosis ($p<0.05$) was observed. Most common local side effect was cataracts (16%). No radiation retinopathy or secondary head and neck tumours were detected.

Conclusions: Amidst the controversy over the efficacy of radiotherapy for thyroid eye disease, our study supports the opinion that orbital radiotherapy is an effective treatment modality for active, moderate-to-severe thyroid eye disease. In addition to reducing disease activity and improving ocular motility, a small but significant improvement in proptosis was also seen in our patient cohort. The complications were limited to the development of cataracts.

Keywords: Thyroid Eye Disease; Radiotherapy; Immunosuppression

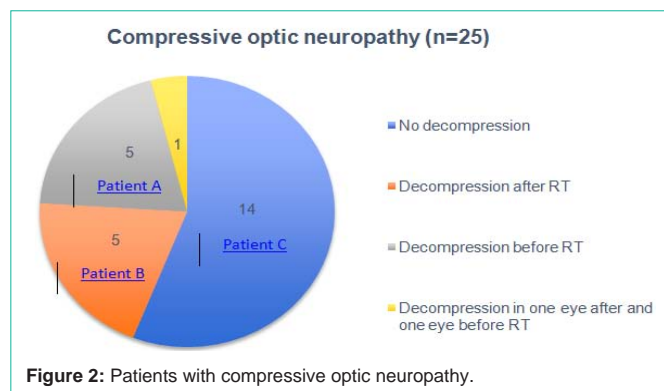
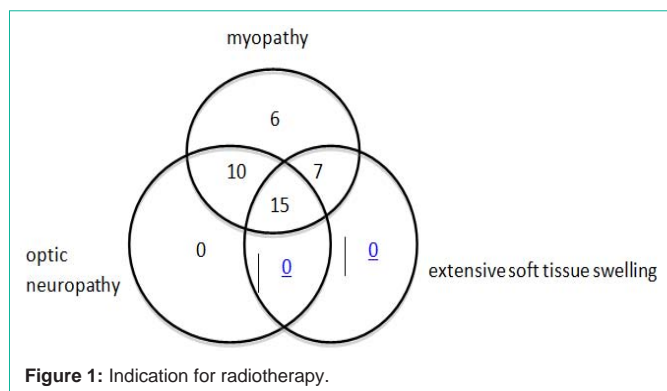
Introduction

Thyroid eye disease is the most common cause of proptosis and eyelid retraction in adults, and can cause adult-onset strabismus as well as compressive optic neuropathy. The main treatment modality for active thyroid eye disease is suppression of activated orbital T lymphocytes and fibroblasts with systemic corticosteroids and other second line agents [2,3]. However, these medications are associated with many systemic side effects [4-6]. Radiation therapy is an alternative treatment as the activated T-cells and fibroblasts are radiosensitive and therapy can be delivered locally with minimal systemic side effects [7,8]. Despite being in use for decades, there is conflicting evidence with regards to its efficacy; not withstanding concerns of radiotherapy-related local side effects as well as radiation-induced secondary malignancies [9-16]. To our knowledge, the mid-term outcomes and safety profile of radiation therapy for thyroid eye disease has not been studied specifically in a multi-ethnic Asian population.

Methods

With institutional review board approval, we performed a retrospective case review of all patients with active, moderate-to-severe thyroid eye disease from the Singapore National Eye Centre who underwent orbital radiotherapy at the Department of Radiation Oncology, National Cancer Centre, Singapore, from 1st January 2002 to 31st December 2011. The definition for thyroid eye disease was based on Bartley's description [3]. Exclusion criteria included patients who had head and neck radiation for reasons other than thyroid eye disease and follow-up period of less than six months.

Baseline demographic and background data consisting of gender, age at time of orbital radiotherapy, ethnicity, past medical history, smoking history, current medications and systemic thyroid status were recorded. The time interval between the start of eye symptoms to first presentation was documented to determine if delay in treatment made a difference to the final visual outcome. Other modalities of treatment for thyroid eye disease, which included oral or intravenous steroids,



methotrexate or surgical decompression, were also documented. Clinical parameters measured were Snellen visual acuity, colour vision (with Ishihara’s colour plates), pupillary reflexes, intraocular pressure, optic disc head appearance, Hertel’s exophthalmometry and inflammatory score using the VISA classification [17]. Visual fields were not included as a clinical parameter as not all patients underwent visual field tests. Similarly, the field of binocular single vision could not be studied as majority of patients had incomplete records. The clinical parameters were studied on presentation, six months and one year post-radiotherapy and on the last follow-up visit.

The presence of complications associated with orbital radiotherapy - specifically, the development of cataracts and radiation retinopathy, were documented on each follow-up visit. Telephone enquiry regarding development of head and neck cancer was conducted for all patients. Cross checking with National Cancer Center’s Cancer Registry was also done to detect documentation of any secondary head and neck tumours not reported by patients.

For data analysis, the statistical program SPSS version 20.0 was used. Paired sample T-test was used for normally distributed data sets. Significance was assumed if $p \leq 0.05$.

Technique of orbital radiotherapy

Radiotherapy was performed by a radiation oncologist at the National Cancer Centre, Singapore. Treatment was targeted at the retrobulbar contents of the orbit and a cumulative dose of 20Gy was delivered in ten fractions over a two-week period using two parallel opposed fields.

Results

Patient demographics

A total of 45 patients were identified. However, only 38 patients who completed at least six months follow-up were included in the study. The gender distribution was similar with 20 females and 18 males. The mean age of the patients was 54.7 years (range 26 to 79 years old). Patients were predominantly Chinese (N=30, 79%), followed by Malay (N=4, 11%), Indian (N=2, 5%) with one Japanese and one Indonesian patient. Seven (18%) patients had diabetes mellitus and six patients (16%) were smokers. The follow-up period ranged from 8 to 120 months with a mean follow-up period of 55 ± 34.9 months (Table 1). Summarizes the characteristics of patients in this series.

Indication and timing of orbital radiotherapy

The indications for radiotherapy in our patient cohort were

Table 1: Demographics and clinical characteristics.
*1: patient was Indonesian; 1: Patient was Japan.

		(N=38)
Gender	Male	18 (47%)
	Female	20 (53%)
Mean age (years)	Male	54.7
	Female	55
Race	Chinese	30 (79%)
	Malay	4 (11%)
	Indian	2 (5%)
	Others	2 (5%)
Systemic illness	Diabetes mellitus	7 (18%)
	Hypertension	15 (39%)
	Ischaemic heart disease	4 (11%)
	Hyperlipidemia	9 (24%)
Smoking status	Smokers	6 (16%)
	Non Smokers	31 (82%)
	Unknown	1 (2%)

compressive optic neuropathy, myopathy and extensive soft tissue swelling. Most of the patients had a combination of factors-15 patients (39%) had concurrent myopathy, compressive optic neuropathy and soft tissue swelling; while ten patients (26%) had combined factors of myopathy and compressive optic neuropathy (Figure 1). The mean interval from development of thyroid eye disease symptoms to orbital radiotherapy was 22.9 months (range 2 months to 50 years). The one patient who required orbital radiotherapy 50 years after from onset of symptoms, only presented with diplopia at 60 years old. She was diagnosed with Graves disease at 11 years old; had undergone thyroidectomy surgery and was on Thyroxine replacement therapy. The indication for orbital radiotherapy, in this instance, was reactivation with worsening diplopia from myopathy. In addition, she was medically unfit for pulsed steroid therapy. Her strabismus stabilised following orbital radiotherapy and she eventually underwent strabismus surgery which finally eliminated her diplopia.

Concurrent immunosuppression

Thirty-one patients (82%) received concurrent immunosuppression (systemic steroids or methotrexate) and seven patients (18%) did not have any form of immunosuppression. This

Table 2: Exophthalmometry measurements with time.

	Proptosis (mm)					
	All patients			Without surgical decompression patients		
	Baseline (n=38)	>1 year (n=32)	P	Baseline(n=25)	>1 year (n=22)	p
Right eye	21.6±3.2	19.1±4.0	0.005	22.3±3.1	20.2±3.9	0.004
Left eye	21.9±3.2	18.8±5.0	0.003	22.0±3.2	19.8±3.9	0.001

Table 3: Inflammatory index over time.

	Baseline	6 months	1 Year	Latest
Inflammatory Index	n=38	n=36	n=36	n=31
	4.1±1.2	1.5±1.3	1.0±1.1	0.7±1.1
p		<0.001	<0.001	<0.001

was due to medical contraindications in five patients (presence of underlying infection in four patients and one patient had high cardiovascular risk); one patient had poor compliance to follow-up and the final patient refused immunosuppressive treatment.

Exophthalmometry readings

The mean exophthalmometry reading for all patients at baseline was 21.6±3.2 mm (right eye) and 21.9±3.2 mm (left eye). Overall, there was a significant reduction in proptosis after radiotherapy ($p<0.05$) in both orbits with mean exophthalmometry readings of 19.1±4 mm (right eye) and 18.8±5 mm (left eye) respectively at latest follow-up period (Table 2).

In order to ascertain the effect of radiotherapy on proptosis, we performed further analysis and comparison after excluding 13 patients who had undergone surgical decompression. The mean exophthalmometry measurement before radiotherapy in patients who did not undergo surgical decompression was 22.3±3.1 mm (right eye) and 22.0±3.2 mm (left eye) (Table 2). At the end of the follow-up period, there was a statistically significant reduction in proptosis bilaterally in all patients compared to baseline (right eye 20.2 ± 3.9 mm, left eye 19.8 ± 3.9 mm) (Table 2).

There was no loss of vision in all patients post-radiotherapy. However three patients (A, B and C) did not have improvement in visual acuity post-radiotherapy. They will be discussed in detail further below.

Compressive optic neuropathy was the largest treatment indication group (N=25). 36% (9 patients) had bilateral and 64% (16 patients) had unilateral compressive optic neuropathy. 11 patients underwent surgical decompression-five patients had surgical decompression prior to radiotherapy (of which, patient A belongs to this group); five patients after radiotherapy; and one patient had bilateral decompression where surgery in one eye was performed before radiotherapy and the fellow eye after radiotherapy (Figure 2).

Within this group of patients who had compressive optic neuropathy, of particular interest were those who still required surgical decompression after completion of radiotherapy (6 patients), as well as three patients (A, B and C) whose vision remained poor at the end of treatment.

Of the six patients with compressive optic neuropathy that required surgical decompression after radiotherapy, three patients

underwent surgical decompression as their visual acuity failed to improve following orbital radiotherapy. Only one patient (patient B) from this group saw no improvement in visual acuity in one eye despite surgical decompression following radiotherapy. The remaining three patients' optic neuropathy resolved post-radiotherapy, but surgical decompression in this instance was done for persistent orbital congestion (two patients) and proptosis with exposure keratopathy (one patient).

Patients A, B and C

Vision in all but three patients (A, B and C) improved post-radiotherapy. All three patients had bilateral compressive optic neuropathy with asymmetrical involvement, and were treated with pulsed steroid therapy and orbital radiotherapy concurrently.

Patient A belongs to the group of patients who had surgical decompression before radiotherapy. She presented at 58 years of age with a visual acuity of counting fingers in the right eye and 6/12 in the left eye for at least three months prior to presentation. She had asymmetrical involvement with right eye being more severely affected; as evidenced by the poorer visual acuity, presence of right relative afferent pupillary defect and inability to identify any ishihara plates on colour vision test. Intravenous methylprednisolone saw no improvement in vision; hence she underwent bilateral surgical decompression which allowed the vision of her left eye to improve to 6/7 [5]. Although she reported an improvement in her right visual field, the vision in that eye remained at counting fingers. She underwent radiotherapy a month after surgical decompression as the thyroid eye disease was still active and she was medically unfit for further cycles of pulsed steroid therapy. The radiotherapy did not improve vision further, but did help to achieve disease quiescence.

Patient B was 64 years old at the time of presentation, and had poor vision (counting fingers in the right eye and 6/15 in the left eye) for three months prior to seeking ophthalmological consult. She presented with bilateral optic neuropathy, worse on the right eye. Similar to patient A, this was clinically evident as impaired colour vision and visual fields. Initial pulsed steroid therapy failed to improve her vision and she subsequently received orbital radiotherapy. Her visual acuity improved in her left eye to 6/9, but was maintained at counting fingers in her right eye. She underwent right surgical decompression a month later but her right eye's visual acuity did not improve further.

Patient C was 55 years old when she presented to the clinic with sudden onset blurring in vision two days prior to her visit. Her visual acuity at presentation was 6/12 in the right eye and no light perception in the left eye. She had bilateral optic nerve compression which worse on the left eye, as evidence by much poorer visual acuity and colour vision as well as a left relative afferent pupillary defect. She received pulsed intravenous steroid therapy and her vision improved

Table 4: Extraocular motility

[†]p<0.05: (compared with baseline); [‡]p<0.01: (compared with baseline); [§]p<0.001: (compared with baseline); [¶]p>0.05: (compared with baseline).

Ductions (degrees)	Baseline (n=35)	6months (n=35)	1 year (n=35)	Latest (n=35)
Elevation				
Right eye	16.6±8.4	23.1±9.3 [¶]	24.4±11.0 [¶]	23.9±10.7 [‡]
Left eye	17.7±10.7	24.0±9.9 [‡]	22.0±10.5 [‡]	23.8±10.8 [‡]
Depression				
Right eye	32.0±13.1	40.7±9.9 [‡]	41.0±10.6 [‡]	43.2±8.6 [¶]
Left eye	34.4±12.1	41.3±9.4 [‡]	42.9±9.9 [‡]	43.0±8.7 [‡]
Abduction				
Right eye	30.3±13.0	34.9±13.3 [‡]	35.4±13.3 [‡]	38.8±11.2 [¶]
Left eye	27.7±10.6	34.7±13.1 [‡]	35.7±12.8 [¶]	37.1±11.1 [¶]
Adduction				
Right eye	25.0±9.8	30.1±9.8 [‡]	34.5±9.5 [¶]	35.6±10.6 [¶]
Left eye	26.0±10.6	31.4±9.3 [‡]	34.4±9.5 [‡]	35.5±8.5 [¶]

to 6/6 in the right eye, but improved only minimally in her left eye to counting fingers closely. Hence, she was planned for bilateral orbital decompression surgery. However, she suffered a cerebellar infarct just before surgery and was deemed too high risk for general and anesthesia to proceed with surgical decompression. As a result, she underwent orbital radiotherapy which helped control disease activity. Unfortunately, the visual acuity in the left eye remained at counting fingers closely.

Disease activity outcome

All 38 patients had reduction in inflammatory index post-radiotherapy and the change in disease activity score was statistically significant (p<0.001). Mean inflammatory index at baseline was 4.1±1.2, which improved to 1.5±1.3 at 6 months post radiotherapy and 0.7±1.1 at latest follow-up visit Table 3. One patient still had residual disease activity post-radiotherapy and required an additional cycle of intravenous methylprednisolone after radiotherapy before he achieved disease quiescence.

Ocular motility outcome

Ocular motility post-radiotherapy was documented in all but three patients at six months post-radiotherapy. The pre-treatment ductions support the clinical observation that the inferior rectus was the most severely affected muscle group, with restrictions in upgaze being more prominent at baseline. There was statistically significant improvement in ocular motility in all directions of gaze post-radiotherapy (Table 4).

Ancillary treatment post-radiotherapy

A total of eight patients underwent orbital decompression after radiotherapy. Orbital decompression was performed within six months (mean 2.7 ± 2 months) post-radiotherapy in seven patients who had partial or no improvement with radiotherapy. This includes the previously mentioned six patients with compressive optic neuropathy. The indications for surgery in the other two patients were persistent exposure keratopathy and cosmetically significant proptosis.

Complications

Six patients (15.8%) who did not have any documented cataracts

at baseline developed cataracts after radiotherapy after a mean period of 41.2 months post radiotherapy (range 5-108 months). The mean age of these patients was 54.3±8.2 years and this did not differ significantly from the patients who did not develop cataracts post-radiotherapy. Three patients from this group underwent cataract surgery. No patients developed radiation retinopathy or head and neck tumours following radiotherapy. One male patient developed breast cancer four months post-radiotherapy.

Two patients passed away at the time of writing and both deaths were not due to orbital radiation-related complications. The cause of death was pneumonia in one and ischaemic heart disease in the other.

Discussion

Orbital irradiation has been used to treat thyroid eye disease for over 60 years. However, controversies regarding its efficacy and reservations regarding the potential side effects somewhat limit its use [7-18,20-22]. Majority of studies have focused primarily on the Caucasian population [3-21,28-31] and there are considerably fewer reports in the literature on orbital radiotherapy for thyroid eye disease in Asians [2-27].

Although orbital radiotherapy has been widely acknowledged to be effective in promoting disease quiescence, there are still lingering questions regarding its effects on ocular dysmotility and proptosis [7-9,17-20,22-24,26-31], with many studies showing conflicting results with regards to reduction in exophthalmos and muscle volume.

Our study primarily addressed the effect of orbital radiotherapy on moderate to severe thyroid eye disease and its side effects over a ten-year period. Notably, in our study population of multi-ethnic Asian patients with active, moderate-to-severe thyroid eye disease, and our results showed a favorable response in all three clinical parameters.

All except one of our patients showed significant improvement in disease activity following orbital radiotherapy, with disease quiescence well maintained until the last follow-up visit. The patient who still had persistent inflammatory activity post-radiotherapy required an additional cycle of intravenous methylprednisolone four months post-radiotherapy before the inflammation subsided. It can

be observed in our study that a vast majority of patients (82%) were treated with a combination of radiotherapy and immunosuppressive medications, which is the preferred treatment practice in our institution. Timing is of key importance in the effective administration of immunosuppression and radiotherapy, and the prime radiation sensitive period is during the active progressive phase of thyroid eye disease [17,30,31]. Evidence from various studies strongly suggests that radiotherapy offers little to no benefit in patients with “burnt-out” non-progressive disease. Thus, patients who have failed immunosuppressive therapy with systemic steroids are unlikely to benefit from orbital radiotherapy [17-20,23,24,30,31]. A timely, multi-pronged treatment approach has been proven in many studies to be synergistic with long-lasting effects [24-31] and may be one of the factors contributing to the favorable response in our group of patients

Amidst conflicting reports on the effects of orbital radiotherapy on ocular dysmotility and proptosis [7-9,12,16,20], our study shows that both parameters responded well to orbital radiotherapy. The improvement was already apparent as early as six months post-radiotherapy and continued until patients' latest follow-up visit. It is worthwhile noting that within the subgroup of our patients who did not undergo surgical decompression, there was a small but significant improvement of proptosis after orbital irradiation Table 2. The effect of orbital radiotherapy on proptosis has long been one of the most widely debated issues [7-12,16,20,29-31]. A few studies quoted a trend in proptosis reduction [9,26,30,36], but most still refute the effects of radiotherapy on proptosis [8,12,20,22-26]. Our study shows that the improvement in proptosis in our patients was evident at one year post-radiotherapy and beyond at the final follow-up visit.

One of the few controversial issues in our patient cohort was the use of orbital radiotherapy in patients who have diabetes mellitus. The presence of diabetes mellitus has been traditionally considered a relative contraindication to orbital radiotherapy due to the compromised retinal vasculature and increased susceptibility to radiation retinopathy [11,14,15]. In our study, seven patients with established diabetes mellitus but no diabetic retinopathy underwent orbital radiotherapy. Of these seven patients, four had early stage diabetes mellitus, one patient was medically unfit for surgical orbital decompression due to multiple comorbidities (recent cerebrovascular accident and multiple vascular risk factors) and the remaining two patients had already exhausted all treatment options (both had multiple cycles of intravenous methylprednisolone as well as surgical decompression prior to orbital radiotherapy without much improvement). These patients were co-managed with their attending physician, with whom the decision to proceed with radiotherapy was made, based on the absence of diabetic retinopathy. Our study found that none of these patients developed radiation retinopathy. Although a longer follow-up period would be required for a more conclusive outcome, our midterm data supports current evidence that radiation retinopathy is rare with the radiation dosage in thyroid ophthalmopathy treatment protocol [9-15,17,36,37].

In analyzing the visual outcome, we would like to address the limited visual improvement in three patients within the compressive optic neuropathy group. The poor visual outcomes in the three patients (patients A, B and C) may be attributed to several factors. These patients represent the extreme end of the severe spectrum

of thyroid eye disease and the situation may have been further compounded by the delay in presentation, particularly in elderly patients with a preference for non-surgical options. While there are reports of radiation induced optic neuropathy [39,40], in patients with active thyroid eye disease who received radiotherapy, this is an unlikely cause of the limited visual outcome since none of our patients experienced an acute worsening in visual acuity or symptoms following radiotherapy. The presence of bilateral optic neuropathy with a relative afferent pupillary defect does suggest that these patients could have had a much longer duration of optic nerve compression, albeit asymmetrically and only sought help when the better eye also became similarly affected. In this group of severe, late-presentation, elderly patients, the authors believe that the best treatment approach would be to start immunosuppression as soon as possible and plan for an early surgical decompression that includes medial wall, floor and aggressive lateral wall decompression, leaving only a thin anterior orbital rim or to consider removing the lateral rim entirely. Radiotherapy could follow if disease activity was still observed after decompression surgery.

Adverse effects observed in our series were mild and mainly limited to the development of cataracts (15.8%); these findings were consistent with other studies which reported incidence of cataract development from 10 to 29% [9-11,14]. A noteworthy point was that all patients who developed cataracts in our study had also received concurrent high-dose glucocorticoid therapy, which could be a contributory factor towards cataract development. Yet despite this, none of our patients who had radiotherapy alone developed cataracts. However, the numbers were too small to show statistical significance. There were no secondary head and neck malignancies developing within the treatment field in our group of patients. Arguably, the follow-up period in our patient group was too short and may account for our findings being prematurely uneventful. It would be worthwhile to pursue long term follow-up of this group, in particular those who underwent orbital radiotherapy at younger age, due to the long latency of radiation-induced carcinogenesis and the 0.6-1.4% theoretical risk of tumour formation [32,33]. The solitary case of malignancy (breast cancer diagnosed in a male patient six months following orbital radiotherapy), drew parallel comparisons to a previously published case report [34]. It is however, unlikely that the breast cancer could be attributed to orbital irradiation as the affected area was far from the irradiated field. Thyroid orbitopathy on its own, however, has been shown to be associated with higher risk of cancer, particularly breast and thyroid cancer [35].

Many of the limitations of this study can be attributed to the small number of study subjects. This significantly reduces the impact of the results in the smaller treatment indication subgroups, namely the ocular dysmotility subgroup and combined muscle and soft tissue disease group (Figure 1). Although the favorable results in these two treatment groups were apparent, a larger treatment group would help in strengthening conclusions on the effect of radiotherapy on muscle dysmotility and soft tissue changes. This study however demonstrates clearly the effectiveness of orbital radiotherapy combined with immunosuppression in patients with compressive optic neuropathy. Strength of our study lies in our inclusion of patients with compressive optic neuropathy, whereas previous randomized controlled trials of radiotherapy in thyroid orbitopathy patients excluded them. This

study lends weight to evidence supporting the use of combination therapy with radiotherapy and immunosuppression as a viable treatment option for patients with compressive optic neuropathy [17,28,41], particularly those who are unsuitable or unwilling to undergo surgical decompression. However, “res ipsa loquitur”, and some patients may still require surgical decompression following radiotherapy—this ought to be conveyed to patients prior to embarking on radiotherapy.

Conclusion

We found that orbital radiotherapy, alone or in combination with immunosuppression, to be a safe and effective modality of treatment for active, moderate-to-severe thyroid eye disease with improvements seen in disease activity, visual acuity, ocular motility and proptosis.

The only complication observed was the development of cataracts. Radiation retinopathy was not encountered even in those with diabetes mellitus and no secondary head and neck tumours were detected during the study period. The study was limited by the relatively short period of follow-up and lack of an age-matched control group as some of the changes, in particular the development of cataracts, could also be attributed to increasing age as well as concurrent glucocorticoid therapy. Despite these limitations, our results demonstrate the important role of orbital radiotherapy as an effective tool in the armamentarium of treatment options for thyroid eye disease.

Compliance with Ethical Standards

Conflict of interest: All authors declare that we have no conflict of interest.

Ethical approval: All procedures performed in studies involving human participants were in accordance with the ethical standards of the institutional and/or national research committee and with the 1964 Helsinki declaration and its later amendments or comparable ethical standards.

Precis

Orbital radiotherapy alone or combined with immunosuppressive therapy is an effective and safe treatment modality for active, moderate-to-severe, thyroid eye disease in Asian eyes.

Informed consent

Informed consent was obtained from all individual participants included in the study.

References

- Werner SC. The eye changes of Graves' disease. *Mayo Clin Proc.* 1972; 47: 969-974.
- Burch HB, Wartofsky L. Graves' ophthalmopathy: current concepts regarding pathogenesis and management. *Endocr Rev.* 1993; 14: 747-793.
- Bartalena L, Pinchera A, Marcocci C. Management of Graves' ophthalmopathy: reality and perspectives. *Endocr Rev.* 2000; 21: 168-199.
- Donihi AC, Raval D, Saul M, Korytkowski MT, DeVita MA. Prevalence and predictors of corticosteroid-related hyperglycemia in hospitalized patients. *Endocr Pract.* 2006; 12: 358-362.
- Pecora PG, Kaplan B. Corticosteroids and ulcers: is there an association? *Ann Pharmacother.* 1996; 30: 870-872.
- Yanoff M. Cataract formation mechanisms. In: Yanoff M, Duker JS, eds. *Ophthalmology.* St. Louis: Mosby International Ltd. 1999; 8: 3-5.
- Bartalena L, Marcocci C, Manetti L, Mazzi B, Barbesino G, Pinchera A, et al. Orbital radiotherapy for Graves' ophthalmopathy. *Thyroid.* 1998; 8: 439-441.
- Mourits MP, van Kempen-Harteveld ML, Garcia MB, Koppeschaar HP, Tick L, Terwee CB. Radiotherapy for Graves' orbitopathy. *Lancet.* 2000; 355: 1505-1509.
- Marquez SD, Lum BL, McDougall IR, Levin PS, MacManus M, Donaldson SS, et al. Long-term results of irradiation for patients with progressive Graves' ophthalmopathy. *Int J Radiat Oncol Biol Phys.* 2001; 51: 766-774.
- Schaefer U, Hesselmann S, Micke O, Bruns F, Palma C, Willich N, et al. A long-term follow-up study after retro-orbital irradiation for Graves' ophthalmopathy. *Int J Radiat Oncol Biol Phys.* 2002; 52: 192-197.
- Wakelkamp I, Tan H, Saeed P, Schlingemann RO, Verbraak FD, Blank LE, et al. Orbital irradiation for Graves' ophthalmopathy: Is it safe? A long-term follow-up study. *Ophthalmology.* 2004; 111: 1557-1562.
- Bradley EA, Gower EW, Bradley DJ, Meyer DR, Cahill KV, Custer PL, et al. Orbital radiation for Graves's ophthalmopathy. A report by the American Academy of Ophthalmology. *Ophthalmology.* 2008; 115: 398-409.
- Gorman CA, Garrity JA, Fatourechi V, Bahn RS, Petersen IA, Stafford SL, et al. The aftermath of orbital radiotherapy for Graves' ophthalmopathy. *Ophthalmology.* 2002; 109: 2100-2107.
- Marcocci C, Bartalena L, Rocchi R, Marinò M, Menconi F, Morabito E, et al. Long-term safety of orbital radiotherapy for Graves Ophthalmopathy. *J Clin Endocrinol Metab.* 2003; 88: 3561-3566.
- Kinyoun JL, Kalina RE, Brower SA. Radiation retinopathy after orbital irradiation for Graves' ophthalmopathy. *Arch Ophthalmol.* 1984; 102: 1473-1476.
- Snijders-Keilholz A, De Keizer RJ, Goslings BM, Van Dam EW, Jansen JT, Broerse JJ, et al. Probable risk of tumour induction after retro-orbital irradiation for Graves' ophthalmopathy. *Radiother Oncol.* 1996; 40: 187-189.
- Dolman PJ, Rath S. Orbital radiotherapy for thyroid eye disease. *Curr Opin Ophthalmol.* 2012; 23: 427-432.
- Mourits MP. Does radiotherapy have a role in the management of thyroid orbitopathy? *Br J Ophthalmol.* 2002; 86: 102-104.
- Dolman PJ, Rootman J. VISA Classification for Graves's orbitopathy. *Ophthalm Plast Reconstr Surg.* 2006; 22: 319-324.
- Gorman CA, Garrity JA, Fatourechi V, Bahn RS, Petersen IA, Stafford SL, et al. A prospective randomized, double-blind, placebo-controlled study of orbital radiotherapy for Graves' ophthalmopathy. *Ophthalmology.* 2001; 108: 1523-1534.
- Perros P, Baldeschi L, Boboridis K, Dickinson AJ, Hullo A, Kahaly GJ, et al. A questionnaire survey on the management of Graves' orbitopathy in Europe. *Eu J Endocrinol.* 2006; 155: 207-211.
- Ohtsuka K, Sato A, Kawaguchi S. Effect of steroid pulse therapy with and without orbital radiotherapy on Graves' ophthalmopathy. *Am J Ophthalmol.* 2003; 135: 285-290.
- Tsujino K, Hirota S, Hagiwara M, Fukada S, Takada Y, Hishikawa Y, et al. Clinical outcomes of orbital irradiation combined with or without systemic high-dose or pulsed corticosteroids for Graves' ophthalmopathy. *Int J Radiat Oncol Biol Phys.* 2000; 48: 857-864.
- Ng CM, Yuen HK, Choi KL, Chan MK, Yuen KT, Ng YW, et al. Combined orbital irradiation and systemic steroids compared with systemic steroids alone in the management of moderate-to-severe Graves's ophthalmopathy: A preliminary study. *Hong Kong Med J.* 2005; 11: 322-330.
- Prummel MF, Mourits MP, Blank L, Berghout A, Koornneef L, Wiersinga WM, et al. Randomized double-blind trial of prednisone versus radiotherapy in Graves' ophthalmopathy. *Lancet.* 1993; 342: 949-954.
- Kim JW, Han SH, Son BJ, Rim TH, Keum KC, Yoon JS, et al. Efficacy of combined orbital radiation and systemic steroids in the management of Graves' orbitopathy. *Graefes Arch Clin Exp Ophthalmol.* 2016; 254: 991-998.

27. Kim JW, Lee KH, Woo YJ, Kim J, Keum KC, Yoon JS, et al. The effect of systemic steroids and orbital radiation for active Graves's orbitopathy on post decompression extraocular muscle volume. *Am J Ophthalmol*. 2016; 171: 11-17.
28. Bartalena L, Marcocci C, Chiovato L, Laddaga M, Lepri G, Andreani D, et al. Orbital cobalt irradiation combined with systemic corticosteroids for Graves' ophthalmopathy: Comparison with systemic corticosteroids alone. *J Clin Endocrinol Metab*. 1983; 58: 1139-1144.
29. Marcocci C, Bartalena L, Bogazzi F, Bruno-Bossio G, Lepri A, Pinchera A, et al. Orbital radiotherapy combined with high dose systemic glucocorticoids for Graves' ophthalmopathy is far more effective than radiotherapy alone: Results of a prospective randomized study. *J Endocrinol Invest*. 1991; 14: 853-860.
30. Viani GA, Boin AC, De Fendi LI, Fonseca EC, Stefano EJ, Paula JS, et al. Radiation therapy for Graves' ophthalmopathy: A systematic review and meta-analysis of randomized controlled trials. *Arq Bras Otolmol*. 2012; 75: 324-332.
31. Rajendram R, Bunce C, Lee RW. Orbital radiotherapy for adult thyroid eye disease. *Cochrane Database Syst Rev*. 2012.
32. Broerse JJ, Snijders-Keilholz A, Jansen JTM, Zoetelief J, Klein C, Seegenschmiedt MH, et al. Assessment of a carcinogenic risk factor for treatment of Graves ophthalmopathy in dependence of age and irradiation geometry. *Radiother Oncol*. 1999; 53: 205-208.
33. Snijders-Keilholz A, De Keizer RJW, Goslings BM, Van Dam EW, Jansen JT, Broerse JJ, et al. Probable risk of tumour induction after retro-orbital irradiation for Graves's ophthalmopathy. *Radiother Oncol*. 1996; 38: 69-71.
34. Santhos CT, Howe FY, Fong KS. Breast cancer in a male with thyroid-associated orbitopathy and subclinical hyperthyroidism: A rare occurrence. *Orbit*. 2009; 28: 162-165.
35. Chen YK, Lin CL, Chang YJ, Peng CL, Sung FC, Cheng YH, Kao CH, et al. Cancer risk in Graves' disease: A nationwide cohort study. *Thyroid*. 2013; 23: 879-884.
36. Hahn E, Laperriere N, Millar BA, Oestreicher J, McGowan H, Krema H, et al. Orbital radiation therapy for Graves' ophthalmopathy: Measuring clinical efficacy and impact. *Pract Radiat Oncol*. 2014; 4: 233-239.
37. Chundury RV, Weber AC, Perry JD. Orbital radiation therapy in thyroid eye disease. *Ophthal Plast Reconstr Surg*. 2016; 32: 83-89.
38. Verity DH, Rose GE. Acute thyroid eye disease (TED): Principles of medical and surgical management. *Eye (Lond)*. 2013; 27: 308-319.
39. Hersh D, Kinnar M. Acute dysthyroid optic neuropathy exacerbated by orbital radiotherapy. *Orbit*. 2014; 33: 385-387.
40. Sanchez-Orgaz M, Grabowska A, Royo-Oreja A, Asencio-Durán M, Romero-Martín R, Arbizu-Duralde A. Optic neuropathy following orbital irradiation for Graves' ophthalmopathy: A case report and literature review. *Orbit*. 2012; 31: 30-33.
41. Shams PN, Ma R, Pickles T. Reduced risk of compressive optic neuropathy using orbital radiotherapy in patients with active thyroid eye disease. *Am J Ophthalmol*. 2014; 157: 1299-1305.