

Case Report

Multiple Complications of Severe Hyperandrogenism in a Postmenopausal Woman

Capatina C^{1,2*}, Alexandru Scafa-Udriste¹, Adela Ghinea², Anda Dumitrascu² and Catalina Poiana^{1,2}

¹"Carol Davila" University of Medicine and Pharmacy, Romania

²National Institute of Endocrinology and Metabolism, Romania

*Corresponding author: Cristina Capatina, National Institute of Endocrinology and Metabolism, "Carol Davila" University of Medicine and Pharmacy, 34-36 Aviatorilor Ave, Bucharest, Romania

Received: April 11, 2018; Accepted: May 08, 2018;

Published: May 18, 2018

Abstract

Introduction: Severe hyperandrogenism in postmenopausal women has frequently a neoplastic etiology and is associated with an increased risk of cardiovascular, respiratory, metabolic complications as well as with higher risk of endometrial or breast cancer.

Case Report: An obese 68 years-old diabetic woman with a recent history of severe arterial hypertension, cardiogenic pulmonary edema, respiratory failure, worsening of glycemic values was referred to our department due to the severely androgenic phenotype. The clinical examination showed android obesity, very severe male-pattern alopecia, important hirsutism, coarse voice. The cardiological examination revealed severe, resistant arterial hypertension with hypertrophic cardiomyopathy and congestive heart failure. Severe chronic respiratory failure and obstructive sleep apnea syndrome were also present. The patient had extremely elevated serum testosterone level, hyperestrogenism, normal serum levels of the adrenal androgens. Computed tomography of the abdomen revealed a tumoral mass in the right ovary and markedly increased uterine volume and endometrial hyperplasia. Surgery was performed and revealed a benign ovarian thecoma with no suspicious endometrial findings. Significant clinical improvement was noted as early as one month after surgery.

Conclusion: The presence of severe hyperandrogenism in a postmenopausal women should prompt the search for an androgen-secreting tumor and can be associated with important complications.

Keywords: Hyperandrogenism; Hyperestrogenism; Postmenopausal woman; Complications; Thecoma

Introduction

Hyperandrogenism is not uncommon in young, premenopausal women (most frequently caused by polycystic ovary syndrome) but new onset hyperandrogenism is a relatively rare occurrence in postmenopausal women. In these cases, the investigation should necessarily be directed toward an androgen-secreting tumor, especially if serum androgen concentrations are very high. Severe hyperandrogenism is associated with cardiovascular, respiratory and metabolic complications, partly mediated by hyperinsulinism [1,2]. It also increases the neoplastic risk (endometrial, breast cancer) because of the secondary hyperestrogenism (resulting from the aromatisation of the excessive androgens) [3,4].

Case Report

We report the case of 68 years-old woman with a recent history of severe arterial hypertension presenting as cardiogenic pulmonary edema, recent-onset diabetes mellitus, severe respiratory failure and marked, progressive obesity. She was referred to our department mainly due to her severely androgenic phenotype (developed during the last 18 months before admission).

The clinical examination showed android obesity, severe male-pattern alopecia (Figure 1), marked hirsutism involving the face but especially the trunk, deepening of the voice.

Severe, resistant arterial hypertension with hypertrophic cardiomyopathy and congestive heart failure was also present. The patient associated chronic respiratory failure, severe obstructive sleep apnea syndrome, recent-onset diabetes mellitus (maximum blood glucose 211 mg/dl, HbA1c of 6.8%).

The endocrine evaluation revealed: erythrocytosis, extremely elevated serum testosterone level, high serum estradiol- by aromatization of androgens, low gonadotropins discordant with the postmenopausal status - caused by the increase in estradiol and testosterone levels- Table 1, normal adrenal function.

Computed tomography of the abdomen showed normal adrenal glands, right ovarian tumor, markedly increased uterine volume with severe endometrial hyperplasia- Figure 2.

Surgery was recommended and performed, with significant early clinical improvement. As soon as 3 weeks after surgery the blood pressure and glycemic control improved markedly. The histopathological examination revealed a benign sex cord-stromal tumor (thecoma) with no suspicious endometrial findings.

Discussion

Severe hyperandrogenism in a postmenopausal woman is a relatively rare occurrence and should raise the suspicion of a tumoral cause. Women with androgen-secreting tumors typically present

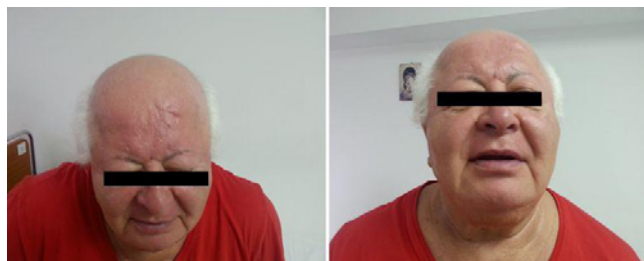

Figure 1: Clinical appearance of the patient showing severe signs of androgen excess.

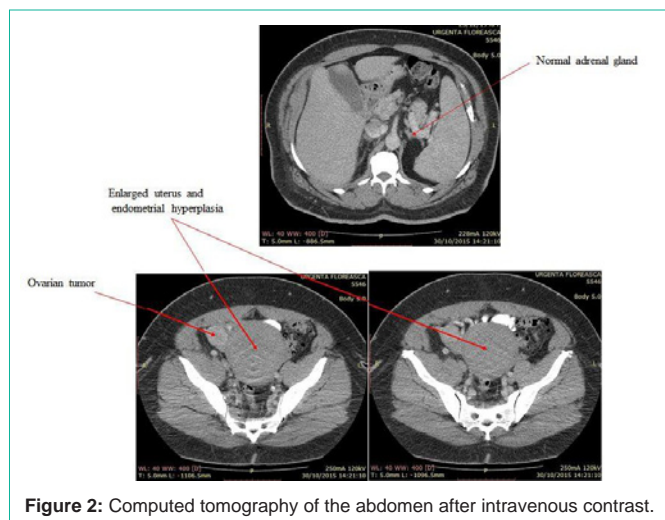


Figure 2: Computed tomography of the abdomen after intravenous contrast.

with recent-onset, rapidly progressive hirsutism. Approximately 80% of ovarian androgen-secreting neoplasms result in testosterone levels above 150 ng/dL (5.2 nmol/L), often well over 200 ng/dL. Recent, rapidly progressive virilisation and a serum total testosterone >150 ng/dL (5.2 nmol/L), should suggest a neoplastic source of hyperandrogenism.

Such high androgen levels are associated with a number of serious possible complications. Several epidemiological studies in men have shown an inverse relationship between serum testosterone levels and several cardiovascular risks factors (eg diabetes mellitus, increased visceral adiposity, insulin resistance and metabolic syndrome) [5,6]. In contrast, in men primarily diagnosed with obesity and metabolic syndrome serum testosterone levels are typically low but whether this is a cause-effect relationship remains to be determined. In contrast, in women, elevated serum androgens levels are positively correlated with obesity and metabolic syndrome [7]. The Women's Ischemia Syndrome Evaluation (WISE) study revealed that in postmenopausal women hyperandrogenism is significantly associated with a higher incidence of central adiposity and coronary artery disease than women without hyperandrogenemia [8]. The mechanisms behind the differential action of androgens in males and females remain unclear.

Granulosa cell tumors and thecomas are more often hyperestrogenic, but androgenic cases have been reported [9]. Hyperandrogenism of ovarian origin may be associated with endometrial hyperplasia and/or carcinoma [10], especially in postmenopausal women [11,12] as a result of increased peripheral

Table 1: The endocrine evaluation of the patient.

Serum hormone	Measured value	Normal postmenopausal range	Measurement unit
Testosterone	>16.60	10 - 75	ng/dL
Estradiol	186	<20.00 - 40	pg/mL
FSH	0.3	16.74-114	mIU/mL
LH	0.42	10.87-58.64	mIU/mL
Androstenedion	2.3	0.35 - 2.49	ng/ml
17 hydroxyprogesterone	3.36	0.1 - 3.5	ng/ml
DHEAS	180	7 - 177	µg/dl

estrogen production (aromatization of androgens). Some postmenopausal women with hyperandrogenism caused by a tumor also experience uterine bleeding due to peripheral aromatization of androgens to estrogens [13].

In almost all cases with severe hyperandrogenism, insulin resistance and hyperinsulinemia are present and women are at increased risk for type 2 diabetes and cardiovascular disease. Additional physical findings may include central obesity, skin tags, and acanthosis nigricans.

Most women with ovarian hyperandrogenism have tissue resistance to insulin that is identified by fasting hyperinsulinemia or subnormal insulin-mediated glucose uptake (from euglycemic clamp studies) [14]. The molecular basis for the tissue resistance to insulin in these women is not known. Studies in cultured skin fibroblasts suggest that approximately 50 percent of them have a defect in phosphorylation of the insulin receptor [15]. Peripheral insulin resistance likely plays a more important role in the development of hypertension [16]. Increased cardiovascular risk was implicated in women with hyperandrogenism. Serum testosterone independently increases risk for cardiovascular disease, and correlates even with indices of subclinical atherosclerosis in various populations of postmenopausal women [3].

Conclusion

The presence of severe hyperandrogenism in postmenopausal women is frequently the result of an androgen-secreting tumor and can be associated with important complications.

References

- Barbieri RL, Hornstein MD. Hyperinsulinemia and ovarian hyperandrogenism. Cause and effect. *Endocrinol Metab Clin North Am.* 1988; 17: 685-703.
- Christakou CD, Diamanti-Kandarakis E. Role of androgen excess on metabolic aberrations and cardiovascular risk in women with polycystic ovary syndrome. *Womens Health (Lond).* 2008; 4:583-594.
- Macut D, Antic IB, Bjekic-Macut J. Cardiovascular risk factors and events in women with androgen excess. *J Endocrinol Invest.* 2015; 38: 295-301.
- Secreto G, Sieri S, Agnoli C, Grioni S, Muti P, Zumoff B, et al. A novel approach to breast cancer prevention: reducing excessive ovarian androgen production in elderly women. *Breast Cancer Res Treat.* 2016; 158: 553-561.
- Kelly DM, Jones TH. Testosterone and obesity. *Obes Rev.* 2015; 16: 581-606.
- Stanworth RD, Jones TH. Testosterone in obesity, metabolic syndrome and type 2 diabetes. *Front Horm Res.* 2009; 37: 74-90.
- Valderhaug TG, Hertel JK, Nordstrand N, Dale PO, Hofso D, Hjelmessaeth J.

- The association between hyperandrogenemia and the metabolic syndrome in morbidly obese women. *Diabetol Metab Syndr*. 2015; 7: 46.
8. Shaw LJ, Bairey Merz CN, Azziz R, Stanczyk FZ, Sopko G, Braunstein GD, et al. Postmenopausal women with a history of irregular menses and elevated androgen measurements at high risk for worsening cardiovascular event-free survival: results from the National Institutes of Health--National Heart, Lung, and Blood Institute sponsored Women's Ischemia Syndrome Evaluation. *J Clin Endocrinol Metab*. 2008; 93: 1276-1284.
 9. Outwater EK, Wagner BJ, Mannion C, McLarney JK, Kim B. Sex cord-stromal and steroid cell tumors of the ovary. *Radiographics* 1998; 18:1523-1546.
 10. Potischman N, Hoover RN, Brinton LA, Siiteri P, Dorgan JF, Swanson CA, et al. Case-control study of endogenous steroid hormones and endometrial cancer. *J Natl Cancer Inst*. 1996; 88: 1127-1135.
 11. Barth JH, Jenkins M, Belchetz PE. Ovarian hyperthecosis, diabetes and hirsuties in post-menopausal women. *Clin Endocrinol (Oxf)*. 1997; 46: 123-128.
 12. Krug E, Berga SL. Postmenopausal hyperthecosis: functional dysregulation of androgenesis in climacteric ovary. *Obstet Gynecol*. 2002; 99: 893-897.
 13. Kaltsas GA, Isidori AM, Kola BP, Skelly RH, Chew SL, Jenkins PJ, et al. The value of the low-dose dexamethasone suppression test in the differential diagnosis of hyperandrogenism in women. *J Clin Endocrinol Metab*. 2003; 88: 2634-2643.
 14. Dunaif A, Segal KR, Shelley DR, Green G, Dobrjansky A, Licholai T. Evidence for distinctive and intrinsic defects in insulin action in polycystic ovary syndrome. *Diabetes*. 1992; 41: 1257-1266.
 15. Dunaif A, Xia J, Book CB, Schenker E, Tang Z. Excessive insulin receptor serine phosphorylation in cultured fibroblasts and in skeletal muscle. A potential mechanism for insulin resistance in the polycystic ovary syndrome. *J Clin Invest*. 1995; 96: 801-810.
 16. Han T, Lan L, Qu R, Xu Q, Jiang R, Na L, et al. Temporal Relationship Between Hyperuricemia and Insulin Resistance and Its Impact on Future Risk of Hypertension. *Hypertension*. 2017; 70: 703-711.