

Case Report

A Rare Case of Foramen Magnum Schwannoma Anatomical and Surgical Perspective

Ul Hassan A* and Farooq

Department of Anatomy, Sheri Kashmir Institute of Medical Sciences Medical College, Bemina, India

***Corresponding author:** Ashfaq Ul Hassan, Department of Anatomy, Sheri Kashmir Institute of Medical Sciences Medical College, Bemina, India**Received:** May 05, 2017; **Accepted:** May 26, 2017;**Published:** June 02, 2017**Abstract**

Mostly schwannomas are concentrated in relation to the Acoustic or Cochlear division of the eighth cranial nerve which is the Vestibulocochlear nerve. These lesions are usually benign. We present a rarer location of schwannoma lying in relation to the Foramen Magnum which is not a common location for such masses. The Anatomical relations determine the presentation of the tumors and in this case the rare presentation was to the surprise of ours.

Keywords: Schwannoma; Vestibulocochlear; Benign; Merlin; Trigeminal; Nerve; Compression; Brain stem

Case Presentation

This 52 year old male initially presented to a private clinic with headache easy fatigability. Preliminary investigations revealed haemoglobin: 11.5g/dL, white blood cell count $11 \times 10^9/L$ (4-11), neutrophils: $6 \times 10^9/L$ (1.5-7), lymphocytes, liver function tests within normal values, kidney function tests within normal values. With more progression of headaches especially morning headaches, subsequent brain scan showed a foramen magnum mass which was pathologically proven to be a schwannoma.

Introduction

In most cases the schwannomas are referred to as Acoustic Neuromas and lie in relation to the (VIIIth) Vestibulocochlear nerve or the eighth cranial nerve [1] and are often called as vestibular schwannomas because they are tumors that arise from the myelin sheath that surrounds the vestibular nerve. These tumors are mostly benign. Pathologically they are benign and slow growing but can cause symptoms through mass effect and pressure on local structures, eventually becoming life-threatening. They are common at the anatomical location of cerebellopontine angle [2]. Merlin plays an important role in controlling cell shape, cell movement, and communication between cells in addition to being a tumor suppressor protein.

Usually these tumors are non cystic but cystic schwannomas are also reported [3]. They may be extracranial in course as well [4]. Abnormal site can be Parapharyngeal space as well as peripheral nerves like the median nerve [5,6]. In normal instances where the growth of tumor is large, it may extend into the posterior cranial fossa and cause compression at the cerebellopontine angle and it may also compress the 5th and the 7th cranial nerves. In some cases it may compress the pons and lateral medulla, causing obstruction of the cerebrospinal fluid and increased intracranial pressure. The increased pressure in the posterior Cranial Fossa and the disfigurement of the foramina of Luschka and of Magendie predispose to obstruction of cerebrospinal fluid (CSF) and the development of hydrocephalus. In this case the schwannoma was present at the level of Foramen Magnum. The spinal Cord is continuous below with the spinal cord at the foramen magnum and the central canal of the spinal cord extends

upwards in the lower half of the medulla. Thus the site of foramen magnum is an important landmark.

Anatomical and Surgical Considerations

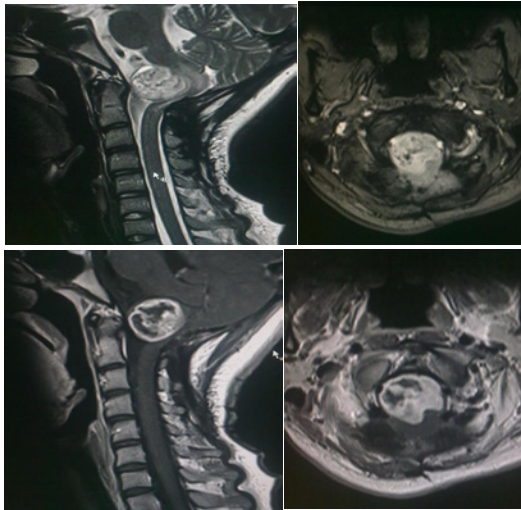
Usually in normal circumstances, patients with such tumors present with ipsilateral sensorineural hearing deafness, vertigo with associated nausea and vomiting or tinnitus. Headache may also be present. In cases of rare involvement of the IXth and Xth cranial nerves there is dysphagia and hoarseness due to palatal, pharyngeal and laryngeal paralysis. Other cranial nerves XIth, XIIth, IIIrd, IVth and VIth are affected when tumor is very large. In case of brainstem involvement, there is ataxia, weakness and numbness of the arms and legs with exaggerated tendon reflexes. In case of cerebellar involvement there may be ataxia with positive finger-nose test, knee-heel test, dysdiadochokinesia and nystagmus.

In case of rapid growth especially with Large tumors that compress the adjacent brainstem may affect other local cranial nerves. Involvement of the nearby facial nerve (CN VII) may lead to ipsilateral facial weakness, involvement of the trigeminal nerve (CN V) may lead to loss of taste and loss of sensation in the involved side's face and mouth. The glossopharyngeal and vagus nerves are uncommonly involved, but their involvement may lead to altered gag or swallowing reflexes.

Even larger tumors may lead to increased intracranial pressure, with its associated symptoms such as headache, vomiting, and altered consciousness.

Pathologically these tumors are the most common and need to be differentiated from Meningiomas [7,8]. Intracranial schwannomas are Benign, encapsulated and slow growing and are derived from Schwann cells. Histologically schwannomas consists of cellular areas (Antoni A) and loose edematous areas (Antoni B). Verocay bodies (foci of palisaded nuclei) may be found in the more cellular areas. The most useful (i.e., sensitive and specific) test to identify acoustic neuromas is a Gadolinium enhanced MRI of the head.

When small, they may occasionally be excised with preservation of hearing. Large tumors can also be safely removed in most cases but cranial nerve palsies, especially facial paralysis and deafness are



Figures 1: Showing Brain Stem Tumor (Schwanomma).

common sequelae. In case of a typical Location or Extremely large tumors they may compress the brainstem, threatening other cranial nerves and preventing the normal flow of cerebrospinal fluid within the ventricular system of the brain leading to the development of hydrocephalus which may be life-threatening [9]. In such cases of treatment of the hydrocephalus and decompression of the brainstem is important part of management. In normal course otherwise the tumors are periodically monitored by regular MRI or CT Scans.

Conclusion

Schwannomas may not normally present as life threatening tumors but rare cases can present at ectopic locations and cause life threatening symptoms. Such Tumors in the region of Foramen Magnum are rare and can be potentially dangerous.

References

1. Mulkens TH, Parizel PM, Martin JJ, et al. Acoustic schwannoma: MR findings in 84 tumors. *AJR Am J Roentgenol.* 1993; 160: 395-398.
2. Mafee MF, Lachenauer CS, Kumar A, et al. CT and MR imaging of intralabyrinthine schwannoma: report of two cases and review of the literature. *Radiology.* 1990; 174: 395-400.
3. Tali ET, Yuh WT, Nguyen HD, et al. Cystic acoustic schwannomas: MR characteristics. *AJNR Am J Neuroradiol.* 1993; 14: 1241-1247.
4. Biswas D, Marnane CN, Mal R, Baldwin D. Extracranial head and neck schwannomas—a 10-year review. *Auris Nasus Larynx.* 2007; 34: 353-359.
5. Miller FR, Wanamaker JR, Lavertu P, Wood BG. Magnetic resonance imaging and the management of parapharyngeal space tumors. *Head Neck.* 1996; 18: 67-77.
6. Ziadi A, Saliba I. Malignant peripheral nerve sheath tumour of intracranial nerves: a case series review. *Auris Nasus Larynx.* 2010; 37: 539-545.
7. Voss NF, Vrionis FD, Heilman CB, Robertson JH. Meningiomas of the cerebellopontine angle. *Surg Neurol.* 2000; 53: 439-446.
8. Glasscock ME, Minor LB, McMenemy SO. In: Jackler R, Brackmann D, editor. *Neurotology.* St. Louis: Mosby; 1994. Meningiomas of the cerebellopontine angle. pp. 795-823.
9. Mallucci CL, Ward V, Carney AS, O'Donoghue GM, Robertson I. Clinical features and outcomes in patients with non-acoustic cerebellopontine angle tumours. *J Neurol Neurosurg Psychiatry.* 1999; 66: 768-771.