

Case Report

Recurrent Shoulder Dislocation in the Elderly - What are the Potential Complications?

Chua Si Yong Ivan^{1*} and Fatimah Lateef²¹Department of Emergency Medicine, Singapore General Hospital, Singapore²Department of Emergency Medicine and Trauma, National University of Singapore, Yong Loo Lin School of Medicine, Singapore***Corresponding author:** Chua Si Yong Ivan, Department of Emergency Medicine, Singapore General Hospital, Singapore**Received:** November 13, 2015; **Accepted:** November 24, 2015; **Published:** November 27, 2015**Abstract**

Shoulder dislocation is a common medical condition seen in the Accident and Emergency (A&E) Department. It is usually a result of trauma or associated with ligamentous laxity. Its occurrence in the elderly population is less common and as the elderly usually has multiple medical co-morbidities including osteoporosis, treatment with manipulation and reduction of a shoulder dislocation in the elderly has to be attempted with extreme care due to associated complications. We report a case of an elderly Chinese lady with a history of recurrent right shoulder dislocation presenting to the local A&E department with an a traumatic right shoulder dislocation that underwent a closed reduction of the dislocated right shoulder in the A&E but unfortunately had a complication - fracture of the proximal neck of humerus. This article will discuss the complications associated with recurrent shoulder dislocation in the elderly and the appropriate management of this orthopaedic condition in the geriatric population.

Keywords: Shoulder dislocation; Elderly; Geriatrics; Osteoporosis

Introduction

Shoulder dislocation is the most common large joint dislocation seen in the Accident and Emergency (A&E) Department with an incidence of 8.2-24 [1,2] per 100,000 person-years, of which 96% are anterior shoulder dislocations [3]. It is usually a result of trauma - typically a fall on an outstretched hand or associated with a history of ligamentous laxity. Its occurrence in the elderly population is less common and as the elderly usually has multiple medical co-morbidities including osteoporosis, treatment with manipulation and reduction of a shoulder dislocation in the elderly has to be attempted with extreme care due to associated complications.

Case Report

An 88-year-old Chinese lady with a history of recurrent right shoulder dislocation presented with sudden onset of pain and inability to elevate her right shoulder. There was no prior trauma and previous episodes of recurrent right shoulder dislocations were reduced spontaneously. Clinical examination revealed squaring of the right shoulder with the humeral head felt anterior to the glenoid labrum. There was no regimental badge numbness and neurovascular status of the right upper limb was intact. An X-ray of the shoulder was performed which confirmed a right anterior shoulder dislocation with the presence of a diffusely osteopaenic humerus. Manipulation and Reduction (M&R) of the right shoulder was performed using the traction-counter traction technique while the patient was placed under conscious sedation using IV Midazolam and IV Fentanyl. A post-reduction X-ray was performed which showed subluxation of the humeral head and a second attempt at M&R was made, this time using the Spaso technique. Unfortunately, a crack sound was heard during the M&R and a new fracture of the surgical neck of the humerus was noted on a repeat X-ray of the shoulder. The patient was assessed by an orthopaedic surgeon who recommended conservative

management in view of her multiple medical co-morbidities (Figures 1 and 2).

Discussion

There is a bimodal age distribution for anterior shoulder dislocation - the first group being young adult men with high-energy injuries to the shoulder and the second group comprising of older patients with lower impact injuries [4]. 20-44% [5-7] of shoulder dislocations occurs in patients aged more than 60 years of age. However, whereas most young and middle-aged patients with shoulder dislocations are male, most of the elderly patients are female, likely a result of longer life expectancy. In addition, many of these injuries are not isolated injuries and there are significant problems that arise more frequently in the older population, including rotator cuff injury, brachial plexus injury and axillary artery injury [8].

The prevalence of recurrent shoulder dislocation is around 50-75% for adolescents and young adults (up to 25 years of age) [9] whereas various studies on patients over 60 years old have quoted prevalence up to 22% in elderly patients [5]. Nevertheless, the recurrence in older patients may reflect a more significant injury with potential need for imaging and reconstructive surgery. Kinnett et al. identified 3 risk factors for recurrence of dislocations in the elderly - increased ligamentous laxity, increased activity level and high-energy dislocation [8].

Up to 83% [10] of elderly patients with a shoulder dislocation have a tear of the rotator cuff, and it is important to evaluate symptomatic elderly patients with imaging 2-4 weeks after reduction as earlier rotator cuff repairs may yield better results [11].

The prevalence of nerve injury after anterior shoulder dislocation increases with age. In a study by Gumina et al., 9.3% of elderly patients had an injury of the axillary nerve compared to 4.6% in patients less




Figure 1: (A): (left) is an AP right shoulder X-ray taken 3 years ago in 2009. (B): (middle) was taken during the current admission prior to M&R. (C): (right) shows a new surgical neck of humerus fracture after M&R.

than 60 years of age [5]. Thankfully, most of the nerve damage was mainly neurapraxia which resolved spontaneously within a few months.

Extreme care is also necessary when dealing with chronically dislocated shoulders in the elderly (defined as more than 3 weeks) due to risk of axillary artery rupture [4]. Closed reduction should be attempted under general anesthesia in the operating theatre with a view to proceed with open reduction if gentle, closed reduction techniques have failed.

Various techniques have been described in the literature for manipulation and reduction of anterior shoulder dislocation and their efficacy is similar between 70-90% reductions on first attempt. Hippocratic's and Kocher's methods have been criticized for their significant association with complications such as neurovascular injury in the former and spiral fractures of the humerus in the latter. In addition, the risk of fracture in attempting another reduction is much higher [12].

Conclusion

In summary, recurrent shoulder dislocations are not uncommon in the elderly, and manipulation and reduction in the A&E department should proceed with care due to the increased risk of complications, with a low threshold for conscious reduction under general anesthesia if the initial attempt is unsuccessful.

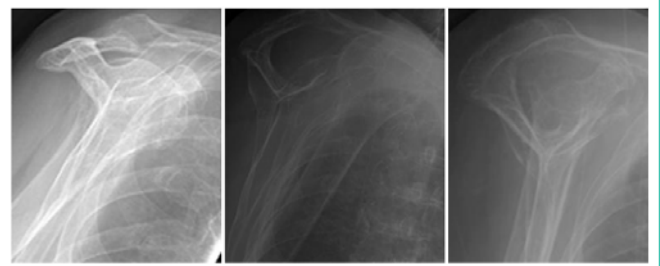


Figure 2: The X-rays above correspond to the lateral views of Figures 1A-1C.

References

1. Krøner K, Lind T, Jensen J. The epidemiology of shoulder dislocations. *Arch Orthop Trauma Surg.* 1989; 108: 288-290.
2. Zacchilli MA, Owens BD. Epidemiology of shoulder dislocations presenting to emergency departments in the United States. *J Bone Joint Surg Am.* 2010; 92: 542-549.
3. Goss TP. Anterior glenohumeral instability. *Orthopedics.* 1988; 11: 87-95.
4. Stayner LR, Cummings J, Andersen J, Jobe CM. Shoulder dislocations in patients older than 40 years of age. *Orthop Clin North Am.* 2000; 31: 231-239.
5. Gumina S, Postacchini F. Anterior dislocation of the shoulder in elderly patients. *J Bone Joint Surg Br.* 1997; 79: 540-543.
6. Rowe CR. Prognosis in dislocations of the shoulder. *J Bone Joint Surg Am.* 1956; 38: 957-977.
7. Kazár B, Relovszky E. Prognosis of primary dislocation of the shoulder. *Acta Orthop Scand.* 1969; 40: 216-224.
8. Kinnett JG, Warren RF, Jacobs B. Recurrent dislocation of the shoulder after age fifty. *Clin Orthop Relat Res.* 1980; 164-168.
9. Aronen JG, Regan K. Decreasing the incidence of recurrence of first time anterior shoulder dislocations with rehabilitation. *Am J Sports Med.* 1984; 12: 283-291.
10. Hawkins RJ, Bell RH, Hawkins RH, Koppert GJ. Anterior dislocation of the shoulder in the older patient. *Clin Orthop Relat Res.* 1986; 192-195.
11. Pevny T, Hunter RE, Freeman JR. Primary traumatic anterior shoulder dislocation in patients 40 years of age and older. *Arthroscopy.* 1998; 14: 289-294.
12. Butler M, Rossiter N. A national audit to assess preferential reduction technique of orthopedic surgeons and accident and emergency (A&E) doctors in anterior dislocation of the shoulder.