

## Case Report

# Two Large Symptomatic Thyroid Cysts in Multinodular Goiters Treated with Ultrasound-Guided Ethanol Sclerotherapy

Milan Halenka\*, David Karasek and Zdenek Frysak

Department of Internal Medicine, Palacky University, Czech Republic

\*Corresponding author: Milan Halenka, 3rd Department of Internal Medicine, Faculty of Medicine and Dentistry, Palacky University, 775 20 Olomouc, Czech Republic, Tel: 420 585 853 356; Fax: 420 585 852 526; Email: milan.halenka@fnol.cz

Received: August 04, 2014; Accepted: August 20, 2014; Published: August 25, 2014

## Abstract

Ultrasound-guided ethanol sclerotherapy is used as an alternative to surgery in the treatment of thyroid cysts. The method is effective, repeatable, and cheap and can be performed in an outpatient setting. The risks are related to ethanol leaking into the surrounding tissues but serious complications are only seen in a small proportion of procedures. The approach is successfully used to treat small- and medium-sized cysts of less than 50 ml of volume. It may also be attempted in large, mostly complex cysts causing significant mechanical problems. These are two reports documenting cases of successfully treated large symptomatic cysts (80 and 170 ml) in multinodular goiters in elderly patients with co morbidities who either refused a surgical approach or in whom surgery was ruled out.

**Keywords:** Ultrasound-guided ethanol sclerotherapy; Large symptomatic cysts thyroid cysts

## Introduction

A multinodular goiter is a common condition, especially in elderly patients. The goiter is frequently visible, causing mechanical problems. The prevalence rates of thyroid nodules detected by palpation and by Ultrasound (U/S) are 4-7% and 19-67%, respectively [1]. Complex nodules develop due to hemorrhage or degenerative changes and are present in 18%-35% of surgical specimens [2]. In U/S examinations, complex nodules account for up to 50% of all palpable and non-palpable nodules [3].

Cysts with the fluid component making up more than 60% of their volume are called complex [4,5] in some individuals, large complex cysts with a volume of more than 50 ml may appear, causing significant mechanical and cosmetic difficulties that have to be solved. Naturally, the approach of choice is surgery. In most cases, simple evacuation fails to be successful, even in small cysts. The recurrence rates are 58%-80%, depending on the size, content and number of previous aspirations [6,7]. Large complex cysts recur quite commonly [8]. In patients unsuitable for surgery, an alternative approach is ethanol sclerotherapy which may produce a significant reduction in cyst volume of more than 50% or, sometimes, even disappearance of the fluid component. To assess the success of treatment, a Volume Reduction Rate (VRR) is calculated using the following formula:  $\text{initial cyst volume} - \text{final cyst volume} / \text{initial cyst volume} \times 100 = \text{result as a percentage}$ . The mechanism of action of ethanol is related to coagulative necrosis, reactive fibrosis and small vessel thrombosis [7]. These large cysts already require repeated administration of ethanol, meaning a higher risk of its leakage into the surrounding tissue and more severe complications. Yet the method has already been used successfully [8-10].

## Methods

Cytological examination showed that the aspirate was benign in

all the cases. The patients gave informed consent to sclerotherapy. The examination and U/S ethanol sclerotherapy was performed using the iU 22, Philips, 10-MHz linear probe. During the procedure, the patient was in the supine position with the head slightly tilted back. A 20-gauge needle was used for evacuation of the cyst and subsequent sclerotherapy. The approach was non-aspiration of the instilled 96% ethanol [5,6,11]. First, nearly all cyst content was evacuated, with a small amount of the colloid being left for visualization of the needle tip. While the needle was kept in the cystic cavity, the evacuation syringe was replaced with a syringe with 96% ethanol which was slowly instilled into the collapsed cavity. U/S check-ups after latest sclerotherapy were planned 3, 6, and 12 months later. Laboratory findings (TSH, normal range 0, 35-4, 94 mIU/l) were checked before and after sclerotherapy.

## Case report 1

A 79-year-old male with a 15-year history of a multinodular goiter developed a mass in the right thyroid lobe causing mechanical problems as he could not button his shirt (Figure 1). The underlying cause was a large complex cyst repeatedly (3 times) biopsied by a local radiologist, with benign cytology results. A U/S scan performed in our department revealed a large multinodular goiter with a volume of 130 ml and a large 80-ml complex cyst in the right lobe, with a predominant cystic component, smooth inner wall and no septa (Figure 2a). Given the patient's co morbidities, surgery was ruled out and ethanol sclerotherapy was proposed. Initially, 70 ml of brown fluid were evacuated. Cytological examination showed only degenerative but not benign changes. This was followed by sclerotization with 96% ethanol. Every three weeks, the cyst was evacuated and 5 ml of 96% ethanol were instilled into it. The procedure was carried out five times. Gradually, the cyst volume reduced to 35 ml, 22 ml, 20 ml, 16 ml and 14 ml. One month after completion of therapy, the solid residue of the cyst had a volume of 9 ml (Figure 2b). The complex cyst regressed

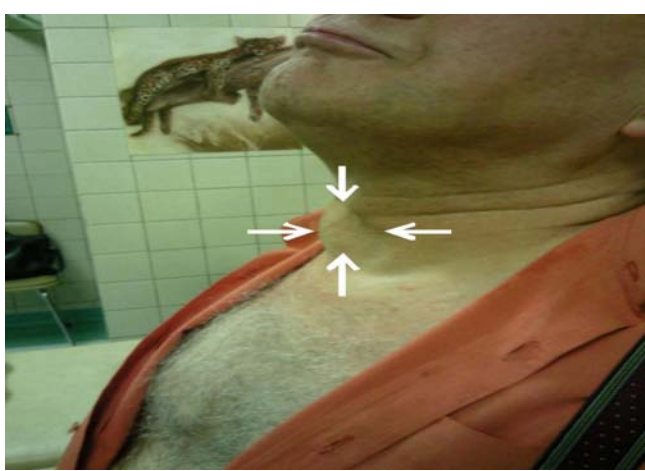

Figure 1: Case 1, input clinical findings.

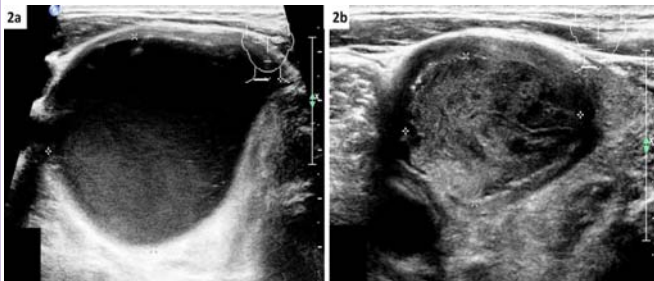


Figure 2A: A complex, non-septated 80-ml cyst prior to sclerotherapy .  
 Figure 2B: A complex, non-septated cyst 1 month after completion of sclerotherapy showing a solid residue, of volume 9 ml (a transverse US view).

from the initial volume of 80 ml to the final volume of 9 ml that is a VRR of 89%. A total of 25 ml of 96% ethanol was administered, which was equal to 31% of the initial cyst volume. The procedures were tolerated well by the patient who only reported mild local pain on two occasions after ethanol instillation that subsided within 24 or 48 hours. Patient was before and after sclerotherapy euthyroid, TSH 2.14 resp. 2.23 mIU/l.

**Case report 2**

An 80-year-old female presented with a 5-year history of a large palpable mass in the right neck, extending from the jugulum to the mandible and causing mechanical problems when rotating or inclining her head (Figure 3). The underlying cause was a large complex septated cyst. The patient declined surgery and was treated by a local endocrinologist with repeated (a total of 5) aspirations and evacuation of approximately 100 ml, with benign cytology results. She was referred to our center. There, initial U/S examination found a multinodular goiter and normal-sized right lobe (9 ml volume) with complex nodules smaller than 5 mm. The entire left lobe was occupied by a complex cyst, much larger than the probe sector image. Its size was estimated to be approximately 14x6x4 cm and volume about 170 ml. The cyst had a rough wall, numerous thick septa and fluid anechoic contents (Figure 4a). Since the patient continued to refuse surgery and with respect to her co morbidities, ethanol sclerotherapy was suggested to treat the condition. The first evacuation with several punctures yielded 150 ml of light yellow, later blood-tinged, fluid. Cytology results were benign. Subsequent sclerotherapy with 96%

ethanol was performed as follows: every 3 weeks, evacuation of the cyst, in this case a particularly large septated cavity, and instillation of 10 ml of 96% ethanol (a total of 9 procedures). Gradually, the following amounts were evacuated: 90, 90, 60, 50, 35, 35, 30 and 20 ml of fluid; some cavities were evacuated and sclerotized repeatedly. One month after completion of therapy, the volume of the complex cyst was 42 ml. Several small cystic septated cavities remained, together with a dominant solid portion of the residual complex nodule (Figure 4b). The complex cyst regressed from the initial volume of about 170 ml to the final volume of 42 ml, a VVR of 75%. A total of 60 ml of 96% ethanol was administered, which was equal to 35% of the initial cyst volume. The patient’s symptoms disappeared. Despite the higher number of punctures, the procedures were well tolerated by the patient. The adverse effects included mild transient pains at the puncture site that subsided within 24 hours (4 occasions) and short-term attacks of vertigo due to her head being tilted back during the procedure and sitting up abruptly after the intervention, related to cerebral atherosclerosis (3 occasions). Patient was before and after sclerotherapy euthyroid, TSH 1.96 resp. 2.08 mIU/l.

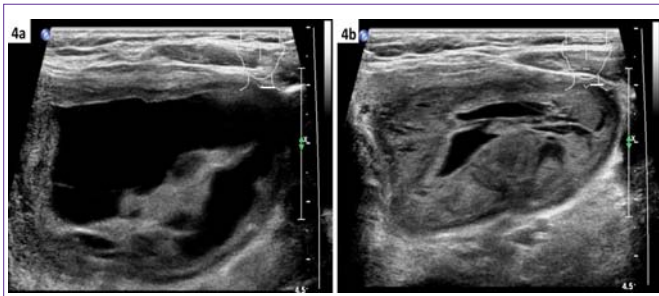
**Discussion**

Sclerotherapy as a method for the treatment of thyroid cysts was first reported by Rozman in 1989. Since the early 1990s, it has been used as an alternative to surgery. Although various substances were used as sclerosing agents (tetracycline, OK-432), ethanol has become the most common one. Apart from cysts, sclerotherapy is used to treat solid thyroid nodules, in particular autonomous toxic adenomas, also with a certain success although the volume of solid masses is reduced to a smaller extent and the risk of adverse effects is higher. Therefore, the basic treatment approaches are surgery or radioiodine therapy [12].

The largest and most successful studies were those with patients treated for recurrent thyroid cysts. The reported studies mostly comprised tens or even hundreds of patients, such as those by Del Prate et al. (98 patients), Kim YJ et al. (127 patients) or Lee and Ahn (432 patients) [10,12,13]. The approach was found to be highly effective. In the vast majority of cases, the cysts volume was reduced (to less than 50% of the initial volume) or the fluid component even disappeared completely, both of which are considered a therapeutic success [7]. The outcome is affected by the initial cyst volume and character of the fluid component [14]. The method was compared

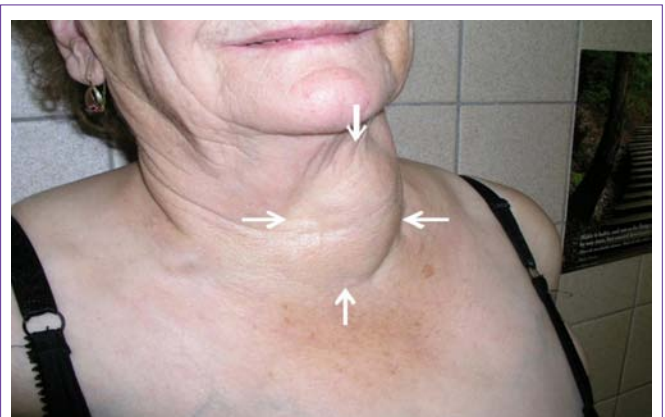

Figure 3: Case 2, input clinical findings.



**Figure 4A:** A complex septated 170-ml cyst prior to sclerotherapy; a longitudinal US view of a part of the cyst.

**Figure 4B:** A complex, septated cyst 1 month after completion of sclerotherapy showing a solid residue with small cystic cavities, of volume 42 ml (a transverse US view).

with simple evacuation by Valcavi and Frasoldati in a study of 281 patients, of whom 138 were treated by simple evacuation and 143 by ethanol sclerotherapy. After one year, the VRR was only 7% in evacuation but as much as 86% in sclerotherapy [15]. The results of ethanol sclerotherapy were compared with evacuation and instillation of saline as a placebo in studies by Atonally et al. in 1994, with a therapeutic effect of 77% and 36% of patients, respectively, and by Bennedbaek and Hegedüs in 2003, with a therapeutic effect of 82% and 48% of patients, respectively [7,16].

The method is used in two basic ways, with the instilled ethanol being either applied or left inside or removed shortly (2-10 minutes) after application. The former is more frequent since there is no need for another puncture, the procedure is shorter and thus less uncomfortable for the patient [5,6,11]. The main reason for the latter approach is lowering the potential risk for ethanol leaking into the surrounding tissue [7,17]. As far the effectiveness is concerned, both approaches are fully comparable, as shown by Kim DW et al [18].

Another difference is the amount of ethanol applied, ranging from 40% to 100% of the initial cyst volume. Although most authors recommend that a single dose of 10 ml of ethanol should not be exceeded, Kim DW et al. applied up to 20 ml and, in one case of a large 135-ml cyst, even as much as 30 ml of ethanol [18].

In most studies, the initial cyst volume was 50-60 ml. The examples may be those by Kim JH et al. (1.2-48.6 ml), Cho et al. (3.5-42 ml), Sung et al. (4.5-57 ml), Kim DW et al. (2-50 ml; one patient 135 ml) or Jayesh et al. (3-25 ml) [4,5,17-19].

The approach proved effective in patients with large cysts as well. Zingrillo reported successful treatment in 93% of 43 patients with large symptomatic cysts with a mean volume of 38 ml [8]. Over a period of 10 years, Del Prete et al. treated 98 patients of whom one-third had cysts with an initial volume of more than 40 ml. recurrent cysts were reported in only six of them [10].

Adverse effects are related to ethanol leaking into the surrounding tissues. Following the procedure, most patients report mild and transient pain at the site of injection, radiating to the neck, chin and ears, due to a small leak of ethanol into the subcutaneous space. The incidence varies, with 2.5% to 30% or, in large cysts, to as much as 70% of patients being affected [10,13,18]. More severe leaks may lead to par glandular fibrosis complicating potential surgery if treatment fails [7]. Rarely, vocal cord paresis and dysphonia or transient

thyrotoxicosis may develop [16]. In the largest study of 432 patients with complex cysts, Lee and Ahn found transient localized pain in 32 patients (7.9%) and temporary vocal cord paralysis in only three (0.7%). However, the rate of complications is lower than in the treatment of solid autonomous nodules [12].

When selecting cystic nodes suitable for sclerotherapy, it is important to realize that the complex nodes with a solid share of over 50% of the volume as microcalcifications have potentially greater risk of malignancy and it is better to remove them surgically [20].

In both reported patients with large complex cysts, ethanol sclerotherapy was successful, solving their mechanical problems. The cyst volume regressed by more than 50%, with a VRR of 89% and 75% for the non-septated and septated cysts, respectively. The total amounts of 96% ethanol applied were equal to 31% and 35% of the initial volume of the non-septated and septated cysts. In the non-septated cyst, the fluid component disappeared completely and only the solid portion of the complex cyst remained. The septated cyst volume was substantially reduced, with several small cavities remaining into which ethanol could not penetrate. However, the therapeutic effect was sufficient and no more applications were needed. A favorable course of the treatment was contributed to by the fact that the cyst contents were not excessively viscous.

Despite numerous applications in both patients, the adverse effects were only transient localized pain which did not prevent treatment from continuing and attacks of vertigo, associated rather with the head being tilted back during surgery and cerebral atherosclerosis. However, both patients were positively motivated by the fact that palpable masses in their necks were becoming visibly smaller. The higher numbers of procedures gave rise to concerns, especially about the development of vocal cord paresis on the side of the procedure or skin necrosis, but these did not materialize. Naturally, the numbers of applications could have been lowered and the amount of ethanol per application could have been increased. But given the potential risks and concerns about the patients' response to treatment, the amounts of 5 ml and 10 ml per application were used.

## Conclusion

The two reports document cases of large dominant complex cysts in multinodular goiters that were successfully treated with repeated instillation of ethanol.

The important fact is that for successful sclerotherapy of such large cysts, relatively small amounts of ethanol were sufficient, equal to one-third of the initial cyst volume. Despite a higher number of applications, there were no severe complications and the procedures resulted in the desired therapeutic effects. Thyroid function was not impaired.

## References

1. Welker MJ, Orlov D. Thyroid nodules. *Am Fam Physician*. 2003; 67: 559-566.
2. McHenry CR, Slusarczyk SJ, Khiyami A. Recommendations for management of cystic thyroid disease. *Surgery*. 1999; 126: 1167-1171.
3. Alexander EK, Heering JP, Benson CB, Frates MC, Doubilet PM, Cibas ES, et al. Assessment of nondiagnostic ultrasound-guided fine needle aspirations of thyroid nodules. *J Clin Endocrinol Metab*. 2002; 87: 4924-4927.
4. Kim JH, Lee HK, Lee JH, Ahn IM, Choi CG. Efficacy of sonographically



- guided percutaneous ethanol injection for treatment of thyroid cysts versus solid thyroid nodules. *AJR Am J Roentgenol.* 2003; 180: 1723-1726.
5. Cho YS, Lee HK, Ahn IM, Lim SM, Kim DH, Choi CG, et al. Sonographically guided ethanol sclerotherapy for benign thyroid cysts: results in 22 patients. *AJR Am J Roentgenol.* 2000; 174: 213-216.
  6. Yasuda K, Ozaki O, Sugino K, Yamashita T, Toshima K, Ito K, et al. Treatment of cystic lesions of the thyroid by ethanol instillation. *World J Surg.* 1992; 16: 958-961.
  7. Bennedbaek FN, Hegedüs L. Treatment of recurrent thyroid cysts with ethanol: a randomized double-blind controlled trial. *J Clin Endocrinol Metab.* 2003; 88: 5773-5777.
  8. Zingrillo M, Torlontano M, Ghiggi MR, D'Aloiso L, Nirchio V, Bisceglia M, et al. Percutaneous ethanol injection of large thyroid cystic nodules. *Thyroid.* 1996; 6: 403-408.
  9. Zingrillo M, Torlontano M, Chiarella R, Ghiggi MR, Nirchio V, Bisceglia M, et al. Percutaneous ethanol injection may be a definitive treatment for symptomatic thyroid cystic nodules not treatable by surgery: five-year follow-up study. *Thyroid.* 1999; 9: 763-767.
  10. Del Prete S, Caraglia M, Russo D, Vitale G, Giuberti G, Marra M, et al. Percutaneous ethanol injection efficacy in the treatment of large symptomatic thyroid cystic nodules: ten-year follow-up of a large series. *Thyroid.* 2002; 12: 815-821.
  11. Verde G, Papini E, Pacella CM, Gallotti C, Delpiano S, Strada S, et al. Ultrasound guided percutaneous ethanol injection in the treatment of cystic thyroid nodules. *Clin Endocrinol (Oxf).* 1994; 41: 719-724.
  12. Lee SJ, Ahn IM. Effectiveness of percutaneous ethanol injection therapy in benign nodular and cystic thyroid diseases: long-term follow-up experience. *Endocr J.* 2005; 52: 455-462.
  13. Kim YJ, Baek JH, Ha EJ, Lim HK, Lee JH, Sung JY, et al. Cystic versus predominantly cystic thyroid nodules: efficacy of ethanol ablation and analysis of related factors. *Eur Radiol.* 2012; 22: 1573-1578.
  14. Zieleńnik W, Kawczyk-Krupka A, Barlik MP, Cebula W, Sieroń A. Modified percutaneous ethanol injection in the treatment of viscous cystic thyroid nodules. *Thyroid.* 2005; 15: 683-686.
  15. Valcavi R, Frasoldati A. Ultrasound-guided percutaneous ethanol injection therapy in thyroid cystic nodules. *Endocr Pract.* 2004; 10: 269-275.
  16. Antonelli A, Campatelli A, Di Vito A, Alberti B, Baldi V, Salvioni G, et al. Comparison between ethanol sclerotherapy and emptying with injection of saline in treatment of thyroid cysts. *Clin Investig.* 1994; 72: 971-974.
  17. Sung JY, Baek JH, Kim YS, Jeong HJ, Kwak MS, Lee D, et al. One-step ethanol ablation of viscous cystic thyroid nodules. *AJR Am J Roentgenol.* 2008; 191: 1730-1733.
  18. Kim DW, Rho MH, Kim HJ, Kwon JS, Sung YS, Lee SW. Percutaneous ethanol injection for benign cystic thyroid nodules: is aspiration of ethanol-mixed fluid advantageous? *AJNR Am J Neuroradiol.* 2005; 26: 2122-2127.
  19. Jayesh SR, Mehta P, Cherian MP. *Indian J Radiol Imaging.* 2009; 19: 255.
  20. Lee MJ, Kim EK, Kwak JY, Kim MJ. Partially cystic thyroid nodules on ultrasound: probability of malignancy and sonographic differentiation. *Thyroid.* 2009; 19: 341-346.