

Clinical Image

Loculated Pleural Effusion Mimicking as Mass Lesion

Agarwal A, Saigal S*, Choudhary NS and Sooin AS
Medanta Institute of Liver Transplantation and
Regenerative Medicine, Medanta The Medicity, India

***Corresponding author:** Sanjiv Saigal, Director-
Transplant Hepatology, Medanta Institute of Liver
Transplantation and Regenerative Medicine, Medanta
The Medicity, India

Received: October 27, 2016; **Accepted:** December 27,
2016; **Published:** December 28, 2016

Clinical Image

A 56 years male, known case of Living Donor Liver Transplantation in July, 2014 for Hepatitis C Virus related cirrhosis and hepatocellular carcinoma underwent Endoscopic Retrograde Cholangio Pancreatography (ERCP) and biliary stenting for anastomotic stricture in September 2016. He complained of shortness of breath with right sided chest pain after 5 days of procedure. Cardiac evaluation was normal. Chest X-ray showed two rounded opacities in right hemithorax suggestive of mass lesion (Figure 1A). As patient was previously transplanted for Hepatocellular Carcinoma, a high suspicion of pulmonary metastatic disease was considered and further imaging was done. CECT Thorax was done which revealed loculated hypodense fluid collection involving right middle and lower lung lobes (Figure 1B and C). Two pigtail catheters were placed for drainage and subsequently patient showed clinical and radiological improvement with expansion of lung (Figure 1D). The pleural fluid was exudative in character with culture being positive for Klebsiella pneumonia and patient responded well to intravenous antibiotics; pleural fluid bilirubin was normal, thus ruling out communication between biliary system and pleural cavity. Reports of Hepatocellular Carcinoma mimicking as abscess have been noted in some studies [1,2]. As Sir William Osler aptly puts it [3], “to study the phenomenon of disease without books is to sail an uncharted sea, while to study books without patients is not to go to sea at all”. It is therefore

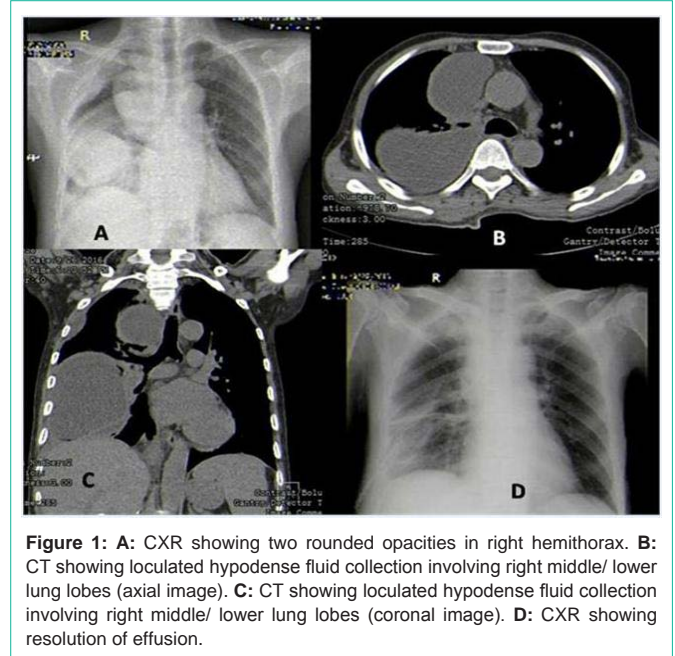


Figure 1: **A:** CXR showing two rounded opacities in right hemithorax. **B:** CT showing loculated hypodense fluid collection involving right middle/ lower lung lobes (axial image). **C:** CT showing loculated hypodense fluid collection involving right middle/ lower lung lobes (coronal image). **D:** CXR showing resolution of effusion.

important then for all involved in the care of patients to be in that boat at sea together.

References

1. Falidas E, Pazidis A, Anyfantakis G, Vlachos K, Goudeli C, Villias C. Multicystic Hepatocarcinoma Mimicking Liver Abscess. Case Reports in Surgery. 2013.
2. Chung YF, Thng CH, Lui HF, Mancor K, Chow PKH, Tan YM, et al. Clinical mimicry of hepatocellular carcinoma: imaging-pathological correlation. Singapore Med J. 2005; 46: 31
3. Osler W. Aequanimitas. 3rd ed. London: McGraw-Hill Professional. 1932.