

Research Article

N-Acetylcysteine, Anti-CD4/CD8 Antibodies, and Physical Exercise Reduces Histopathological Damage in Salivary Glands of Spontaneously Diabetic Mice

Ror FN^{1,2*}, Col LO², Moura EG², Jaciara MA² and Caldeira EJ²

¹Faculty of Medicine, Three Frontier International University, UNINTER-PJC, Paraguay, Brazil

²Tissue Morphology Laboratory, Faculty of Medicine of Jundiaí, FMJ, São Paulo, Brazil

*Corresponding author: Ror FN, Faculty of Medicine, Three Frontier International University, UNINTER-PJC, Paraguay, Tissue Morphology Laboratory, Faculty of Medicine of Jundiaí, FMJ, São Paulo, Brazil

Received: February 03, 2018; Accepted: March 16, 2018; Published: March 23, 2018

Abstract

The objective of this study was to evaluate the effect of NAC, anti-CD4/CD8, on salivary glands of spontaneously diabetic mice, mainly observing the action of this therapy on the recovery of glandular homeostasis. Mice were divided into groups with 5 animals each: Group I (Balb/C control); Group II (diabetic NODs); Group III (NOD diabetics + NAC + anti-CD4 and CD8). NAC was administered intraperitoneally for 21 days at the dosage of 50mg/kg. Anti-CD4/CD8 antibodies at the dose of 25µg/ml were administered intravenously on days: 0, 7, 14 and 21. The hyperglycemic condition promoted alterations in the general homeostasis of the animals and also in the salivary tissues, characterized by cellular pleomorphism and the presence of inflammatory processes. The therapy used, promoted the recovery of glandular architecture as well as aided in the reduction of inflammatory processes. Thus, it is suggested that this treatment can act in two specific pathways, first blocking the inflammatory infiltrate in type I diabetes and then allowing the antioxidant action of the NAC to aid in the recovery of glandular homeostasis.

Keywords: Diabetes mellitus type I; Oxidative stress; N-acetylcysteine

Introduction

Hyperglycemia, characteristic of type 1 diabetes mellitus, can lead to an increase in the production of Reactive Oxygen Species (ROS). These oxidants, the final products of a small part of O₂, among them the radical superoxide anion, hydrogen peroxide and hydroxyl radicals, can further enhance cellular damage [1].

The main antioxidant defense system, constituted by enzymes such as superoxide dismutase (CuZn-SOD - cytosolic and extracellular, Mn-SOD-mitochondrial), catalas (heme-enzyme) and Glutathione Peroxidase (GR/GPX) that respectively decompose the anode O₂, H₂O₂ and lip peroxides are depleted in hyperglycemic conditions [2].

There are antioxidant treatments that can recover damages caused by diabetes. Among these, there is NAC (N-acetylcysteine), which is considered a potent antioxidant agent. Its action is due to the ability to stimulate the synthesis of reduced Glutathione (GSH), one of the enzymes responsible for the antioxidant defense system [3]. Studies have shown their inhibitory action in biomarkers of oxidative stress in different tissues. A work investigated the effect of N-acetylcysteine (NAC) on the expression of Nicotinamide Adenine Dinucleotide Phosphate oxidase (NADPH), antioxidant enzymes and inflammatory markers in diabetic rats. The authors found satisfactory answers where NAC showed protective and antioxidant effects in cardiac tissue [4]. Corroborating this, a study evaluated the effects of NAC in the reduction of oxidative tissue damage in the liver and kidneys of diabetic rats. The authors observed a significant decrease in lipid peroxidation, especially in renal tissue [5]. However, another study observed that despite NAC presenting these beneficial effects, its protective effects on beta-pancreatic cells are not yet fully elucidated.

To this end, we used a transfer model of NOD mouse farms for NOD Scid mice to induce diabetes, using NAC as a treatment. With this, it was observed that after two weeks of administration of this treatment, there was an increase in the infiltration of CD4 and CD8 T lymphocytes, further accelerating the autoimmune process in this animal model [6].

This process occurs because the immune system is very sensitive to cysteine, which is a compound of NAC. With this, the greater intracellular quantity of cysteine promotes a greater infiltration of T cells in the tissues, thus promoting the progression of the disease. On the other hand, a work, using specific antibodies, anti-CD4 and anti-CD8, managed to block the infiltration of CD4 and CD8 T lymphocytes in the beta-pancreatic cells of non-obese diabetic animals [7]. Therefore, an association between the NAC and these two therapeutic agents would be possible, in an attempt to block the infiltration of the T lymphocytes, promoted by the NAC, allowing only its antioxidant action. Thus, it is clear that diabetes is related to the oxidative stress process, NAC can be an antioxidant and a potential therapeutic agent when it is associated with anti-CD4 and anti-CD8 antibodies, which can improve insulin sensitivity and modulate the production of free radicals [4-7].

In this way, in salivary glands, which present structure morphologically similar to the pancreas and are affected in the same way by the hyperglycemic condition, the use of antioxidant could decrease oxidative stress and inflammation, thus recovering the morphology of the salivary tissues. Thus, the objective of this study will be to verify the effects of prolonged treatment with NAC and its associations and on the salivary tissues, observing mainly the antioxidant action in the recovery of these tissues.

Table 1: Mean levels of Glucose (mg/dL) between the groups studied.

	Levels of Glucose (mg/dL)
Group I (Balb/c healthy)	143.50±21.79 ^a
Group II (NOD unhealthy)	605.25±31.23 ^a
Group III (NOD Nac + CD4 and CD8)	515.62±39.27 ^{2,b}

Values expressed by the mean ± standard deviation.
a,b Different in significance (P <0.05).

Materials and Methods

15 female mice divided into Group I (5Balb/C control animals) were used. Group II (5 animal's diabetic controls NOD) and Group III (5 diabetic NOD treated with Nac + Anti CD4 and Anti CD8). All the animals were in the age group of 15 weeks and weighing an average of 24 grams from the Multidisciplinary Center for Biological Research in the Animal Sciences Area of the State University of Campinas (CEMIB, certified by the ICLAS). These were maintained in a standardized way in relation to the environment, feeding and treatment in the Laboratory Animal Experimentation Sector of the Department of Morphology and Basic Pathology of the Faculty of Medicine of Jundiaí.

As soon as the hyperglycemic condition was confirmed, group III animals received 50mg/kg of the antioxidant N-acetylcysteine (NAC) daily for 21 days [8], as well as doses of 25µg of anti-CD4 and anti-CD8. -CD8 every 7 days intravenously (respectively on days: 0, 7, 14 and 21).

Weekly monitoring of all animals was done to evaluate blood glucose levels (mg/dL). The animals that presented glycemic values higher than 300mg/dl were considered diabetics. The blood of these animals was collected and analyzed in the Accu-Chek Performa apparatus (Roche, NY, USA). The blood samples were obtained by cardiac puncture, for metabolic analysis. After the experimental period, the female mice of all the groups were subjected to anesthesia with (130mg/kg) / Xylazine (6.8mg/kg) (1:1) and the samples of the Salivary glands. The animals were then sacrificed with a deepening of the anesthetic procedure (in accordance with the ethical norms in animal experimentation - Brazilian College of Animal Experimentation). The samples obtained were subjected to the stereological analysis.

All the animals studied received a solid diet in the form of grains and ad-libitum water as a solid diet. Throughout the experimental period, measurements were made of the daily liquid and solid consumptions in the animals of the five groups studied. The corporeal weights (g) of the animals were also verified at the beginning and end of the experimental period.

The samples of the parotid and submandibular salivary glands were fixed in Bouin's Solution (Picric acid solution), with subsequent inclusion in plastic resin (Paraplast Plus, Oxford Lab, USA) and stained with Hematoxylin and eEosin (HE) 35. The volumes Nucleic and cytoplasmic cells of the acinar cells of the parotid and Submandibular glands were measured from sheets for light microscopy. These volumes were obtained after the analysis of 50 cells of each animal totaling 250 acini per experimental group by the method of point counting similar to that described by Weibel (1979) [9]. For this study, intact acini and circular or ellipsoid nuclei with

Table 2: Nuclear and Cytoplasmic Volume of the Acinar Cells (µm³) of the submandibular glands.

	Nuclear Volume	Cytoplasmic Volume
Group I (Balb/c healthy)	189.48±05.92 ^a	534.73±63.21 ^a
Group II (NOD unhealthy)	39.62±04.24 ^a	71.29±18.86 ^a
Group III (NOD Nac + CD4 and CD8)	104.37±04.42 ^b	310.33±85.60 ^b

Values expressed by the mean ± standard deviation.
a,b Different in significance (P <0.05).

Table 3: Nuclear and Cytoplasmic Volume of the Acinar Cells (µm³) of the parotid glands.

	Nuclear Volume	Cytoplasmic Volume
Group I (Balb/c healthy)	137.82±37.27 ^a	497.74±58.81 ^a
Group II (NOD unhealthy)	33.46±01.68 ^a	98.37±10.95 ^a
Group III (NOD Nac + CD4 and CD8)	110.52±03.84 ^b	329.06±24.60 ^b

defined limits were considered.

The statistical study was performed for the following variables: glucose levels, nucleus volume of glandular acini (µm³), cytoplasm volume of glandular acini (µm³), number of inflammatory cells of the groups and variance (ANOVA) confidence simultaneously complemented by the nonparametric test of Kruskal-Wallis. The entire study was conducted with at least 5% significance.

Results

Analysis of the glycemic levels

High glucose levels were observed in diabetic animals without treatment (Group II). Recovery of these glycemic levels occurred in the group III animals submitted to treatment (Table 1).

Microscopy of light and stereological analysis

Submandibular salivary gland: In group I, seromucous acini were noted with mucosal columnar cells and basal nuclei. Among the acini we observed salivary ducts and discrete intercellular space (Figure 1A) (Tables 2,3). In untreated mice (Group III), involute cells and increased space between the acini were observed. The nuclei were located in the basal region (Figure 1B) (Tables 2,3). In treated diabetic animals (Group III), inverted acini were observed when compared to control animals, but significantly recovered compared to untreated animals (Figure 1C) (Tables 2,3).

Parotid salivary gland: In group I, serous acini with columnar cells with pyramidal format were observed. The basophilic cytoplasm and the basal nucleus were noted. Between the acini, discrete stromal space and salivary ducts were noted (Figure 1D) (Tables 2,3). In diabetic mice without treatment (Group II), the cells presented involutes and with increased interactive space. In most cases, an increase in the concentration of the substance in the soil and in the soil was observed, but recovered in relation to the animals without treatment (Figure 1F) (Tables 2,3).

Discussion

Glucose reduction was observed in group III animals compared to Group II animals. Healthy animals have fasting glucose levels of 180mg/dl. In diabetic animals, these levels reach or exceed 300mg/dl, thus showing the effective diabetic state. The high concentration of

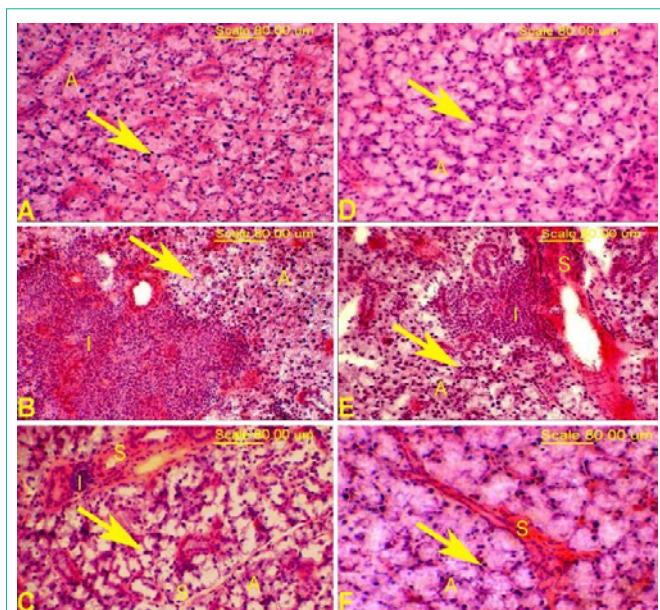


Figure 1: Photomicrograph of the submandibular and parotid salivary gland. A and D: In the control mice discrete stromal space was observed between the acini (arrow). Normal serous acini (A) and normal nuclei (arrow) in these animals. B and E: In diabetic mice the presence of greater stromal space (S) was observed. Inflammatory infiltrates (I), acini (A) and involuted nuclei (arrow). C and F: In mice of the treated groups, decreased stromal space was observed between the acini (S). Significant recovery of the acini (A) and nuclei (arrow).

glucose in the blood alters the metabolism, causing polyphagia where there is an increase in the consumption of solid due to the inability of the body to use glucose as a source of energy, with consequent decrease of body mass. Polydipsia where there is need of the organism to replenish the water used in the release of glucose by the urine [10,11]. Tissue disruption and hyperglycemia are a consequence of the disruption of insulin production, which leads the body to recruit other energy sources such as fats and proteins.

As for the salivary glands, in group II there was a decrease in the cytoplasmic and nuclear volume of the acinar cells and the presence of inflammatory infiltrates. In the literature there are various effects of diabetes in the salivary glands, studies have demonstrated accumulation of lipid droplets that is characteristic of tissue damage processes, alteration in saliva and these morphological alterations were more significant in Submandibular gland epithelium than of the parotid gland in mice with hyperglycemia [11-13].

Some research shows that NAC can be a potent antioxidant and anti-inflammatory agent under hyperglycemic conditions by rebalancing antioxidant enzymes, reducing inflammation and recovering specific tissues. It is possible to observe that these studies in the vast majority were in animals with Type II or chemically induced Diabetes [4,5,8,14-16].

On the other hand, in type I diabetes, NAC seems to stimulate the disease by enhancing its damage. N-acetylcystine contains a cysteine compound, which brings the immune system to the higher production of T lymphocytes [6]. Thus, in order to obtain the antioxidant action of NAC, it is necessary to associate TCD4 and CD8 lymphocyte blockers. In this regard, some studies demonstrated that

the administration of specific anti-CD4/CD8 antibodies were efficient in decreasing the infiltration of T lymphocytes into pancreatic beta cells of non-obese diabetic animals [17-20].

This demonstrates that an association between these two therapeutic agents is possible because the inhibitory action of anti-CD4 and CD8 on specific lymphocytes would allow the antioxidant action of the NAC causing a decrease of the inflammation and restoring the tissue structure of the cel [21-31].

Conclusion

The therapy used mainly when associated NAC to the anti-CD4/CD8 promoted the recovery of the glandular architecture as well as helped in the reduction of inflammatory processes. Thus, it is suggested that this treatment can act in two specific pathways, first blocking the inflammatory infiltrate in type I diabetes and then allowing the antioxidant action of the NAC to aid in the recovery of glandular homeostasis.

References

- Hunt J V, Smith CCT, Wolff SP. Antioxidative glycosylation and possible involvement of peroxides and free radicals in LDL modification by glucose. *Diabetes*. 1990; 39: 1420-1424.
- Matough FA, Budin SB, Hamid ZA, Alwahaibi N, Mohamed J. The role of oxidative stress and antioxidants in diabetic complications. *Sultan Qaboos University Medical Journal*. 2012; 12: 556-569.
- Ribeiro G, Roehrs M, Bairros A, Moro A, Charão M, Arajo F, et al. N-acetylcysteine on oxidative damage in diabetic rats. *Drug Chem Toxicol*. 2011; 34: 467-474.
- Xia Z, Guo Z, Nagareddy PR, Yuen V, Yeung E, McNeill JH. Antioxidant N-acetylcysteine restores myocardial Mn-SOD activity and attenuates myocardial dysfunction in diabetic rats. *Eur J Pharmacol*. 2006; 544: 118-125.
- Mansour HH, Hafez HF, Fahmy NM, Hanafi N. Protective effect of N-acetylcysteine against radiation induced DNA damage and hepatic toxicity in rats. *Biochem Pharmacol*. 2008; 75: 773-780.
- Irie J, Shimada A, Oikawa Y, Shigihara T, Saruta T. N-acetyl-cysteine accelerates transfer of diabetes into non-obese diabetic scid mice. *Diabetologia*. 2004; 47: 1803-1809.
- Phillips JM, Parish NM, Raine T, Bland C, Sawyer Y, De La Pena H, et al. Type 1 diabetes development requires both CD4+ and CD8 + T cells and can be reversed by non-depleting antibodies targeting both T cell populations. *Rev Diabet Stud*. 2009; 6: 97-103.
- Liu Y, Zhang H, Zhang L, Zhou Q, Wang X, Long J, et al. Antioxidant N-acetylcysteine attenuates the acute liver injury caused by X-ray in mice. *Eur J Pharmacol*. 2007; 575: 142-148.
- Weibel ER. Selection of the best method in stereology. *Journal of Microscopy*. 1974; 100: 261-269.
- Caldeira EJ, Alves Cagnon VH. IGF-I and INS receptor expression in the salivary glands of diabetic Nod mice submitted to long-term insulin treatment. *Cell Biol Int*. 2008; 32: 16-21.
- Caldeira EJ, Camilli JA, Cagnon VHA. Stereology and ultrastructure of the salivary glands of diabetic nod mice submitted to long-term insulin treatment. *Anat Rec - Part A Discov Mol Cell Evol Biol*. 2005; 286: 930-937.
- Mohsenifar Z, Feridoni MJ, Bayat M, Farahani RM, Bayat S, Khoshvaghti A. Histological and biomechanical analysis of the effects of streptozotocin-induced type one diabetes mellitus on healing of tenotomised Achilles tendons in rats. *Foot Ankle Surg*. 2014; 20: 186-191.
- Nones CFM, Reis RC, Jesus CHA, Veronez DADL, Cunha JM, Chichorro JG. Orofacial sensory changes after streptozotocin-induced diabetes in rats. *Brain Res*. 2013; 1501: 56-67.

14. Xu J, Lei S, Liu Y, Gao X, Irwin MG, Xia ZY, et al. Antioxidant N-acetylcysteine attenuates the reduction of Brg1 protein expression in the myocardium of type 1 diabetic rat. *J Diabetes Res.* 2013; 2013.
15. Rushworth GF, Megson IL. Existing and potential therapeutic uses for N-acetylcysteine: The need for conversion to intracellular glutathione for antioxidant benefits. *Pharmacology and Therapeutics.* 2014; 141: 150-159.
16. Heloisa M, Shimizu M, Coimbra TM, De Araujo M, Menezes LF, Seguro AC. N-acetylcysteine attenuates the progression of chronic renal failure. *Kidney Int.* 2005; 68: 2208-2217.
- 17.
18. Ildstad ST, Chilton PM, Xu H, Domenick MA, Ray MB. Preconditioning of NOD mice with anti-CD8 mAb and costimulatory blockade enhances chimerism and tolerance and prevents diabetes, while depletion of -TCR+ and CD4+ cells negates the effect. *Blood.* 2005; 105: 2577-2584.
19. Parish N, Cooke A. Characterization of CD8 monoclonal antibody-induced protection from diabetes in NOD mice. *Autoimmunity.* 2005; 38: 597-604.
20. Harmer AR, Chisholm DJ, McKenna MJ, Hunter SK, Ruell PA, Naylor JM, et al. Sprint training increases muscle oxidative metabolism during high-intensity exercise in patients with type 1 diabetes. *Diabetes Care.* 2008; 31: 2097-2102.
21. Delbin MA, Trask AJ. The diabetic vasculature: Physiological mechanisms of dysfunction and influence of aerobic exercise training in animal models. *Life Sciences.* 2014; 102: 1-9.
22. De Angelis KL, Oliveira AR, Werner A, Bock P, Belló-Klein A, Fernandes TG, et al. Exercise training in aging: hemodynamic, metabolic, and oxidative stress evaluations. *Hypertension.* 1997; 30: 767-771.
23. Finaud J, Lac G, Filaire E. Oxidative stress : relationship with exercise and training. *Sports Med.* 2006; 36: 327-358.
24. Packer L, Cadenas E, Davies KJA. Free radicals and exercise: An introduction. *Free Radic Biol Med.* 2008; 44: 123-125.
25. McBride JM, Kraemer WJ. Free Radicals, Exercise, and Antioxidants. *J Strength Cond Res.* 1999; 13: 175-183.
26. Sachdev S, Davies KJA. Production, detection, and adaptive responses to free radicals in exercise. *Free Radical Biology and Medicine.* 2008; 44: 215-223.
27. Singh S, Brocker C, Koppaka V, Chen Y, Jackson BC, Matsumoto A, et al. Aldehyde dehydrogenases in cellular responses to oxidative/electrophilic stress. *Free Radic Biol Med.* 2013; 56: 89-101.
28. Alessio HM, Goldfarb AH. Lipid peroxidation and scavenger enzymes during exercise: adaptive response to training. *J Appl Physiol.* 1988; 64: 1333-1336.
29. Avula CPR, Fernandes G. Modulation of lipid peroxidation and antioxidant enzymes in murine salivary gland by dietary fatty acid ethyl esters. *Life Sci.* 1999; 65: 2373-2383.
30. Evangelista FS, Brum PC, Krieger JE. Duration-controlled swimming exercise training induces cardiac hypertrophy in mice. *Brazilian J Med Biol Res.* 2003; 36: 1751-1759.
31. Contarteze RVL, Manchado FDB, Gobatto CA, De Mello MAR. Biomarcadores de estresse em ratos exercitados por natação em intensidades igual e superior à máxima fase estável de lactato. *Rev Bras Med do Esporte.* 2007; 13: 169-174.
32. Prada FJ, Voltarelli F, Oliveira CM, Gobatto C, Macedo DV, Mello MR. Condicionamento aeróbio e estresse oxidativo em ratos treinados por natação em intensidade equivalente ao limiar anaeróbio. *R bras Ci e Mov.* 2004; 12: 29-34.