

## Case Report

# Psoriasis Exacerbation Following COVID-19 Mrna Vaccination in an Elderly Patient

Gatzka MV<sup>1,2\*</sup>, Czech P<sup>3</sup> and Czech WJ<sup>2,4</sup><sup>1</sup>Medical Faculty, Ulm University, Germany<sup>2</sup>Department of Dermatology, Schwarzwald-Baar-Clinic, Germany<sup>3</sup>Histology Laboratory Laaf, Freiburg, Germany<sup>4</sup>Department of Dermatology, Freiburg University, Germany**\*Corresponding author:** Gatzka MV, Outpatient Clinic, Saarlandstr. 67, 78050 Villingen-Schwenningen, Germany**Received:** September 11, 2021; **Accepted:** October 06, 2021; **Published:** October 13, 2021**Abstract**

Psoriasis is a chronic recurrent inflammatory disease of the skin and joints mediated by different subsets of T-cells and other immune cells. Known trigger factors of psoriasis include bacterial, viral and fungal infections, various drugs, stress, and mechanic irritation. Onset of psoriasis post vaccination for influenza, tuberculosis and pneumococcal pneumonia has been observed, but the exact mechanisms are still unclear. We herein report of an elderly patient with a history of mild to moderate psoriasis episodes in the past years experiencing a severe generalized psoriasis flare-up two weeks after the second dose of a COVID-19 mRNA vaccination with Corminaty (bnt162b2 biontech/pfizer) had been administered. In the light of current data on psoriasis onset in context with COVID-19, potential molecular psoriasis trigger factors and disease mechanisms are briefly reviewed.

**Keywords:** COVID-19; mRNA vaccine; Psoriasis, T-cell; Toll-like receptor**Abbreviations**

DC: Dendritic Cell; IL: Interleukin; Th: T helper cell; TLR: Toll-Like Receptor

**Case Presentation**

An 82-year-old male presented in our outpatient clinic with disseminated erythrosquamous plaques on his extremities, trunk, and scalp, as well as palms and soles (Figure 1A). The Psoriasis Area and Severity Index (PASI) was 18. Two weeks prior to suffering from the skin symptoms the patient had received the second dose of a COVID-19 vaccination with Corminaty (bnt162b2 biontech/pfizer). He reported of a history of occasional mild to moderate psoriasis episodes in the past 7 years. A few years ago, a systemic treatment attempt with fumarates was stopped after a few months due to clinical improvement and lymphopenia. The patient's current long-term medication at the time of presentation included Marcumar and Bisoprolol for cardiovascular disease as well as L-Thyroxin; recently, Clemastin was prescribed to treat itching associated with the psoriasis flare-up. No history of allergies or eczema was reported.

**Diagnostics**

The H/E stainings of skin biopsies taken from the right flank and right palm showed hyperparakeratosis, acanthosis, and a lymphocytic infiltrate typical for psoriasis vulgaris (Figure 1B). Apart from an aberrant INR due to Vitamin K-antagonist treatment and slightly elevated creatinine level, no pathological findings were found in the blood analysis the total serum IgE level was 25kU/ml without any increases of specific IgE against common inhalation and food allergens in a multipanel screening.

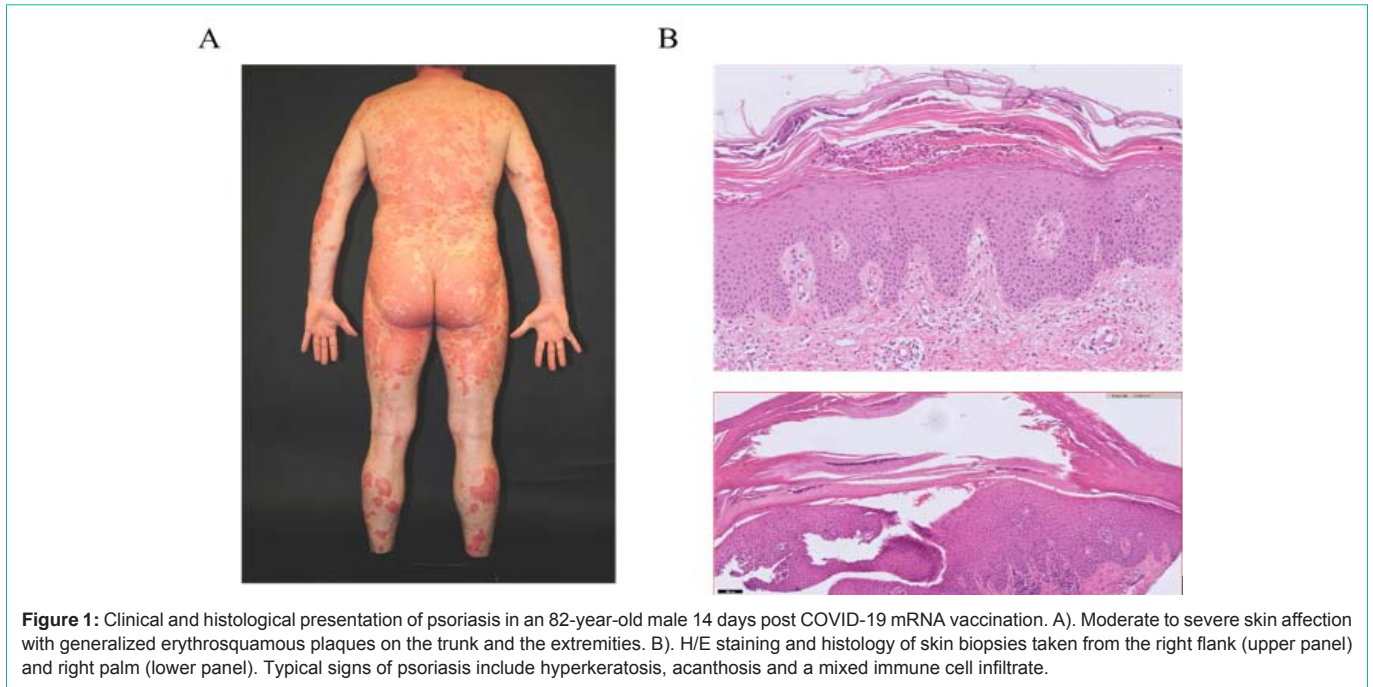
**Epicrisis**

In the hospital, the patient received a daily regimen of UVB 311nm light therapy in conjunction with topical treatment of the affected skin areas with Betamethasonvalerat 0.1% ointment. After excluding

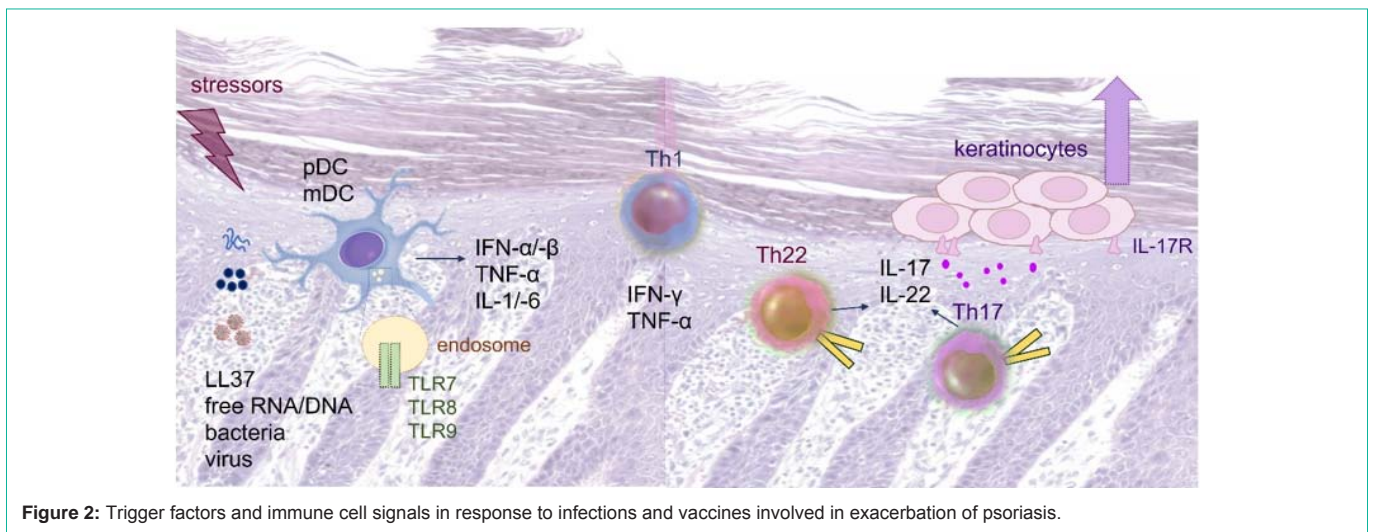
contraindications, systemic therapy with Methotrexate 20mg/weekly per os with folic acid substitution the following day was started. The treatment led to a good improvement of visible skin symptoms and reduced itching and soreness. The patient could be released from hospital with a PASI score around 8 and will be monitored further on an outpatient basis.

**Discussion**

The pivotal role of the Interleukin (IL)-23/ IL-17 axis and TNF- $\alpha$  in the pathogenesis of psoriasis is reflected by the efficacy of treatment with modern anti-IL17, anti-IL-23 and anti-TNF- $\alpha$  biologics [recently reviewed in 1]. Danger signals from infections agents, drugs or other stressors and from damaged cells, so called Pathogen Associated Molecular Patterns (PAMP) or damage associated molecular patterns, may initiate an inflammatory cascade via pathogen recognition Receptors (PRR), including different Toll-Like Receptors (TLR), and stress receptors in phagocytes patrolling the skin and other lymphoid organs [2]. In predisposed individuals, the subsequent release of proinflammatory cytokines may lead to the activation of aberrant T-cells, of keratinocytes, and other cells and trigger the onset of psoriatic skin inflammation [2]. Due to the higher risk for a severe course of infections, vaccination against potentially life-threatening infectious diseases, such as COVID-19, is generally strongly recommended for psoriasis patients receiving immunosuppressive agents, such as Mtx or Ciclosporin A [3]. In conjunction with the relatively new mRNA and vector vaccines administered for prevention of severe COVID-19 caused by SARS-CoV-2 infection, recently, rising numbers of cases of psoriasis flare-ups have been reported in patients with a history of psoriasis [4-7]. In our clinic, several patients of different age groups consulted for treatment because of an onset or exacerbation of psoriasis in context with SARS-CoV-2 infection or vaccination. Similarly, psoriasis exacerbations may occur in context with vaccines for influenza (H1N1), mycobacterial tuberculosis and bladder cancer (bacillus



**Figure 1:** Clinical and histological presentation of psoriasis in an 82-year-old male 14 days post COVID-19 mRNA vaccination. A). Moderate to severe skin affection with generalized erythrosquamous plaques on the trunk and the extremities. B). H/E staining and histology of skin biopsies taken from the right flank (upper panel) and right palm (lower panel). Typical signs of psoriasis include hyperkeratosis, acanthosis and a mixed immune cell infiltrate.



**Figure 2:** Trigger factors and immune cell signals in response to infections and vaccines involved in exacerbation of psoriasis.

calmette-guerin, BCG), pneumococcal pneumonia, diphtheria, and others [2]. Danger signals originating from microbial products, viral DNA and RNA, as well as self-DNA and -RNA released from damaged cells in the course of infections may activate TLR signaling. In particular, endosomal TLR7 and TLR8 are involved in sensing viral single stranded RNA, such as stomatitis virus, influenza and also corona viruses [8]. The intracellular cascade triggered by TLR activation in different subsets of dendritic cells and other immune cells results in the production of various inflammatory cytokines, including TNF $\alpha$ , IL-1, IL-6 and type I interferons as well as IL-12, and IL-23 [7,8]. Apart from alerting the adaptive immune systems to combat infections these cytokines, in individuals with psoriatic predisposition, may also lead to an activation of aberrant Th1, Th17 and Th22 cells, recruitment of neutrophils and macrophages, and activation of keratinocytes,-overall causing the onset of psoriasis.

### Conclusion

Vaccination against COVID-19 is generally recommended for most adults and children 12 years and older, including patients with psoriasis or other inflammatory skin diseases. Intermittent episodes of psoriasis in context of infections or vaccinations should be treated topically, with steroids in combination with UVB light therapy or Vitamin D analogs/steroid combinations, depending on disease history. Systemic treatment with Mtx or biologicals should be considered in refractory cases. Interplay of danger signals and inflammatory conditions of the skin may cause a modulation of immune responses making inhibitors of endosomal TLR signaling a potential new option for treatment of psoriasis [8].

### Acknowledgements

Informed consent of the patients involved in the report was

obtained.

## References

1. Rendon A, Schaeckel K. Psoriasis pathogenesis and treatment. *Int J Mol Sci.* 2019; 20: 1475.
2. Kamiya K, Kishimoto M, Sugai J, Komine M, Ohtsuki M. Risk factors for the development of psoriasis. *Int J Mol Sci.* 2019; 20: 4347.
3. Gisondi P, Geat D, Naldi L, Piaserico S. Insights into SARS-CoV2 vaccination in patients with chronic plaque psoriasis on systemic treatment. *J Eur Acad Dermatol Venereol.* 2021; 35: e361-e362.
4. Krajewski PK, Matusiak L, Szepietowski JC. Psoriasis flare-up associated with second dose of Pfizer BioNTech BNT16B2b2 COVID-19 mRNA vaccine. *J Eur Acad Dermatol Venereol.* 2021; 35: e632-e634.
5. Sotiriou E, Tsentemeidou A, Bakirtzi K, Lallas A, Ioannides D, Vakirlis E. Psoriasis exacerbation after COVID-19 vaccination: a report of 14 cases from a single centre. *J Eur Acad Dermatol Venereol.* 2021.
6. Elamin S, Hinds F, Tolland J. A case of de novo generalized pustular psoriasis following Oxford-AstraZeneca COVID-19 vaccine. *Clin Exp Dermatol.* 2021.
7. Fathizadeh H, Afshar S, Masoudi MR, Gholizadeh P, Asgharzadeh M, Ganbarov K, et al. SARS-CoV-2 (Covid-19) vaccines structure, mechanisms and effectiveness: A review: *Int J Biol Macromol.* 2021; 188: 740-750.
8. Lai CY, Su YW, Lin KI, Hsu LC, Chuang TH. Natural modulators of endosomal Toll-like receptor mediated psoriatic skin inflammation. *J Immunol Res.* 2017; 2017: 7807313.