

## Review Article

# Platelet Rich Plasma (PRP) for Treatment Non-Healing Ulcers: A Review Study

Shaheen A\*

Department of Dermatology, Tishreen University, Syria

\*Corresponding author: Abeer Shaheen, Department of Dermatology, Tishreen University, Lattakia, Syria

Received: March 17, 2018; Accepted: May 14, 2018;

Published: May 22, 2018

**Abstract**

**Background:** Platelets, an important reservoir of growth factors in the body, play an important role in many processes such as coagulation, immune response, angiogenesis and the healing of damaged tissues. Therefore, concentrate of platelets, which called Platelets Rich Plasma (PRP), will be very effective in previous processes.

**Discussion:** There are four steps to get good PRP: collect blood, separate the platelets, extract PRP and inject injured area with it. Although PRP treatment has useful effects, the special centrifuges for obtaining it are high cost, so they are inaccessible to many doctors and patients. However, by using usual centrifuges (specific RCF and specific time), we can obtain PRP with good platelet concentration, and low cost. Growth factors derived from platelets have significant roles in all phases of wound healing, as a result, PRP decreases the period of wound healing, so it is very effective in the treatment of chronic resistance wound such as non-healing ulcers, which is a major health problem affect the patient's quality of life with wound related mortality rate of 2.5%. Due to increased risk factors of atherosclerotic occlusion such as smoking, obesity and diabetes the incidence of these ulcers is expected to increase. Classical treatment is ineffective, but recent studies found that PRP is an effective treatment of these ulcers.

**Summary:** PRP decreases the period of wound healing, so it is very effective in the treatment of non-healing ulcers. And this is the main objective of this review study.

**Keywords:** Platelets; PRP; Growth factors; Wound healing; Non-healing ulcers

## Abbreviations

**PRP:** Platelet Rich Plasma; **PDGF:** Platelet-Derived Growth Factor; **TGF:** Transforming Growth Factor; **IL:** Platelet Factor Interleukin; **PDAF:** Platelet-Derived Angiogenesis Factor; **VEGF:** Vascular Endothelial Growth Factor; **EGF:** Epidermal Growth Factor; **IGF:** Insulin-Like Growth Factor; **RCF:** Relative Centrifugal Force; **RPM:** Revolutions Per Minute

## Introduction

Blood consists of cellular elements (erythrocytes, leukocytes, and platelets) and plasma (the liquid component of blood that is predominantly water, but also contains clotting factors, proteins, glucose, minerals, carbon dioxide, and oxygen) [1]. Platelets, an important reservoir of growth factors (Platelet-Derived Growth Factor (PDGF), Transforming Growth Factor (TGF), Platelet Factor Interleukin (IL), Platelet-Derived Angiogenesis Factor (PDAF), Vascular Endothelial Growth Factor (VEGF), Epidermal Growth Factor (EGF), Insulin-Like Growth Factor (IGF) and fibronectin [2] in the body, play an important role in many processes such as coagulation, immune response, angiogenesis and the healing of damaged tissues. Therefore, concentrate of platelets will be very effective in previous processes. This concentrate called Platelets Rich Plasma (PRP). The definition of platelet rich plasma proposed by

Marx in 2001, mentions 1 million platelets in one microlitre, a 4-5 fold increase in the concentration of platelets compared to whole blood [2]. Due to great regenerative potential with it high content of growth factors and other biologically active substances, PRP could be used in medical treatment aimed at skin rejuvenation, alopecia and excessive hair loss, reduction and removal of scars and striae, in patients with acne scars, wound care treatment, orthopedics in bone regeneration, osteoarthritis and tendinopathy [3]. PRP could also be use in some chronic resistance cases like non-healing ulcers, where classical treatment is ineffective, but recent studies found that growth factors derived from platelets have significant roles in all phases of wound healing, as a result, PRP decreases the period of wound healing, so it is very effective in the treatment of these ulcers. And this is the main objective of this review study.

## Process of PRP Therapy

There are four steps to get good PRP: collect blood, separate the platelets, extract PRP and inject injured area with PRP.

### Collect Blood

The following medical conditions are a contraindication for use of PRP: Critical thrombocytopenia (low platelet count), platelet dysfunction syndrome, Hypofibrinogenaemia, Haemodynamic instability (collapse), Sepsis (infection), Acute and chronic infections,

**Table 1:** Relationship between RPM and RCF according to rotor radius in centimeters.

Speed (RPM)	Rotor Radius (form enter of rotor to sample) in centimeters											
	4	5	6	7	8	9	10	11	12	13	14	15
1000	45	56	57	78	89	101	112	123	134	145	157	166
1500	101	126	151	176	201	226	252	277	302	327	352	377
2000	179	224	268	313	358	402	447	492	537	581	626	671
2500	280	349	419	489	559	629	699	769	839	908	978	1048
3000	402	503	604	704	805	906	1006	1107	1207	1308	1409	1509
3500	548	685	822	959	1096	1233	1370	1507	1643	1780	1917	2054
4000	716	894	1073	1252	1431	1610	1789	1968	2147	2325	2504	2683
4500	906	1132	1358	1585	1811	2038	2264	2490	2717	2943	3170	3396
5000	1118	1398	1677	1957	2236	2516	2795	3075	3354	3634	3913	4193
5500	1353	1691	2029	2367	2706	3044	3382	3720	4058	4397	4735	5073
6000	1610	2012	2415	2817	3220	3622	4025	4427	4830	5232	5635	6037
6500	1889	2362	2834	3306	3779	4251	4724	5196	5668	6141	6613	7085
7000	2191	2739	3287	3835	4383	4930	5478	6026	6574	7122	7559	8217
7500	2516	3144	3773	4402	5031	5660	6289	6918	7547	8175	8804	9433
8000	2862	3578	4293	5009	5724	6440	7155	7871	8586	9302	10017	10733
8500	3231	4039	4847	5654	6462	7270	8078	8885	9693	10501	11309	12116
9000	3622	4528	5433	6339	7245	8150	9058	9961	10867	11773	12678	13584
9500	4036	5045	6054	7063	8072	9081	10090	11099	12108	13117	14126	15135
10000	4472	5590	6708	7826	8944	10062	11180	12298	13416	14534	15652	16770
10500	4930	6163	7396	8628	9861	11093	12326	13559	14791	16024	17256	18489
11000	5411	6764	8117	9469	10822	12175	13528	14881	16233	17586	18939	20292
11500	5914	7393	8871	10350	11828	13307	14786	16264	17743	19221	20700	22178
12000	6440	8050	9660	11269	12879	14489	16099	17709	19319	20929	22539	24149
13000	7558	9447	11337	13226	15115	17005	18894	20784	22673	24562	26452	28341
13500	8150	10188	12225	14263	16300	18338	20376	22413	24451	26488	28526	30563
14000	8765	10956	13148	15336	17530	19722	21913	24104	26295	28487	30678	32869

**Table 2:** Differences between several Platelet Rich Plasma products [11].

Method	Manufacture	Disposable 1 kit price (USD)	Hardware list price (USD)	Time of preparation (min)	Approximate concentration factor
Kuh method	Konkuk University Hospital	9.53	352.21	15 (1 <sup>st</sup> )	3 (1 <sup>nd</sup> )
				30 (2 <sup>nd</sup> )	6 (2 <sup>nd</sup> )
Cell saver based system	www.fresenius-kabi.com	75-175	10.000	320	4-5
Biomet system GPS II	www.biomet.com	700	16.000	30	3-2
Regenlab	www.regenkit.com	320	850	30	2-6
Cytomedix angel	www.cytomedix.com	495	10.950	25	4-5
Autologet system	www.cytomedix.com	325	5.000	1-2	2-4
Genesis CS	www.vet-stem.com	1.550	11.500	16	10±3
Genesis CS-2	www.vet-stem.com	135	2.000	15	5.4
Harvest smart Prep 2 BMAC	www.harvesttech.com	420	9.950	16	4
Magellan	http://www.arteriocyte.com	350-495	9.950	17	5.1

Chronic liver disease, Anti-coagulation therapy (warfarin, dabigatran, heparin), tumor, metastatic disease and pregnancy [4,5]. At the outpatient clinic, at every application, 20-40 ml of blood is collected

and distributed into 10 ml test tubes with anticoagulant (1mL of sodium citrate and 9mL whole blood or 1.5 ml of citrate dextrose sodium and 8.5 ml of whole blood) [6-8].

**Table 3:** Wagner classification of diabetic foot ulcers.

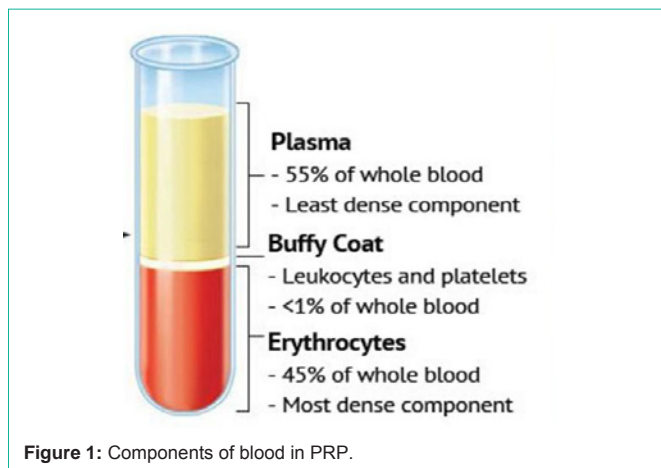
<b>Grade-0</b>	Foot symptoms like pain only
<b>Grade-1</b>	Superficial ulcer
<b>Grade-2</b>	Deep ulcer
<b>Grade-3</b>	Ulcer with bone involvement
<b>Grade-4</b>	Forefoot gangrene
<b>Grade-5</b>	Full foot gangrene

**Table 4A:** Percentage improvement in area after 6 weeks of PRP treatment [27].

Percentage improvement in area at the end of 6 <sup>th</sup> sitting	Number of ulcers	percentage
< 60	0	0
61-70	1	6
71-80	1	6
81-90	2	12
91-100	13	76

**Table 4B:** Percentage improvement in volume after 6 weeks of PRP treatment [27].


Percentage improvement in volume at the end of 6 <sup>th</sup> sitting	Number of ulcers	percentage
< 60	0	0
61-70	1	6
71-80	0	0
81-90	2	12
91-100	14	82



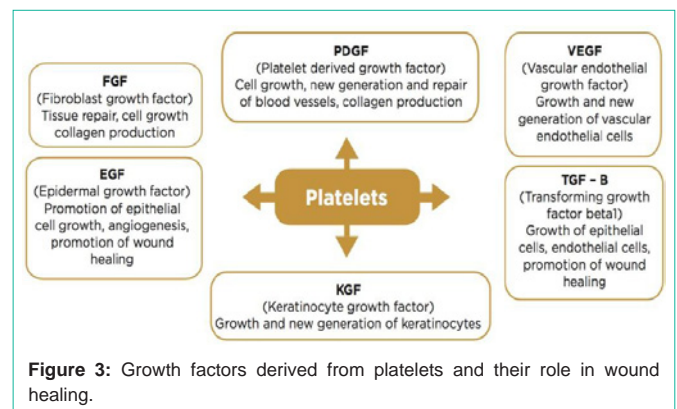
**Figure 1:** Components of blood in PRP.

**Separate the platelets**

The earth's gravitational force is sufficient to separate blood components over time, but the length of time required to separate these components and potential degradation of biological compounds during prolonged storage means faster separation techniques are needed. To resolve this issue, we need to increase the force of gravity many thousand times by using centrifuge. Centrifuge provides Relative Centrifugal Force (RCF) which separate the components of blood according to their molecular weight. RCF is expressed as multiples of the earth's Gravitational Field (g) [9]. RCF and centrifuge time are dependent on what types of blood components are to be made.



**Figure 2:** A) The blood sample after first centrifugation. B) The mixture between PRP and PPP. C) PRP gel [12].



**Figure 3:** Growth factors derived from platelets and their role in wound healing.

A 5-minute heavy spin (5000g) is required for preparation of Red Cells (hematocrit). A three-minute light spin (2000g) is used in preparation of Platelet Rich Plasma (PRP).

Centrifuge times that are given include acceleration time, but do not include deceleration time.

Relative centrifugal force (in g) is calculated using the following formula:  $RCF (in\ g) = 28.38 \times \text{radius of centrifuge rotor in inches} \times (\text{RPM}/1000)^2$ . RPM: Revolutions per minute [10]. According to the conversation between RPM and RCF is explained in (Table 1).

**Extract PRP**

After centrifuging, component of blood separate to 3 layer according to its molecular weight: Erythrocytes, most dense component, consist 45% of whole blood. Buffy coat (leukocytes and platelets), <1% of whole blood. Plasma, least dense component, 55% of whole blood (Figure 1). Each 10 ml of blood gives 1 ml of PRP, which is buffy coat. [11].

**Inject Injured Area with PRP**

PRP should be activated by calcium chloride (0.05 ml for each 1 ml of PRP), calcium gluconate (0.05 ml for each 1 ml of PRP), or thrombin (0.05 ml for each 1 ml of PRP). Activated PRP should be used immediately, because 70% of growth factors are released within 10 minutes. Therefore, clinicians should only activate PRP when they are ready to use it [12-17].

Although PRP treatment has useful effects, the special centrifuges for obtaining PRP are high cost, so they are inaccessible to many doctors and patients (Table 2) [11].

Grade 0	Grade 1	Grade 2
No ulcer in a high-risk foot 	Superficial ulcer involving the full skin thickness but not underlying tissues 	Deep ulcer, penetrating down to ligaments and muscle, but no bone involvement or abscess formation 
Grade 3	Grade 4	Grade 5
Deep ulcer with cellulitis or abscess formation, often with osteomyelitis 	Localized gangrene 	Extensive gangrene involving the whole foot  MD:A.N.

Figure 4: Wagner classification of diabetic foot ulcers.

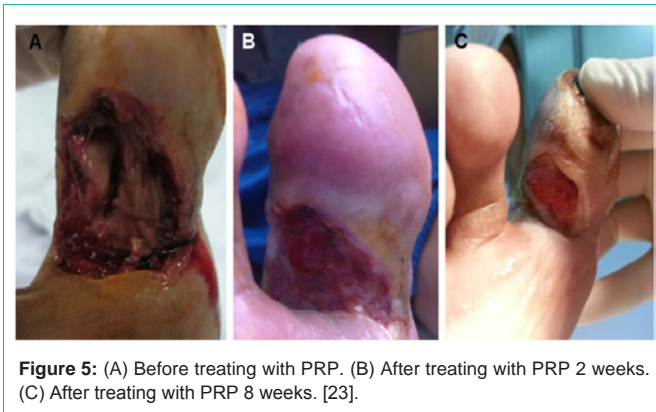


Figure 5: (A) Before treating with PRP. (B) After treating with PRP 2 weeks. (C) After treating with PRP 8 weeks. [23].

However, by using usual centrifuges (specific RCF and specific time), we can obtain PRP with good platelet concentration, and low cost [11].

As we said before, the basic formula for obtaining PRP is  $(2000\text{ g} = 28.38 \times \text{radius of centrifuge rotor in inches} \times (\text{rpm}/1000)^2)$  for three-minute, but some authors recommend experimenting several RMP for different periods of times, because each centrifuge has a different specialty [11].

For example, Han Moi Choi and his colleagues have done this experience [11]; twenty cc of whole blood from 58 patients was collected, distributed into two tubes (10 cc of blood and 1.5 cc of adenosine-citrate-dextrose-acid solution into each tube). Then, centrifugal separation was performed at 4000 RPM for 15 minutes. They had three - six folds concentration of platelets compared with the initial platelet count of whole blood. Note: the centrifuge is PLC-02, Gemmy Industrial Corp, Taipei, Tai- wan, with 10.7 cm radius.

Perego R and his colleagues have had this experience [12]; eight ml of blood was collected from 20 dogs, which was added to 1 ml of sodium citrate 3.8% in 10 ml tube (tube A). Double centrifugation protocol was followed for all tubes. The first centrifugation was 610g for 10 minutes which produce a Blood Cell Component (BCC) in the bottom of the tube and Sine Erythrocyte Components (SEC) in the

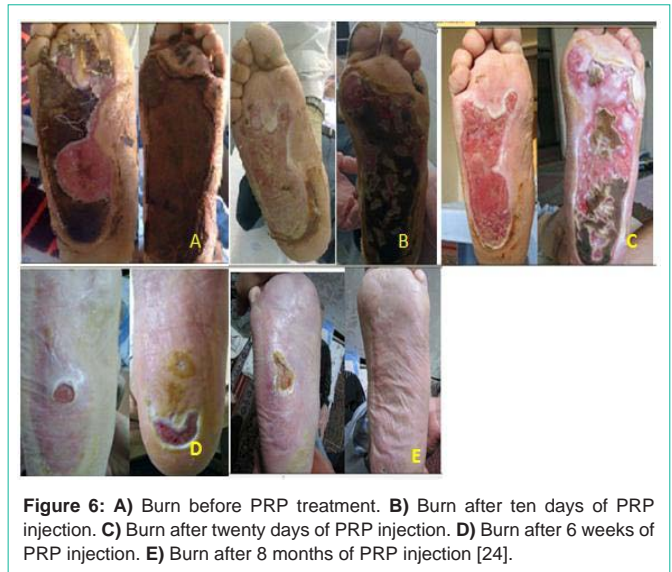


Figure 6: A) Burn before PRP treatment. B) Burn after ten days of PRP injection. C) Burn after twenty days of PRP injection. D) Burn after 6 weeks of PRP injection. E) Burn after 8 months of PRP injection [24].

upper fraction of the tube (Figure 2A). The entire SEC, containing buffy coat, was transferred to another 10 ml tube without anticoagulant (tube B) (Figure 2B) and centrifuged at 1600g for 15 minutes. This centrifugation produced two components: Platelet Poor Plasma (PPP) in the upper fraction and a platelet pellet in the lower fraction (visible as a red button on the bottom of the tube) (Figure 2C). After removing PPP, the platelet pellet was resuspended in approximately 25% of the PPP volume to obtain PRP. They obtained 858000 platelets in 1 ml of PRP. The centrifuge is EBA 20, Hettich, Germany.

Also, Omid Maghsoudi and his colleagues have done this experience [13]; 10 ml of blood was collected from 10 rabbits and added to 0.35 ml of sodium citrate 10%. They used double centrifugation, as before study, the first was 160g for 10 minutes, and the second was 160 g for 2 minutes then 400g for 15 minutes. 1 ml of PRP contain about 1800000 platelets.

### Non-Healing Ulcers

Non-healing ulcers or chronic ulcer are spontaneous or traumatic lesions persist despite initial appropriate therapy and do not heal naturally during the normal period of wound healing (they persist at least 4 weeks without healing). They are caused by underlying etiology that may be related to systemic diseases (such as diabetes mellitus, immunodeficiency, or malnutrition), local disorders (such as presence of necrotic tissue, infection, tissue hypoxia, or repeated trauma) or medications such as corticosteroids. There are many types of non-healing ulcers; venous, arterial, diabetic, pressure, pyogenic granuloma and traumatic ulcers. A high proportion of chronic ulcers are located on lower extremities, especially those attributed to venous disease, diabetes, or arterial disease. About 2-6 million people in the United States have non-healing ulcers, while its prevalence in the world ranges from 1.9 to 13.1%. These ulcers are major health problem, affect the patient's quality of life with wound related mortality rate of 2.5%. Due to increased risk factors of atherosclerotic occlusion such as smoking, obesity and diabetes, the incidence of these ulcers is expected to increase. Classical treatment is ineffective, but several studies have clarified the role of platelet rich plasma in the treatment of these ulcers, because platelets contain growth factors

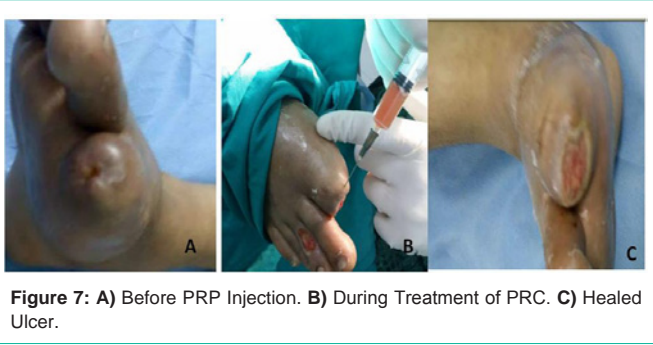


Figure 7: A) Before PRP Injection. B) During Treatment of PRC. C) Healed Ulcer.

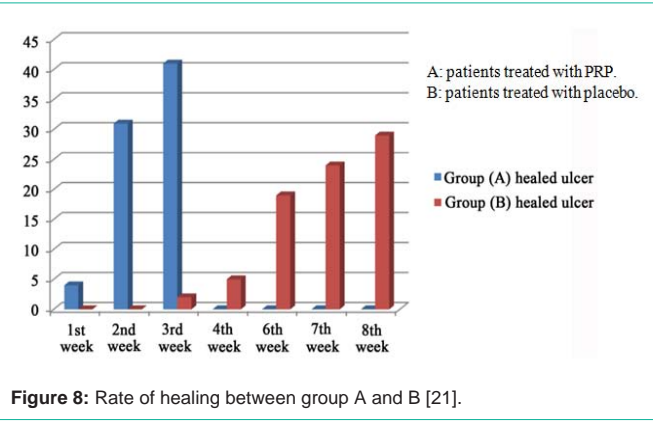


Figure 8: Rate of healing between group A and B [21].

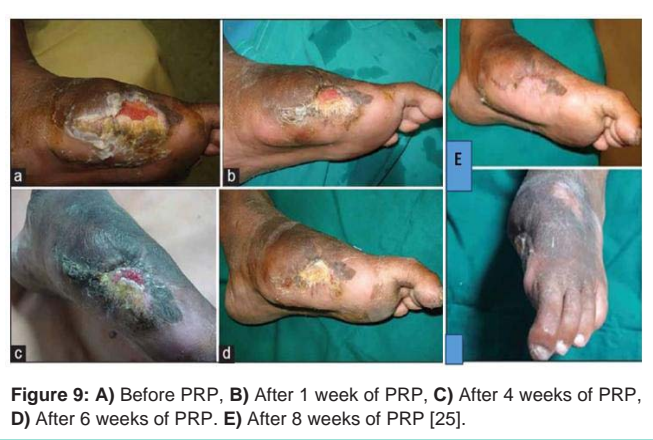

Figure 9: A) Before PRP, B) After 1 week of PRP, C) After 4 weeks of PRP, D) After 6 weeks of PRP. E) After 8 weeks of PRP [25].

that trigger wound healing etiology (cell migration, angiogenesis, cell proliferation and differentiation). However, to understand the role of PRP in treatment non-healing ulcers, we have to understand the etiology of normal wound healing and the role of cytokines of platelets in this etiology [8].

### Normal Wound Healing Process

Healing processes are classically divided into three phases: Hemostasis and Inflammatory phase, Proliferative phase, and Maturation and remodeling phase. Each phases are controlled by specific cytokines and specific cells, although they overlap each other [18]. However, if the normal healing process is interrupted, an ulcer can become chronic in nature due to lack of growth factors and cytokines which delay the healing process [8].

**Scottish Adapted European Pressure Ulcer Advisory Panel (EPUAP) Grading Tool**

**Progression of a pressure ulcer**

Grade	Description	Clinical Photo	Diagram
Grade 1	Non-blanchable erythema (redness) of intact skin. Discolouration of the skin, warmth, oedema, induration or hardness may also be used as indicators, particularly on individuals with darker skin		
Grade 2	Partial thickness skin loss involving epidermis, dermis, or both. The ulcer is superficial and presents clinically as an abrasion or blister		
Grade 3	Full thickness skin loss involving damage to or necrosis of subcutaneous tissue that may extend down to, but not through underlying fascia		
Grade 4	Extensive destruction, tissue necrosis, or damage to muscle, bone, or supporting structures with or without full thickness skin loss		

www.tissueviabilityonline.com/pu

Figure 10: Degree of pressure ulcers.

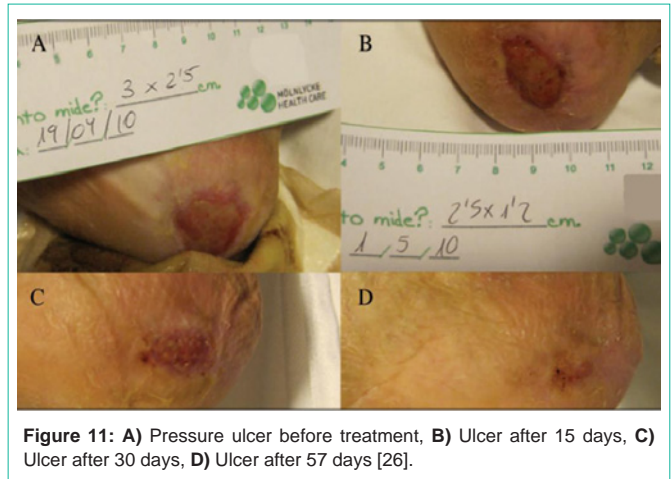


Figure 11: A) Pressure ulcer before treatment, B) Ulcer after 15 days, C) Ulcer after 30 days, D) Ulcer after 57 days [26].

### Hemostatic and inflammatory phase

This phase begins immediately after the occurrence of trauma, and continue for 4-6 days. It contains vascular response and cellular response. Vascular response: Immediately the injured vessels undergo vasoconstriction (10-15 min) is followed by vasodilation due to activation of mast cells, which is important for the chemotaxis of neutrophils, macrophages, and lymphocytes. The increased blood flow, triggering the signs of inflammation, such as heat, edema and redness. Platelets aggregate at the site of injury, leading to blood clot (the coagulation system). Blood clot is temporarily seal the bleeding, and act as a reservoir for growth factors and cytokines, and cell migration. Blood clots predominantly consist of fibrin, but other Extracellular Matrix (ECM) proteins, such as fibronectin, vitronectin, and thrombospondin, are also present.

### Cellular response

The first inflammatory cells arriving to the injury site are Neutrophils, which kill microbes, and provide a source of proinflammatory cytokines. Monocytes enter the wound bed and develop into activated macrophages, which secrete numerous growth factors and cytokines that act on fibroblast, endothelial

cells, and keratinocytes, such as: Platelet-Derived Growth Factor (PDGF), Transforming Growth Factor TGF- $\alpha$ , TGF- $\beta$ , and Vascular Endothelial Growth Factor (VEGF) [18].

### Proliferative phase

It begins around the third day after injury, lasts for 2 to 3 weeks. The aim of this phase is to restore the function of injured tissue, through reepithelialization, neovascularization, fibroplasia. Reepithelialization is the first visible event of the proliferative phase, which is characterized by the migration and proliferation of keratinocytes from the epidermis at the wound edge that occurs 1-2 days post-wounding. Epidermal Growth Factor (EGF) has important role in this etiology. Neovascularization is the process of new blood vessel formation (granulation tissue) in response to tissue malnutrition. Vascular endothelial growth factor VEGF and Platelet Derived Growth Factor (PDGF) have important role in this phase. Fibroplasia; after injury, fibroblasts in normal tissue are attracted to the inflammation site, where they divide and produce the extracellular matrix molecules ECM. Fibroblasts only appear at the lesion site from the third day onwards, after leukocytes have cleansed the injured area. Fibroblast Growth Factor (FGF) and Transforming Growth Factor (TGF) have significant role in this phase, which they stimulate type I collagen secretion and other ECM components [18].

### Remodelling or maturation phase

An excess of unstable collagen, which produced during the proliferative phase, is degraded and replaced by stable collagen. The former has disorderly manner, while the latter has orderly alignment according to tension forces of the skin. This does not only decrease the size of the scar but also increases its tensile strength. The maximum tensile strength is achieved at 42 days after injury. The maturation phase persists for as long as the wound exists, although the increase in tensile strength stabilizes after 1 year in 70-80% of the area of intact skin. There is a balance between production and degradation of collagen fibers during this period, through the activity of collagenase [18].

As we have noted, growth factors derived from platelets have significant roles in all phases of wound healing (Figure 3), as a result, PRP decreases the period of wound healing [19,20].

## Diabetic Ulcers

Diabetic ulcers are one of the most difficult complications of diabetes. About 15% of all diabetic patients may complain from these ulcers. Because of diabetic neuropathy and infection, these ulcers become non-healing. 88% of all leg amputations were related to diabetic foot ulcers [21].

### Classification of diabetic foot ulcers

This classification, Wagner classification, has been the most widely accepted. It has six grades of lesions. The first four grades (grade 0, 1, 2, and 3) are based on the physical depth of the lesion in and through the soft tissues of the foot. The last two grades (grade 4 and 5) are completely distinct because they are based on the extent of gangrene and lost perfusion in the foot (Table 3 and Figure 4) [22].

Classical treatment is ineffective, but recent studies found that growth factors derived from Platelet Rich Plasma (PRP) are very effective in the treatment of diabetic ulcers [21].

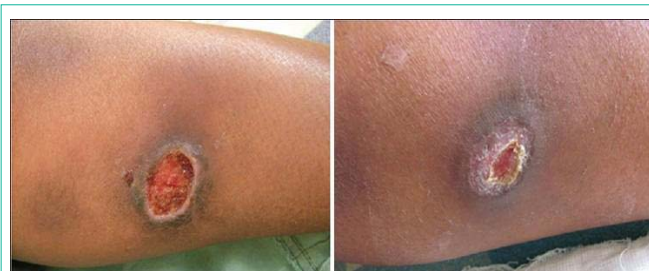

Figure 12: Patient [1] before and after 20 days of treatment with PRP [14].

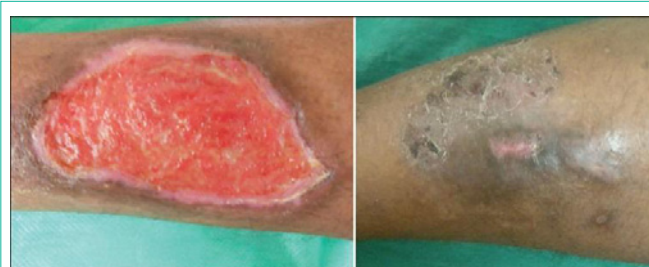

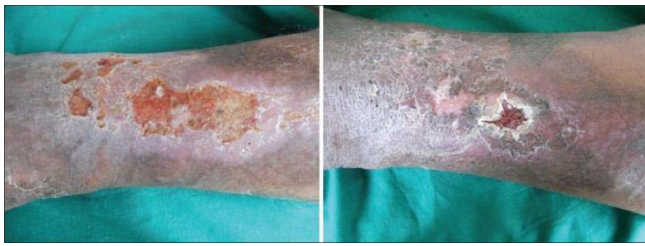
Figure 13: Patient [2] before and after 5 weeks of treatment with PRP [14].

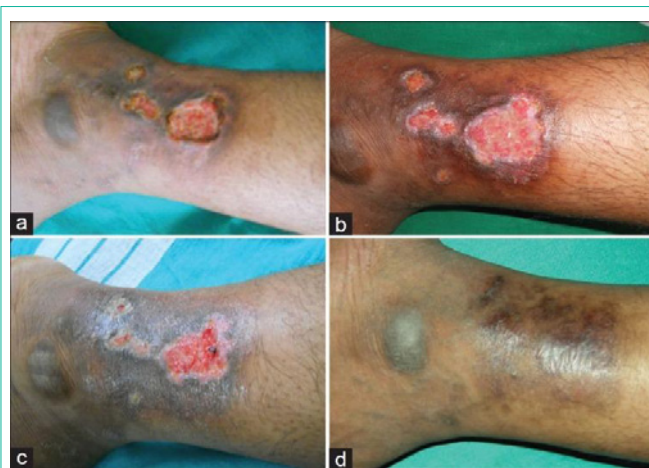

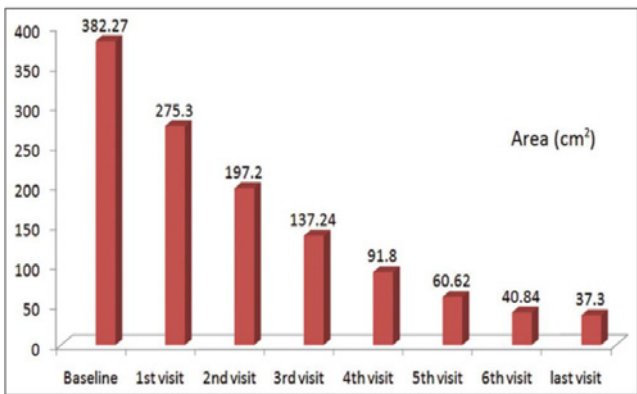
Figure 14: (a) Venous ulcer before treatment with PRP, (b) After one week of PRP, (c) Ulcer at 4<sup>th</sup> week and (d) Ulcer being healed at 6<sup>th</sup> week [27].

In Tung Dang-Xuan's study [23]; 6 patients with diabetic foot non-healing ulcers were injected with PRP two times with 14-day interval. All patients were monitored during 12 weeks. The results showed that 100% (6/6) ulcers completely closed after about 7 weeks (Figure 5). This result initially suggests that PRP injection is efficient method to treat the non-healing foot ulcers.

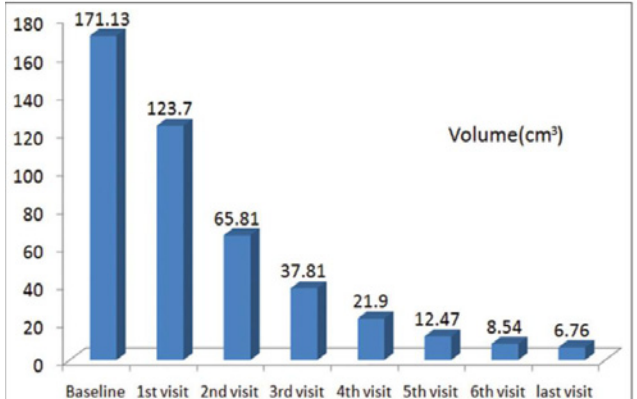
In Masoud Mehrannia's study [24]; a 71-year-old male patient with type II diabetes had severe burns on his soles by walking barefoot on a hot cobble stone surface (Figure 6A). He did not feel pain, because of diabetic neuropathy. PRP was separated from 6 units of his own blood, and injected 4 mm deep inside the wound and 1 cm of its peripheral skin, then standard dressing was applied. After 10 days, the dressing was removed, and the wound did not have any signs of infection (Figure 6B). After twenty days (Figure 6C), small islands of re-generation tissue began to granulate with epithelialization in progress. It was almost completely cured by the end of the eight



**Figure 15:** Venous ulcer before PRP treatment, and after 5 weeks treatment with PRP [27].



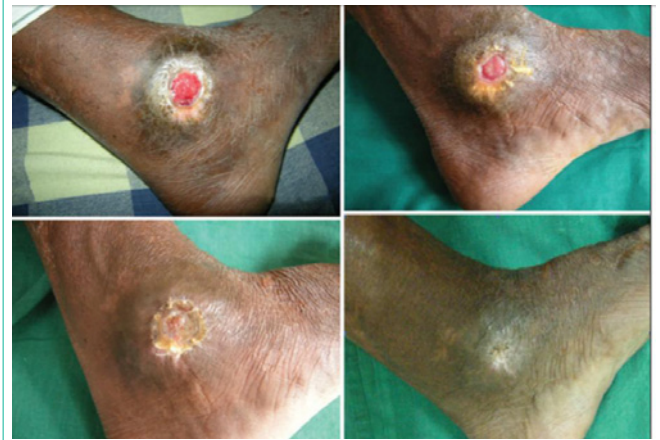**Figure 16:** Improvement of the area of the ulcer at the end PRP treatment [28].



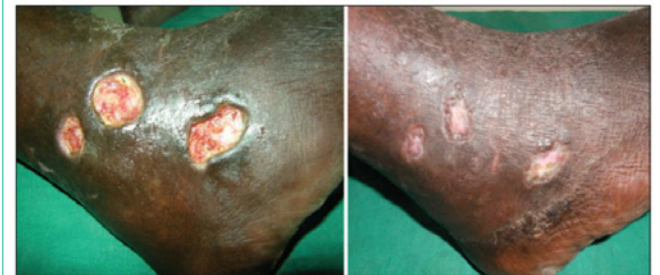**Figure 17:** Improvement of the volume of the ulcer at the end of PRP treatment [28].

month (Figure 6D,E).

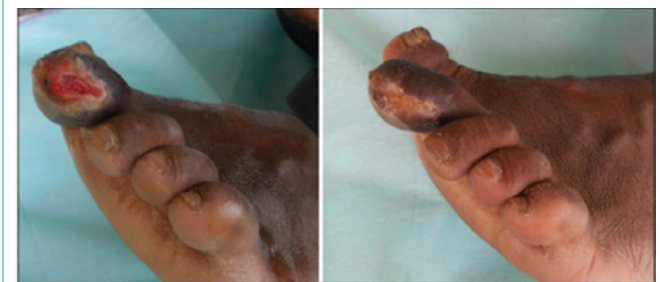In Aymen Salem’s study [21]; 73 patients with planter foot diabetic ulcers not healed for more than 3 months, were enrolled in this study. 2 groups (A, B) were created, 42 patients for group (A) treated with PRP, and 31 for group (B) treated with placebo. For PRP preparation 25 mL of the patient blood was collected. PRP was injected inside the wound peripheral skin, then dressing was applied. Ulcers were dressed by fibrin gel in the first day. If there is no healing after 2 weeks, the procedure can be repeated again. For patients treated with placebo, they had only balanced moist dressing. By the end of the 3<sup>rd</sup> week most of ulcers in group (A) were healed except one ulcer was infected and major amputation was done. In this moment



**Figure 18:** Trauma ulcer before and after 2 months of treatment with PRP [28].



**Figure 19:** Venous ulcer before and after 6 months of treatment with PRP [28].



**Figure 20:** Trophic ulcer before and after 3 months of PRP treatment [28].

only 6.4% of ulcers in group (B) were healed (Figure 7,8).

In Deepak H Suresh’s study [25]; a 57-year-old diabetic male presented with a non-healing wound over the left foot for 4 years, because of hot water spillage, which got secondarily infected and resulted in gangrene. He underwent amputation of great toe (up to metatarsal) for gangrene which left an ulcer over the amputated site. Three months following the amputation, split thickness graft was done for the ulcer. But there was graft failure resulting in a non-healing ulcer. After one year a second split thickness graft was done, but the ulcer did not heal. Then this non-healing ulcer was treated with PRP, which injected in the ulcer and the edge of it, covered by paraffin gauze and sterile gauze. PRP was repeated once weekly. After 1 week, there was reduction in area and the volume. The ulcer healed completely in 7 weeks (Figure 9).

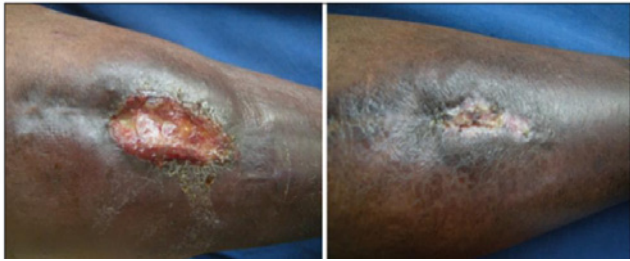

Figure 21: Traumatic ulcer before and after 4 months of PRP treatment [28].

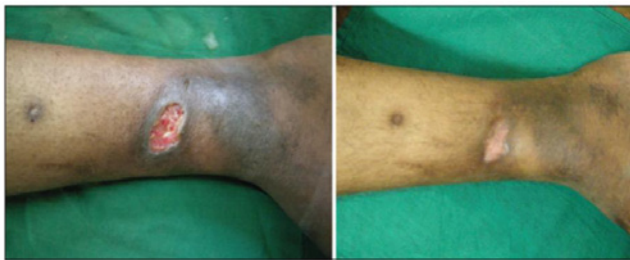

Figure 22: Venous ulcer before and after 7 months of PRP treatment [28].

### Pressure ulcers

Pressure ulcers are skin lesions caused by ischemia that affects cutaneous and subcutaneous tissue. They are caused by prolonged friction between two hard surfaces, the first is inner (bone prominence) and the second is external (bed as a result of prolonged lying). Degree of ulcer ranges from mild erythema to damage that affects subcutaneous tissue like muscles and bones (Figure 10). It needs prolonged hospitalization, and careful nursing care. Several studies found that PRP decreases the period of wound healing and consequently, decrease the hospitalization [26].

In Javier Ramos-Torrecillas's study; an 86-year-old woman developed a grade III pressure ulcer on her right heel, which did not have any signs of healing despite topical therapy over a 4-month period. This non-healing ulcer was treated with PRP for once, with a follow-up every 3 days for a period of 8 weeks. The ulcer closed completely at 54 days (Figure 11) [26].

### Pyoderma gangrenosum

Pyoderma gangrenosum is an idiopathic, inflammatory and ulcerative disease with unknown cause. Both topical and systemic immunosuppressors are commonly used for the ulcers of this ulcer, but these ulcers are often intractable despite treatment [14].

In Leelavathy Budamakuntla's study [14]; a 50-year-female presented with pyoderma gangrenosum over the posterior aspect of left leg for two and half months duration. Second case was a 60-year-old male presented with pyoderma gangrenosum over his left shin for one month. These ulcers were treated with PRP every weeks and covered with non-adherent dressing. Patient '1' showed improvement by 20 days (Figure 12). Patient '2' showed improvement in five weeks (Figure 13).

### Venous ulcers

Venous ulcers are the most common form of non-healing

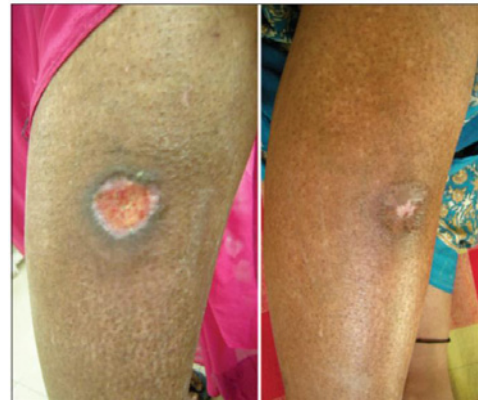

Figure 23: Traumatic ulcer before and after one sitting PRP treatment [28].

leg ulcers which has an important effect on quality of life. Classic therapies cannot provide significant healing, but PRP is a safe, simple, and cheap procedure in the treatment of this non-healing ulcer [27].

In Sacchidan and Sarvajnamurthy's study [27]; 12 patients with 17 venous ulcers were treated with PRP. Activated PRP was applied onto the wound after proper surgical debridement and was dressed with a non-absorbent dressing (paraffin gauze). This process was repeated once weekly for 6 weeks. The mean duration of the healing of the ulcers was in 5.1 weeks (Figure 14,15). 100% resolution in the area of the ulcers was seen in 13 (76%) (Table 4A). 100% resolution in volume of the ulcer was seen in 14 (82%) (Table 4B). **9.5. Non-healing leg ulcers**

In Shwetha Suryanarayan's study [28]; 24 patients with 33 non-healing leg ulcers of various etiologies (19 venous ulcers, 7 traumatic ulcers, 2 pyoderma gangrenosum, 2 diabetic ulcers, 2 trophic ulcers and 1 vasculitic ulcer) were treated with PRP once weekly for 6 weeks. The area and size were measured each time. 100% improvement in the area of the ulcers was seen in 25 (76%) of the ulcers (Figure 16) and 100% improvement in volume was seen in 24 (73%) of the ulcers (Figure 17) at the end of 6 weeks (Figure 18-23).

### Conclusion

Non-healing ulcer is a major health problem. Due to increased risk factors of atherosclerotic occlusion, the incidence of these ulcers is expected to increase. These ulcers affect the patient's quality of life and pose a significant financial burden. Classical treatment is ineffective, but recent studies found that growth factors derived from platelets have significant roles in all phases of wound healing, as a result, PRP decreases the period of wound healing, so it is very effective in the treatment of these ulcers. However, most of these studies are case reports or limited clinical studies, so further controlled, randomized prospective clinical trials are necessary to definitively demonstrate its efficacy. There is also a need for the development of a standard protocol for the preparation of PRP, as literature currently there is no standardization of the procedure.

### References

1. Saucedo JM, Yaffe MA, Berschback JC, Hsu WK, Kalainov DM. Platelet-Rich Plasma. *The Journal of Hand Surgery*. 2012; 37: 587-589.
2. Lubkowska A, Dołęgowska B, Banfi G. Growth factor content in PRP and



- their applicability in medicine. *J Biol Regul Homeost Agents*. 2012; 26: 3-22.
3. Bednarska K, Kieszek R, Domagała P, Jedrzejko K, Zieba M, Bieniasz M, et al. The Use of Platelet-Rich-Plasma in Aesthetic and Regenerative Medicine. *MEDtube Science*. 2015; 3.
  4. Ranaweera A. Platelet-Rich Plasma. *DermNet New Zealand*. 2013.
  5. Anila S, Nandakumar K. Applications of Platelet Rich Plasma for Regenerative Therapy in Periodontics. *Trends Biomater Artif Organs*. 2006; 20: 78-83.
  6. Pinto JM, Pizani NS, Kang HC, Silva LA. Application of platelet-rich plasma in the treatment of chronic skin ulcer - Case report. *An Bras Dermatol*. 2014; 89: 638-640.
  7. Zandim BM, de Souza MV, Magalhães PC, Benjamin LA, Maia L, de Oliveira AC, et al. Platelet activation: Ultrastructure and morphometry in platelet-rich plasma of horses. *Pesquisa Veterinária Brasileira*. 2012; 32: 83-92.
  8. Suthar M, Gupta S, Bukhari S, Ponemone V. Treatment of chronic non-healing ulcers using autologous platelet rich plasma: a case series. *Journal of Biomedical Science*. 2017; 24: 16.
  9. Dhurat R, Sukesh MS. Principles and Methods of Preparation of Platelet-Rich Plasma: A Review and Author's Perspective *J Cutan Aesthet Surg*. 2014; 7: 189-197.
  10. Practical Transfusion Medicine. Feldman BF, Sink CA, editors. Publisher: Teton New Media, Jackson, WY, USA ([www.tetonnm.com/](http://www.tetonnm.com/)). Internet Publisher: International Veterinary Information Service, Ithaca NY ([www.ivis.org/](http://www.ivis.org/)), Last updated: 2008; A4805.0708.
  11. Choi HM, Kim SH, Kim CK, Choi HG, Shin DH, Uhm KL, et al. The Cheapest and Easiest Way to Make Platelet-rich Plasma Preparation. *Arch Aesthetic Plast Surg*. 2015; 21: 12-17.
  12. Perego R, Proverbio D, Baggiani L, Roggero N, Giorgi GBD, Spada E. In House Double Centrifugation Method for Preparation of Homologous Platelet-Rich Plasma (Prp) in Dogs. *EC Veterinary Science*. 2016; 126-132.
  13. Maghsoudi O, Beheshtiha SS, Abarkar M, AlalehAnvar S. Standardization and Modification Techniques of Platelet-Rich Plasma (PRP) Preparation in Rabbit. *Int Clin Pathol J*. 2015; 1: 00007.
  14. Budamakuntla L, Suryanarayan S, Sarvajnamurthy SS, Hurkudli SD. Autologous Platelet Rich Plasma in Pyoderma Gangrenosum - Two Case Reports. *Indian J Dermatol*. 2015; 60: 204-205.
  15. Bausset O, Giraudo L, Veran J, Magalon J, Coudreuse JM, Magalon G, et al. Formulation and Storage of Platelet-Rich Plasma Homemade Product. *Biores Open Access*. 2012; 1: 115-123.
  16. Roh YH, Kim W, Park KU, Oh JH. Cytokine-release kinetics of platelet-rich plasma according to various activation protocols. *Bone Joint Res*. 2016; 5: 37-45.
  17. Silva RF, Álvarez ME, Ríos DL, López C, Carmona JU, Cleuza MF. Evaluation of the effect of calcium gluconate and bovine thrombin on the temporal release of transforming growth factor beta 1 and platelet-derived growth factor isoform BB from feline platelet concentrates. *BMC Vet Res*. 2012; 8: 212.
  18. Mcnaught C, Young A. The physiology of wound healing. *Surgery (Oxford)*. 2011; 29: 475-479.
  19. Eppley, BL, Woodell, JE, Higgins J. Platelet quantification and growth factor analysis from platelet-rich plasma: Implications for Wound Healing. *Plast Reconstr Surg*. 2004; 114: 1502-1508.
  20. Lacci KM, Dardik A. Platelet-Rich Plasma: Support for Its Use in Wound Healing. *Yale J Biol Med*. 2010; 83: 1-9.
  21. Salem A, Tawfik AM. Role of Platelet Rich Plasma in Treatment of Diabetic Foot Ulcers. *Surgical Science*. 2016; 7: 272-277.
  22. Amit Kumar C Jain. A new classification of diabetic foot complications: a simple and effective teaching tool. *The Journal of Diabetic Foot Complications*. 2012; 4: 1-5.
  23. Dang-Xuan T, Thi-Bich Le P, Pham PV. Diabetic foot ulcer treatment by activated platelet rich plasma: a clinical study. *Bio Med Press*. 2014; 1: 2
  24. Mehrannia M, Vaezi M, Yousefshahi F, Rouhipour N. Platelet rich plasma for treatment of non-healing diabetic foot ulcers: a case report. *Can J Diabetes*. 2014; 38.
  25. Suresh DH, Suryanarayan S, Sarvajnamurthy S, Puvvadi S. Treatment of a non-healing diabetic foot ulcer with platelet-Rich Plasma. *J Cutan Aesthet Surg*. 2014; 7: 229-231.
  26. Ramos-Torrecillas J, De Luna-Bertos E, García-Martínez O, Ruiz C. Use of platelet-rich plasma to treat pressure ulcers: a case study. *J Wound Ostomy Continence Nurs*. 2013; 40: 198-202.
  27. Sarvajnamurthy S, Suryanarayan S, Budamakuntala L, Suresh DH. Autologous Platelet Rich Plasma in Chronic Venous Ulcers: Study of 17 Cases. *J Cutan Aesthet Surg*. 2013; 6: 97-99.
  28. Suryanarayan S, Budamakuntla L, Sha Khadri SI, Sarvajnamurthy S. Efficacy of autologous platelet-rich plasma in the treatment of chronic nonhealing leg ulcers. *Plast Aesthet Res*. 2014; 1.