

## Case Report

## Burning Mouth Syndrome due to Sodium Metabisulfite

Aguiar R<sup>1\*</sup> and Correia TE<sup>2</sup><sup>1</sup>Department of Immunoallergology, Hospital Santa Maria, Portugal<sup>2</sup>Department of Dermatology and Venereology, Hospital Santa Maria, Portugal**\*Corresponding author:** Aguiar R, Department of Immunoallergology, Hospital de Santa Maria-Centro Hospitalar Lisboa Norte, AV. Prof. Egas Moniz, 1649-035 Lisboa, Portugal**Received:** November 02, 2016; **Accepted:** November 28, 2016; **Published:** November 29, 2016

## Introduction

The International Headache Society has defined the Burning Mouth Syndrome (BMS) as an intraoral burning sensation for which no medical or dental cause can be found [1]. Patients usually describe it as a painful burning sensation of the oral cavity, in the absence of clinically apparent mucosal alterations, more commonly occurring in middle-aged and elderly women [2]. It's possible cause has not been yet well established, and diagnosis and therapy are controversial [3]. Primary patients' treatment has been based on the avoidance of possible causes of oral irritation and the provision of psychological support [3]. The condition responds poorly to commonly used treatments and it may become very disabling [4].

The etiological factors involved in BMS have been extensively studied and differentiated into three subgroups: Type 1 patients have no burning on waking but the burning develops as the day goes on and worse in the evening; Type 2 the burning is present on waking and persists throughout the day. On both, the sensation is present every day and this is a different from Type 3 patients in whom the burning is intermittent, atypical and related to food allergy sensitization [5].

## Case Presentation

The authors report a 50-year-old woman, referring a painful and burning sensation of the oral cavity (dorsum of the tongue, soft palate and lips) for more than 2 years. The burning occurred intermittently with asymptomatic periods lasting for days or weeks, correlating with some foods. The oral mucous membrane had no inflammatory signs, teeth were in good repair and she wore an artificial denture of chromium-cobalt alloy. The burning did not respond to corticosteroids and/or antifungals. She had no evidence of atopy and was otherwise healthy.

Incisional biopsy was performed to the anterior third of the right edge of the tongue with no abnormal findings (Figure 1). Skin prick tests with commercial extracts of fruits that she related to worsening were negative. Prick-to-prick tests with fresh food were positive for grape, mango, tomatoes, kiwi, peach and apricot. Specific IgE for these fruits were negative.

She was patch tested with the Portuguese Contact Dermatitis Group basic series, "dental screening", metals and pastry series

## Abstract

Burning mouth syndrome is characterized by an idiopathic burning pain affecting the oral mucosa, with no clinically apparent changes. It can present to a variety of health professionals including allergologists and dermatologists. This article summarizes the important aspects of the condition, including diagnosis and management.

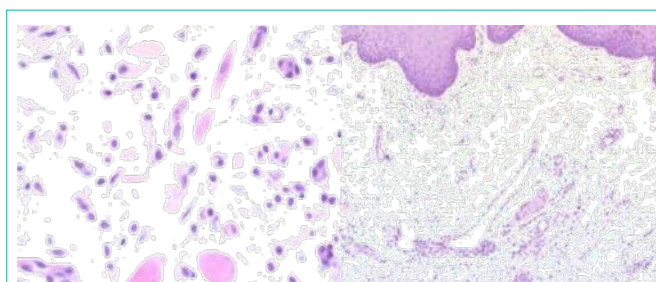
**Keywords:** Burning mouth syndrome; Sodium metabisulfite; Patch test

and the fruits involved. The only positive reaction was to 1% sodium metabisulfite (E223) (TROLAB<sup>®</sup>): 48h ++ and 96h +++ . The patient did a Single-Blind Food Challenge with capsules of sodium metabisulfite (Placebo, 25mg, 50mg, 100mg, 200mg) with immediate and late negative results. Despite this result and because of the patch result the patient was advised for avoidance of foods containing high sulfite levels. It was given a list of foods that contain high sulfite levels, and since avoiding these she has had no recurrence of the burning sensation.

## Discussion

The results proved that the patient suffered from an intermittent BMS (without objective symptoms of inflammation) due to Sodium Metabisulfite (SMS). The sulfites are widely used in pharmaceutical preparations, leather tanning and in fabric treatments [6,7], as well as in food industry as a preservative and antioxidant. In food, sulfite-derived preservatives are listed from E220 to E224. The Sodium Metabisulfite (SMS) is the most frequently used molecule [8]. Type IV-allergy to SMS occurs frequently due to epidermal contact to topical treatment containing sulphites and presents as contact dermatitis. In some individuals with asthmatic predisposition, reactions to sulphite compounds have been described upon oral intake or inhalation, rarely IgE-mediated reactions have been reported.

In our case, the clinical intermittent course led us to suspect of an allergic pathogenesis. There was a direct correlation between BMS and fruits that usually have high levels of SMS as preservative. The patch and the prick-prick tests support the diagnosis of allergy to SMS. The negative result of the oral provocation test was probably



**Figure 1:** Biopsy of the tongue, Microscopic description: Epithelium without changes, PAS staining was negative for yeasts.

due to the intake of the product inside a capsule, thus preventing the direct contact with the oral mucosa. The patient started on an exclusively organic diet without preservatives and she had no further complaints.

## Conclusion

BMS is not uncommon. The oral mucosa in BMS looks normal clinically and histologically. The evidence for pharmacological intervention in BMS is relatively weak, and there is no clear evidence-based first-line treatment.

This case stresses the need to declare preservatives and its avoidance in food and underscores the fact that the BMS has to be considered as a Type IV-sensitization.

## References

1. Headache Classification Subcommittee of the International Headache Society. The international classification of headache disorders. *Cephalalgia*. 2004; 24: 80-160.
2. Sun A, Wu KM, Wang YP, Lin HP, Chen HM, Chiang CP. Burning mouth syndrome: a review and update. *J Oral Pathol Med*. 2013; 42: 649-655.
3. Silvestre FJ, Silvestre-Rangil J, López-Jornet P. Burning mouth syndrome: a review and update. *Rev Neurol*. 2015; 60: 457-463.
4. Cárcamo Fonfría A, Gómez-Vicente L, Pedraza MI, Cuadrado-Pérez ML, Guerrero Peral AL, Porta-Etessam J. Burning mouth syndrome: Clinical description, pathophysiological approach, and a new therapeutic option. *Neurologia*. 2016.
5. Lamey PJ, Lamb AB, Hughes A, Milligan KA, Forsyth A. Type 3 burning mouth syndrome: psychological and allergic aspects. *J Oral Pathol Med*. 1994; 23: 216-219.
6. Madan V, Walker SL, Beck MH. Sodium metabisulfite allergy is common but is it relevant? *Contact Dermatitis*. 2007; 57: 173-176.
7. Przybilla B, Ring J. Sulfit-Uberempfindlichkeit. *Hautarzt*. 1987; 38: 445-448.
8. García-Gavín J, Parente J, Goossens A. Allergic contact dermatitis caused by sodium metabisulfite: a challenging allergen. A case series and literature review. *Contact Dermatitis*. 2012; 67: 260-269.