

Case Report

Metachronous Metastasis to Glans Penis from Colorectal Cancer

Papaeftymiou V¹, Hall A¹ and Ladoyanni E^{2*}¹Department of Radiology, Russells Hall Hospital, United Kingdom²Department of Dermatology, The Dudley Group Hospitals NHS Foundation Trust, Corbett Hospital, UK

***Corresponding author:** Evmorfia Ladoyanni, The Dudley Group Hospitals NHS Foundation Trust, Department of Dermatology, Corbett Hospital, Vicarage Road, Stourbridge, DY8 4JB, United Kingdom, Email: effie.ladoyanni@dgh.nhs.uk

Received: February 26, 2014; **Accepted:** March 22, 2014; **Published:** March 24, 2014

Abstract

Penile metastases from rectal adenocarcinoma are rare and usually develop after the prime tumor has manifested. They suggest disseminated disease and are associated with poor prognosis. They can develop very late in the clinical course of metastatic cancer and the clinical presentation can be very inconspicuous. Clinicians need to be aware of this late presentation. We present the case of a 78-year-old patient, who first appeared to our department with a symptomatic, fleshy, red papule on his glans penis, which looked like pyogenic granuloma. There had been a diagnostic conundrum. However, his past medical history suggested that his condition was clinically consistent with a cutaneous metastasis. That is the reason why we performed an urgent biopsy, which confirmed our diagnosis. Clinicians need to be aware of penile metastases' occurrence and undertake appropriate imaging and biopsy before treatment.

Case report

A 78-year-old man presented with a lesion on glans penis of two months duration. The lesion bled recurrently and profusely. His past medical history included Dukes B colorectal cancer initially treated with radiotherapy, combined chemotherapy and abdominoperineal resection. He had received a second course of chemotherapy two years later for relapsed colorectal cancer. At time of presentation, he had bladder outflow obstruction, related to sacral disease (Figure 1) and was receiving a third course of chemotherapy for colorectal cancer. On clinical examination, a 6x7mm fleshy, red papule was revealed on glans penis (Figure 2). Skin biopsy showed adenocarcinoma, consistent with adenocarcinoma from his rectal primary. Within 3 months of initial presentation he had died.

Adenocarcinomas of rectum mainly metastasize to regional lymph nodes, liver, lung and bones [1]. Metastatic involvement of the penis is rare, being first described by Eberth in 1870 [2]. The primary site of origin in order of frequency is bladder, prostate, rectum, recto sigmoid areas and kidney [1]. Lung and colorectal cancers have a very low tendency to metastasize to skin. Despite this, they are still common causes of cutaneous metastases simply because they are such common cancers [3]. There are isolated reports of metastasis to penis from upper gastrointestinal tract, lung, skin and osseous primaries [4]. Metastatic involvement of penis is rare, despite its rich vascularity and its proximity to rectum, bladder and prostate, which are common sites of malignancy [5].

It is very difficult to elucidate the exact mode of spread in individual cases, as penile metastasis is usually associated with disseminated disease. Retrograde venous route is presumed to be the commonest mode of spread to penis. The established communications between the dorsal venous system of penis and the venous plexuses draining the pelvic viscera provide routes for easy transportation of malignant cells from prostate, bladder and the recto-sigmoid. This would account for the vast majority of secondary lesions being localized on corpus cavernosa and glans penis [4]. Cutaneous metastases of

colorectal adenocarcinomas show specific CDX2 (a gene involved in the regulation of intestinal cell proliferation/differentiation) expression, although its sensitivity appears modest [6].

Because penile involvement by a secondary tumor usually indicates systemic dissemination the prognosis is poor. As our case illustrates, penile metastasis can represent a late development in the clinical course of metastatic cancer. The time interval between primary tumor and metastatic tumor ranges from 3 to 60 months, with a mean of 19 months [2]. Prognosis in the setting of penile metastasis is poor, with an average survival of 9 months [1]. Clinical evidence of penile involvement (presence of a penile shaft tumor, priapism) in a patient with a known malignancy is an ominous sign and should alert the clinicians to the dismal prognosis. Therapeutic modalities aimed to provide local and systemic control of the disease (penectomy, radiotherapy and chemotherapy alone or in combination) usually do not yield any substantial improvement in the outcome [4].

In conclusion, in this interesting case of colorectal adenocarcinoma, retrograde venous route may be a plausible explanation for the metachronous metastasis occurring to glans penis. In general, cutaneous metastases are bad news to the patient, suggesting underlying widespread metastatic disease, followed by death within a short period of time. Despite the fact that penile metastases are rare, clinicians need to be aware of their occurrence and undertake appropriate imaging and biopsy before treatment [5].

Learning points

- Adenocarcinomas of rectum rarely metastasize to glans penis
- Penile metastasis can represent a late development in the clinical course of metastatic cancer and represents a poor prognosis
- Clinicians need to be aware of penile metastases' occurrence and undertake appropriate imaging and biopsy before treatment

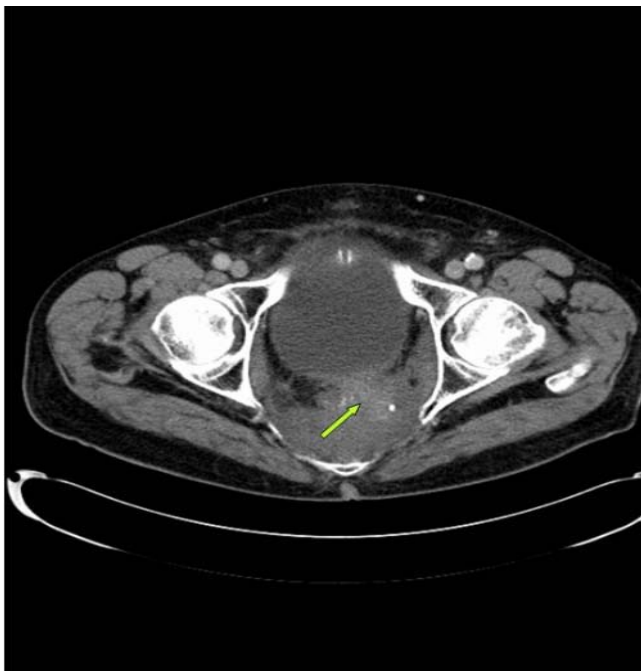


Figure 1: CT scan of the pelvis showing local recurrence: a soft tissue mass in the pre-sacral space (arrow) is inseparable from thickened posterior bladder wall and the left pelvic side wall muscles.

Figure 1: CT scan of the pelvis showing local recurrence: a soft tissue mass in the pre-sacral space (arrow) is inseparable from thickened posterior bladder wall and the left pelvic side wall muscles.

Figure 2: 6mm x 7mm fleshy, red papule on glans penis.

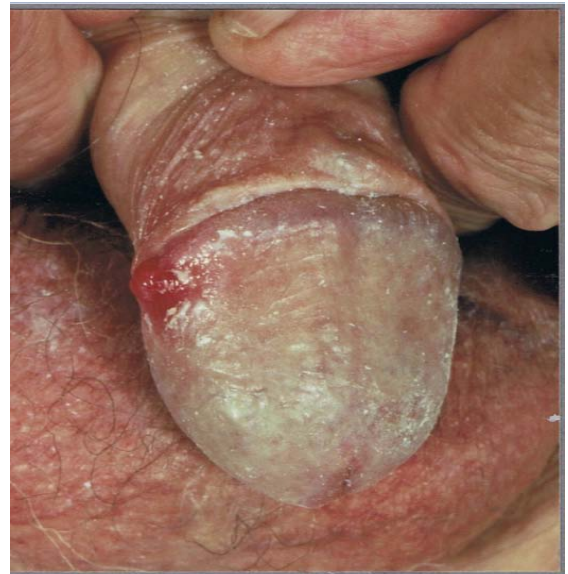

Figure 2: 6mm x 7mm fleshy, red papule on glans penis.

References

1. Ketata S, Boulaire JL, Soulimane B, Bargain A. Metachronous Metastasis to the Penis from a Rectal Adenocarcinoma. *Clin Colorectal Cancer*. 2007; 6: 657-659.
2. Chau A, Amin M, Cubilla AL, Young RH. Metastatic Tumors to the Penis: A Report of 17 Cases and Review of the Literature. *Int J Surg Pathol*. 2011; 19: 597-606.
3. Jeffery P, Challen, Joseph L, Jorizzo, Jean L, Bologna, et al. *Dermatological signs of Internal Disease*. 4th edn.: Saunders Elsevier publishing. 2009.
4. Cherian J, Rajan S, Thwaini A, Elmasry Y, Shah T, Puri R. Secondary penile tumours revisited. *Int Semin Surg Oncol*. 2006; 3: 33.
5. Appu S, Lawrentschuk N, Russell JM, Bright NF. Metachronous metastasis to the penis from carcinoma of the rectum. *Int J Urol*. 2006; 13: 659-661.
6. Lora V, Kanitakis J. CDX2 Expression in Cutaneous Metastatic Carcinomas and Extramammary Paget's Disease. *Anticancer Res*. 2009; 29: 5033-5037.