

Review Article

Assessment Sheet to Determine Whether Fixed Implant Prostheses Should be Replaced with Implant Overdentures in the Elderly

Tanaka J¹, Suzuki Y^{2,3*} and Ohkubo C^{2,3}

¹Clinical Implant Society of Japan, Kashiwa, Chiba, Japan

²Department of Removable Prosthodontics, Tsurumi University School of Dental Medicine, Yokohama, Japan

³Tsurumi University Center of Maxillofacial Implantology, Dental Hospital, Kanagawa, Japan

*Corresponding author: Yasunori Suzuki, Associate Professor, Department of Removable Prosthodontics, Tsurumi University School of Dental Medicine, 2-1-3, Tsurumi, Tsurumi-ku, Yokohama, Kanagawa, Japan

Received: November 30, 2021; Accepted: December 22, 2021; Published: December 29, 2021

Abstract

At a certain stage before a patient becomes unable to make hospital visits, replacement of fixed implant prostheses with Implant Overdentures (IOD) with simply structured attachments is a useful countermeasure against problems of fixed implant prostheses associated with aging and for maintaining a good oral environment. We investigated an evaluation method to determine whether to replace fixed implant prostheses with IOD in patients undergoing treatment with fixed implant prostheses.

Keywords: Implant overdentures; Fixed implant prostheses; Assessment sheet

Introduction

Fixed implant treatment is considered to be an excellent approach that places little strain on the surrounding teeth, with improved aesthetics and masticatory functions, leading to health and longevity for patients with dental defects. However, amid the rapid aging of society, the method of selecting treatment options for the elderly while taking their hand disabilities, dementia, and primary nursing care into account has become important [1-4].

As saliva secretion decreases with age, the level of oral self-cleaning falls. When hand disabilities worsen and motor functions deteriorate, oral cleaning becomes more difficult (Figure 1). In addition to such difficulties, aspiration pneumonia becomes a problem. To make matters worse, patients with dementia may refuse to accept oral care, resulting in very poor oral hygiene (Figure 2). When the upper structure of an implant falls off or when maintenance of the upper structure is neglected, the abutment may bite the tongue or other adverse events may develop (Figure 3).

Implant Overdentures (IOD) may be a highly beneficial prosthodontic therapy, facilitating mouth cleaning while maintaining masticatory functions [5-7]. At a certain stage before a patient becomes unable to make hospital visits, replacement of fixed implant prostheses with IOD with simply structured attachments is a useful countermeasure against problems of fixed implant prostheses associated with aging and for maintaining a good oral environment. Therefore, we investigated an evaluation method to determine whether to replace fixed implant prostheses with IOD in patients undergoing treatment with fixed implant prostheses.

Level Evaluation to Determine whether Fixed Implant Prostheses should be Replaced with IOD

IOD is particularly useful in primary nursing care situations, facilitating oral cleaning for example. Therefore, IOD is considered to be a good prosthetic method which can resolve a variety of problems

of fixed implant prostheses associated with aging. When a dentist knows a patient's level, the dentist can determine the optimal timing to replace the patient's fixed implant prostheses with IOD. Table 1 is an assessment sheet which objectively shows the level of patient. In the assessment sheet, six evaluation items regarding systemic and localized functions are scored on a five-point scale, and the total score is used to categorize the patient into one of the following four levels.

Level I: 10 to 14 (oral design change should be investigated), Level II: 15 to 19 (oral change is desirable), Level III: 20 to 24 (oral design change is recommended), Level IV: 25 to 30 (oral design change is necessary). Using this categorization, a dentist can objectively determine whether fixed implant prostheses should be replaced with IOD. The assessment sheet can also help to objectively encourage replacement by showing the evaluation results to the patient and family members.

Oral cleaning (including tongue and perioral areas)

Check the cleaning conditions of not only the teeth but also the tongue and perioral areas. In addition, whether oral cleaning can be conducted easily on prostheses should be checked and taken into account for the determination.

Alveolar ridge resorption

With aging, food residue tends to accumulate in the oral vestibule. With greater alveolar ridge resorption, cleaning becomes more difficult. Therefore, the degree of alveolar ridge resorption should be determined.

Hand disability (reduced dexterity)

Hand disability is directly associated with oral hygiene, and the level of hand disability should be determined. In addition, whether a patient can use his/her dominant hand should be checked and taken into account for the determination.

Oral function (gargling, swallowing and others)

Whether a patient can rinse in the mouth and hold the air in his/

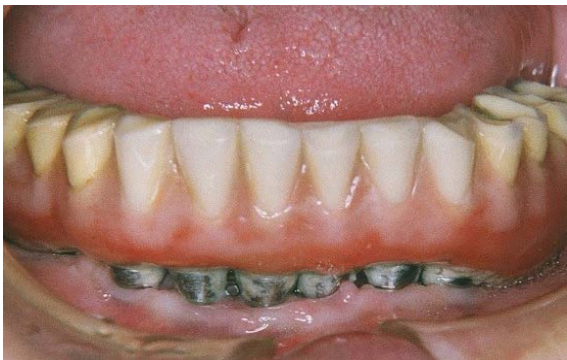

Figure 1: Poor oral hygiene of a fixed implant prosthesis by aging.

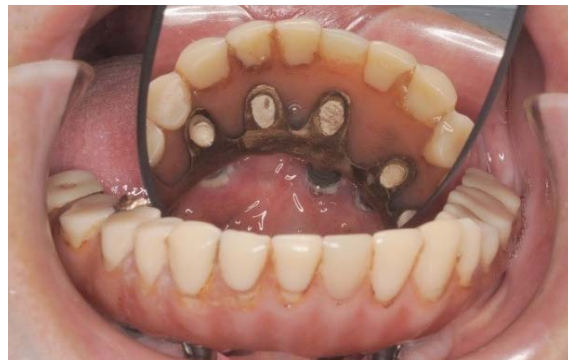

Figure 4: Fixed implant rehabilitation after 14 years.

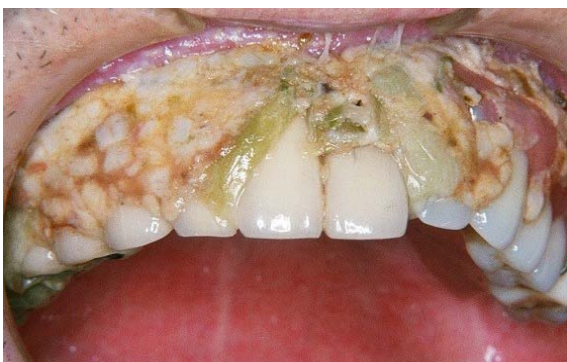

Figure 2: Serious oral hygiene after dementia.

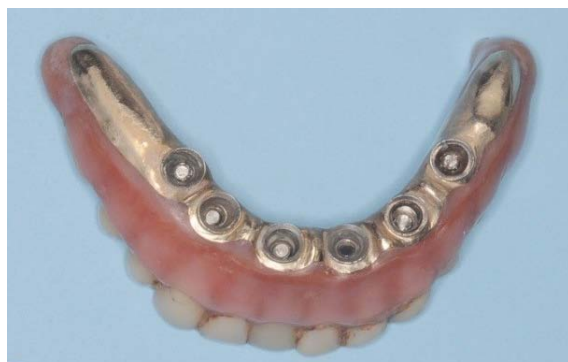

Figure 5: Poor care of basal surface.

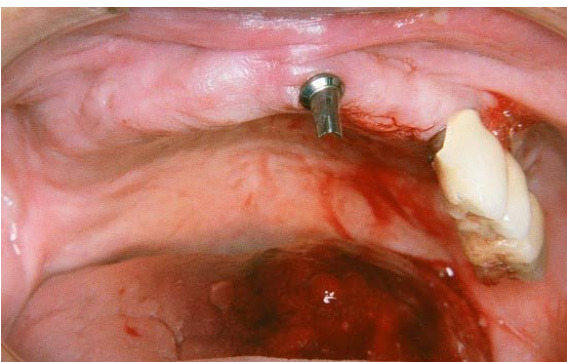


Figure 3: The upper structure of the implant fell off, causing the abutment to bite the tongue.

her cheeks should be determined. In addition, dysphagia tendency should be determined regarding whether a patient chokes during or after eating, has phlegm, or has other symptoms.

Lack of cognition and comprehension

When a patient develops dementia, it becomes difficult to maintain good oral hygiene. Therefore, the dementia tendency should be determined. When a patient develops dementia, it is difficult to get used to new dentures. Therefore, fixed implant prostheses should be replaced with IOD before a patient shows a dementia tendency.

Activities of daily living (ADL)

When a patient has difficulties in ADL, poor oral hygiene is likely.

Therefore, ADL should also be taken into account for the evaluation, which is based on the patient’s abilities in walking, eating, toileting, bathing, dressing, grooming, and communication, etc.

This paper reports cases in which an evaluation was conducted to determine whether fixed implant prostheses should be replaced with IOD as follow.

A 68-year-old male patient treated with a fixed implant 14 years earlier. His oral hygiene is poor (Figure 4). The patient exhibits poor oral care with a moderate degree of alveolar ridge resorption. In addition, the patient is considered to have no major problems in swallowing, cognition and perception, and ADL. However, the patient has poor hand dexterity due to rheumatoid arthritis.

He is considered to be entering a stage when a decision on changing the oral design to IOD should be made. Therefore, the assessment sheet was used to determine whether fixed implant prosthesis should be replaced with an IOD. The patient evaluated by assessment score (Table 2), the total score was 21. The score categorized the patient’s conditions into Level III “Oral design change is recommended.” After notifying the results to the patient, the patient requested to change the oral design to IOD. After the prosthesis was removed from the intraoral space, oral hygiene was poor, which can cause aspiration pneumonia (Figure 5). Fixed implant prosthesis was changed to IOD.

Biting prevention and oral care became easier, maintenance and stability are good, and the patient has a favorable course. Using magnetic attachments, universal-support dentures were developed (Figure 6a-6c). With universal-support dentures, a patient can

Table 1: Assessment sheet to determine whether fixed implant prostheses should be replaced with implant overdentures (Evaluated by Tanaka).

1) Oral cleaning (includes tongue and perioral areas)				
Poor ← - - - - → Good				
5	4	3	2	1
2) Alveolar ridge resorption				
High ← Moderate → Low				
5	4	3	2	1
3) Hand disability (reduced dexterity)				
Present ← - - - - → None				
5	4	3	2	1
4) Oral function (gargling, swallowing and others)				
Deteriorated ← - - - - → No deterioration				
5	4	3	2	1
5) Lack of cognition and perception				
Strong tendency ← - - - - - - - - - - → No tendency				
5	4	3	2	1
6) Activities of daily living ADL				
Having trouble ← - - - - - - - - - - → Having no trouble				
5	4	3	2	1
The patient's condition is categorized into four levels depending on the total score of the six evaluations.				
	Level I	Level II	Level III	Level IV
Total score	10~14	15~19	20~24	25~30

A total score of less than 10 is considered unnecessary.

Level I: Oral design change should be investigated.

Level II: Oral design change is desirable.

Level III: Oral design change is recommended.

Level IV: Oral design change is necessary.

The final determination should be made after taking into account the patient's age and cooperation level of the caregivers.

Regarding cognition and comprehension, when a patient develops dementia, it becomes difficult to get used to new dentures. Therefore, the oral design should be changed to implant overdentures before the patient develops dementia.

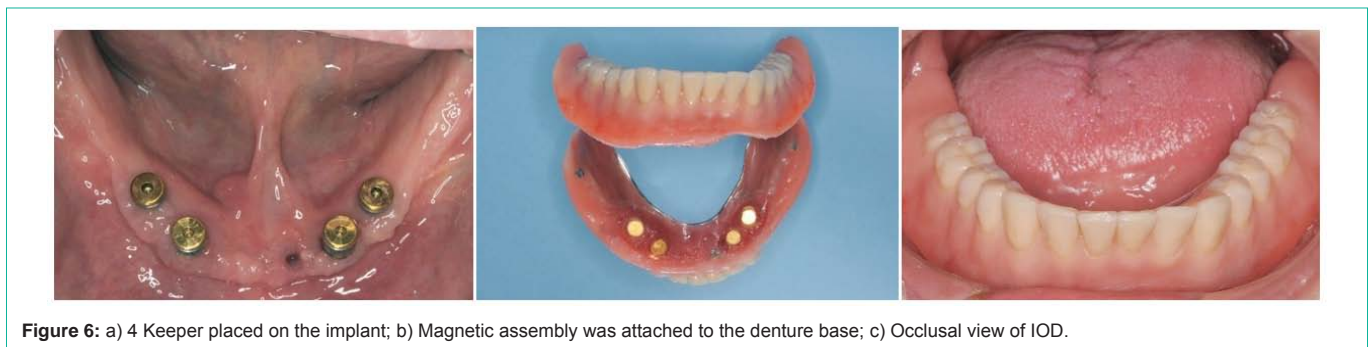

Figure 6: a) 4 Keeper placed on the implant; b) Magnetic assembly was attached to the denture base; c) Occlusal view of IOD.

remove the dentures with one hand even if the patient has rheumatoid arthritis. This prosthetic method is particularly useful when a patient requires primary nursing care (Figure 7).

Discussion

The evaluation to determine whether fixed implant prostheses should be replaced with IOD were 1) oral cleaning, 2) Alveolar ridge resorption, 3) Hand disability, 4) Oral function, 5) Lack of cognition and comprehension, 6) Activities of daily living (ADL).

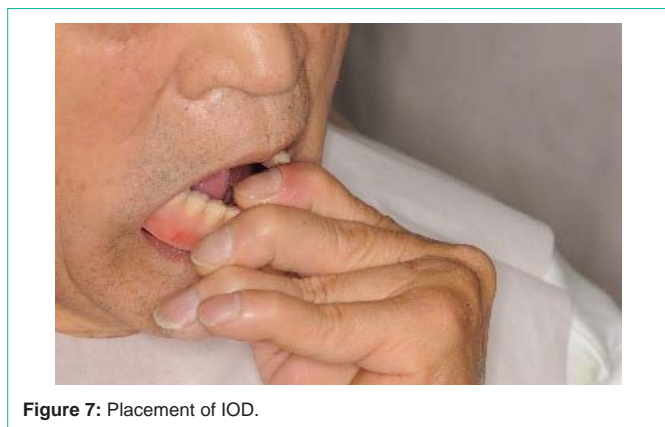
Comprehension and self-motivation may be related to the feasibility of oral cleaning when a patient requires primary nursing

care. When a patient has poor comprehension and self-motivation, the patient may refuse oral care and other treatments. Therefore, comprehension and self-motivation are essential evaluation items when determining whether IOD replacement is necessary.

Regarding alveolar ridge resorption, as people age, the amount of saliva secreted decreases. In addition, motor functions deteriorate. These factors make food residue more likely to accumulate in the oral vestibule. Especially when alveolar ridge resorption is high, food residue is much more likely to accumulate, making cleaning difficult. Regarding scores for evaluating the degree of alveolar ridge resorption, Cawood and Howell's classification [8] (Class I to VI), American

Table 2: Evaluation by assessment score.

1) Oral cleaning (includes tongue and perioral areas)	4
2) Alveolar ridge resorption	4
3) Hand disability (reduced dexterity)	5
4) Oral function (gargling, swallowing and others)	3
5) Lack of cognition and perception	3
6) Activities of daily living ADL	2
Total	21

**Figure 7:** Placement of IOD.

College of Prosthodontists (ACP)'s classification alveolar bone height measured on a panoramic radiograph [9], and a classification used by Kimoto et al. [10] were used as references.

When hand disabilities worsen (deteriorated motor skills), oral cleaning becomes more difficult, making it harder to insert and remove dentures. Accordingly, it is necessary to select attachments that are easier to remove for the elderly and people who require primary nursing care. It is also important to check whether a patient can use his/her dominant hand. If a patient develops hemiplegia due to a brain infarction or other cause, IOD, which can be removed by one hand, is recommended. Universal design means a design that can be readily used by both healthy and handicapped persons; universal-support [11] dentures, which take universal design into account, are preferred.

Regarding oral functions (gargling, swallowing, etc.), swallowing functions are closely related to perioral hygiene, especially with the accumulation of food residue in the oral vestibule. Spilled food and leakage from the angulus oris can be checked and taken into account for the determination. Swallowing functions are mostly associated with aspiration pneumonia. Therefore, as swallowing functions deteriorate, they can become a life-and-death issue depending on the state of oral hygiene. When making an evaluation, the repetitive saliva swallowing test (RSST: the number of times saliva is swallowed in a 30-second period is used; less than 3 swallows per 30 seconds is considered to be dysphagia) and the modified water swallowing test (MWST) are useful references.

The rinsing test and gargling test can be used as references. Also, oral diadochokinesis [12] can be referred to as a test of motor speed and finger dexterity. In oral diadochokinesis, an evaluation is made as follows: 1) Ask the patient to pronounce the syllables "pa", "ta"

and "ka" repeatedly as fast as possible; 2) Evaluate the number of syllables spoken and the rhythmic quality. In addition, the results of a tongue pressure test can be used as a decision index. The test is conducted as follows: 1) The patient uses his/her tongue to press a balloon-type sensor towards the palate; 2) The pressure applied by the tongue towards the palate is measured and evaluated. Regarding lack of cognition and comprehension, when a patient develops dementia, it becomes difficult to use new dentures. Therefore, the oral design should be changed to IOD at the stage where a patient shows signs of dementia, to enable the patient to get used to the IOD early on. A typical questionnaire method for evaluating dementia is the Mini-Mental State Examination (MMSE) [13]. Observational evaluation methods include the Functional Assessment Staging (FAST) [14] of self-supported degree in daily living for the elderly with dementia. The FAST is a seven-stage classification. Stage 3 (boundary state) is considered to be an especially important point for dental treatment. Patients in stage 3 have no trouble conducting daily activities, and so their disabilities are difficult to clearly recognize. A few patients have trouble with dental treatment. However, patients in stage 3 perform oral hygiene irregularly, and so might be diagnosed with dementia if their oral hygiene worsens. It becomes difficult to give instructions on how to use new cleaning devices and manual skills. Therefore, the oral design should be changed in stage 3 or before, as early as possible. After a patient enters a higher stage, the oral design should be changed after adequately investigating the patient's condition including whether the patient can cope with intraoral changes. Dementia progresses gradually, and so countermeasures should be taken while symptoms remain mild.

When a patient has trouble in ADL, oral care is likely to become poor. Therefore, the oral design should be changed to overdentures, which are easy to clean and give the patient a self-cleaning routine, and also make it easier for the patient's family members and caregivers to perform cooperative cleaning when the patient requires primary nursing care.

Conclusion

In anticipation of the conditions in primary nursing care, fixed implant prostheses should be changed to IOD, which are easier to handle and facilitate mouth cleaning, during the period while patients can still visit a hospital. In this paper, we introduced an evaluation sheet to determine whether fixed implant prostheses should be changed to IOD, to help dentists to determine the timing of IOD change. This sheet also shows the degree of necessity when dentists explain the change to patients and family members. This evaluation method also provides a useful reference when selecting fixed or removable implant treatment for the elderly.

References

- Engfors I, Ortop A, Jemt T. Fixed implant-supported prostheses in elderly patients: a 5-year retrospective study of 133 edentulous patients older than 79 years. *Clin Implant Dent Relat Res*. 2004; 6: 190-198.
- Isaksson R, Becktor JP, Brown A, Laurizohn C, Isaksson S. Oral health and oral implant status in edentulous patients with implant-supported dental prostheses who are receiving long-term nursing care. *Gerodontology*. 2009; 26: 245-249.
- Visser A, de Baat C, Hoeksema AR, Vissink A. Oral implants in dependent elderly persons: blessing or burden? *Gerodontology*. 2011; 28: 76-80.

4. Muller F, Barter S. ITI Treatment Guide Vol 9-Implant Therapy in the Geriatric Patient. 1st ed. Berlin: Quintessenz Verlags-GmbH. 2016.
5. Jackowski J, Andrich J, Käppeler H, Zöllner A, Jöhren P, Müller T. Implant-supported denture in a patient with Huntington's disease: interdisciplinary aspects. *Spec Care Dentist*. 2001; 21: 15-20.
6. Müller F, Duvernay E, Loup A, Vazquez L, Herrmann FR, Schimmel M. Implant-supported mandibular overdentures in very old adults: a randomized controlled trial. *J Dent Res*. 2013; 92: 154-160.
7. Faggion CM Jr. Critical appraisal of evidence supporting the placement of dental implants in patients with neurodegenerative disease. *Gerodontology*. 2016; 33: 2-10.
8. Cawood JI, Howell RA. A classification of the edentulous jaws. *Int J Oral Maxillofac Surg*. 1988; 17: 232-236.
9. McGarry TJ, Nimmo A, Skiba JF, Ahlstorm RH, Smith CR, Koumjian JH. Classification system of complete edentulism. *The American College of Prosthodontics J Prosthodont*. 1999; 8: 27-39.
10. Kimoto K, Garrett NR. Effect of mandibular ridge height on masticatory performance with mandibular conventional and implant-assisted overdentures. *Int J Oral Maxillofac Implants*. 2003; 18: 523-530.
11. Tanaka J, Hoshino K. A Prosthetic Design Guideline for Effective Usage of Magnetic Attachments-Application to Restorations Supported by Implants. *The Journal of the Japanese Society of Magnetic Applications in Dentistry*. 2003; 12: 10-25.
12. Portnoy RA, Aronson AE. Diadochokinetic syllable rate and regularity in normal and in spastic and ataxic dysarthric subjects. *J Speech Hear Disord*. 1982; 47: 324-328.
13. Folstein, MF Folstein, SE McHugh PR. "Mini-mental state". A practical method for grading the cognitive state of patients for the clinician. *Journal of Psychiatric Research*. 1975; 12: 189-198.
14. Reisberg B. Functional Assessment Staging (FAST): *Psychopharmacology Bulletin*. 1988; 24: 653-659.