

Clinical Image

Corrective Surgery and Laser ND-YAG

Bagui M^{1*}, Belha JK¹, Fajri L² and Sakout M¹¹Department of Dentistry, Military Hospital Mohammed V Rabat, Morocco²Department of Dentistry, Faculty of Dental Medicine, Rabat, Morocco***Corresponding author:** Bagui M, Department of Dentistry, Military Hospital Mohammed V, Hay Ryad BP 10100 Rabat, Morocco**Received:** September 20, 2021; **Accepted:** October 06, 2021; **Published:** October 13, 2021

Clinical Image

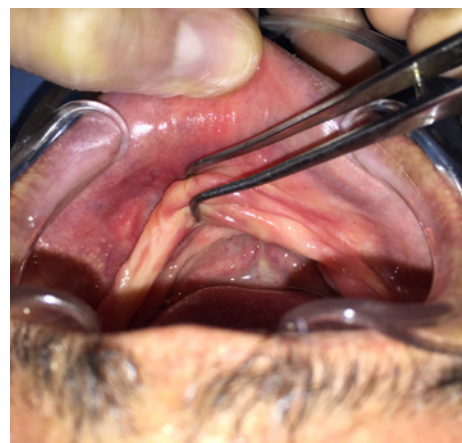
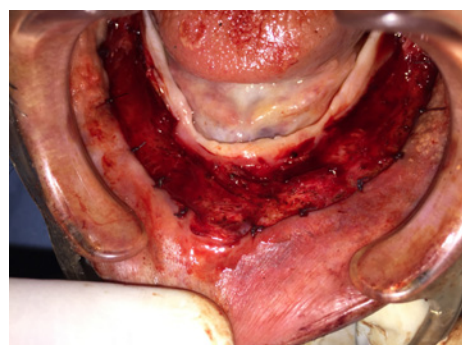
Epulis fissuratum is a mucosal hyperplasia that result from chronic irritation induced by a poorly fitting prosthesis. It is a pseudotumor sitting in the vestibule of the jaw; and composed of several layers.

This lesion impinges on the prosthetic balance and requiring a pre-prosthetic surgical time.

The extent of the hyperplasia in this case makes it impossible to take an accurate impression for performing a cicatrisation guiding prosthesis.

Total surgical excision of the lesion was performed followed by a subperiosteally vestibule extension.

At the final, an application of laser ND-YAG with the aim of coagulation, bio stimulation, limiting the post-operative consequences and fast healing (Figure 1 and 2).

**Figure 1:****Figure 2:**