

Clinical Image

Maxillary Midline and Other Deviations

Al-Murtadha R, El-Housseiny S, El-Beialy AR* and Heidar AM

Department of Orthodontics and Dentofacial Orthopedics, Cairo University, Egypt

*Corresponding author: Amr Ragab El-Beialy,

Department of Orthodontics and Dentofacial Orthopedics, Cairo University, Egypt

Received: March 28, 2016; Accepted: April 11, 2016;

Published: April 13, 2016

Abstract

Correction of the maxillary midline deviation is an important orthodontic objective. Identification of this deviation is sometimes complicated by the presence of deviation of other facial structures. This article provides a simple clinical tip that can aid in detecting the maxillary midline deviation.

Keywords: Orthodontics; Diagnosis; Clinical tip; Palatal papilla

Clinical Image

Orthodontists are keen observers of midline deviations [1]. They usually use the facial midline (constructed from glabella, nasion and the upper lip Cupid's bow) as a reference line to evaluate the maxillary midline [2]. However, extra oral landmarks may be misleading due to the presence of a variable degree of asymmetry in those facial structures, inaccuracy in identifying these points, or parallax during visualization of the points, thus leading to erroneous diagnosis. Clinical examination and intraoral photographs, which are fundamental tools for orthodontic diagnosis, can be valuable in this regard. When using a large intraoral mirror, or viewing the occlusal

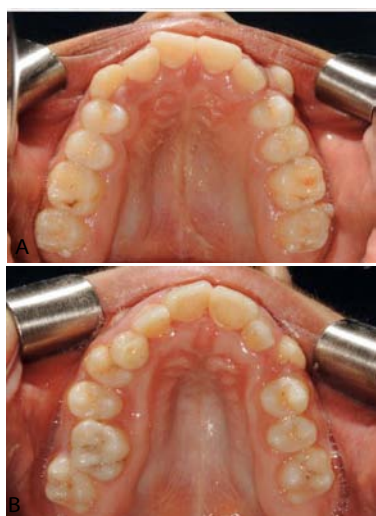

Figure 1A & 1B: Intraoral maxillary occlusal photograph showing the incisive papilla follows the direction of the deviation.

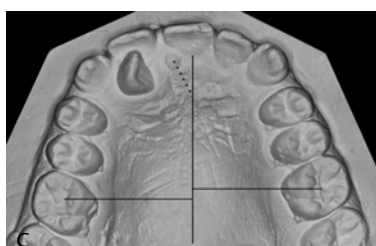


Figure 1C: Maxillary orthodontic model showing the incisive papilla follows the direction of the deviation.

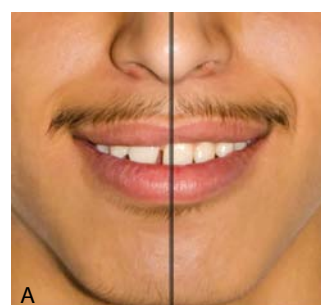


Figure 2A: Frontal facial photograph showing the maxillary midline deviation relative to facial midline.

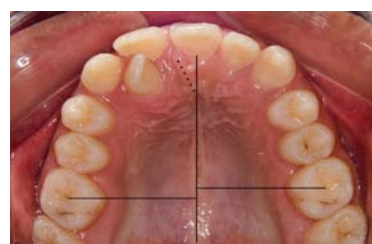

Figure 2B: Intraoral occlusal photograph showing the incisive papilla deviation relative to the midpalatal raphe prior to orthodontic treatment.

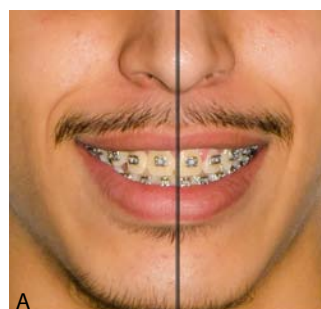


Figure 3A: Frontal facial photograph showing the correction of the maxillary midline deviation relative to facial midline.

photograph of the upper arch, a simple glance at the incisive papilla could be a guide to the existence and direction of the deviation-if any exists. As shown in (Figure 1A, 1B and 1C), the incisive papilla follows the direction of the deviation. The resolution of incisive

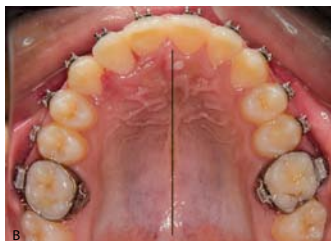

Figure 3B: Intraoral occlusal photograph showing the resolution of incisive papilla deviation after orthodontic correction of the dental midline shift.

papilla deviation following the orthodontic correction of the dental midline shift supports this assumption (Figures 2A, 2B & 3A, 3B).

References

1. Kokich VO, Kokich VG, Kiyak HA. "Perceptions of dental professionals and laypersons to altered dental esthetics: asymmetric and symmetric situations". *Am Orthod Dentofacial Orthop.* 2006; 130: 141-151.
2. Sabri R. "The eight components of a balanced smile". *J Clin Orthod.* 2005; 39: 155-167.