

Review Article

Topic: All-on-Four Concept Literature Review

Ramazan Isufi¹; Edit Xhajanka^{1*}; Anis Thodhorjani^{1,2};
Neada Hysenaj^{1,2}; Fatmir Lela¹; Silvana Bara¹; Renato
Isufi^{1,2}

¹Faculty of Dental Medicine, University of Medicine,
Tirana, Albania

²University Dental Clinic, Tirana, Albania

***Corresponding author: Edit Xhajanka**

Faculty of Dental Medicine, University of Medicine,
Tirana, Albania.

Email: edit.xhajanka@umed.edu.al

Received: November 16, 2023

Accepted: November 24, 2023

Published: December 01, 2023

Introduction

In patients with total edentulism, dental implant treatment is a treatment model which has been accepted scientifically, and with long-term outcomes [1,2]. Dental implants with immediate function by making implant-supported fixed full-arch restorations are becoming the gold standard in dental implantology [3-5]. Normally in literature successful prostheses are made using [6-8] implants in the maxilla and 6 implants in the mandible and applying posterior cantilever extension where it is necessary, in these treatments, hygiene controls can be easily performed especially in full arch screw-retained fixed prostheses [7-9].

In some cases maxillary sinuses for maxilla restricts the implant placement in the posterior region. The posterior implant treatment is also difficult in patients with resorbed mandible with a mandibular nerve located at the top of the alveolar crest. The all-on-four implant concept has been developed to prevent these disadvantages presented by Malo for the first time in 2003 and the all-on-four concept that began to be used in atrophic full arch mandibular and in the maxilla in 2005. In this technique implants are positioned in the pre-maxillary region in the maxilla and in the inter-foraminal region in the mandible. Anterior implants are placed to the lateral incisor sites or canine/first premolar region, posterior implants are placed to the second premolar or first molar region [12-16].

The fact that full arch screw-retained fixed prostheses and immediate dentures made on a total of 4 implants including two implants that are orthogonally placed to the occlusal plane in the anterior region and two implants that are placed in the

posterior region with a mesial angle of 30-45 grade in edentulous maxillary or mandibular jaws are constructed and immediately loaded (after a surgery of 8-48h), and the construction of permanent fixed prosthesis after a 3-month period constitute the basis of the all-on-four concept [21,22].

The fact that the distribution of the forces is biomechanically sufficient with 4 implants placed at right angles and positions, the use of longer implants for the posterior region ($\geq 13\text{mm}$) and accordingly increase in bone anchorage and placement in the correct biomechanical position, and ensuring high primary stability are regarded as the advantages of the all-on-four concept [29,30].

In implant supported dentures, general protocol is formed by placing implants parallel to the anterior maxilla and mandible. In implant-supported fixed dentures, masticatory forces are distributed evenly over the implants, and the loads to be on posterior cantilever extensions are shared on many anterior implants. For this purpose, it is aimed to distribute the loads by increasing the number of maxillary and mandibular anterior implants [31-33].

In literature are many researches articles about the all-on-four implant concept. Therefore, the purpose of this review is to summarize articles written about all-on-four, to make comparisons between them, to form the advantages and disadvantages of the method from the literature review, and to evaluate the all-on-four concept in terms of osseointegration and crestal bone resorption [35-37].

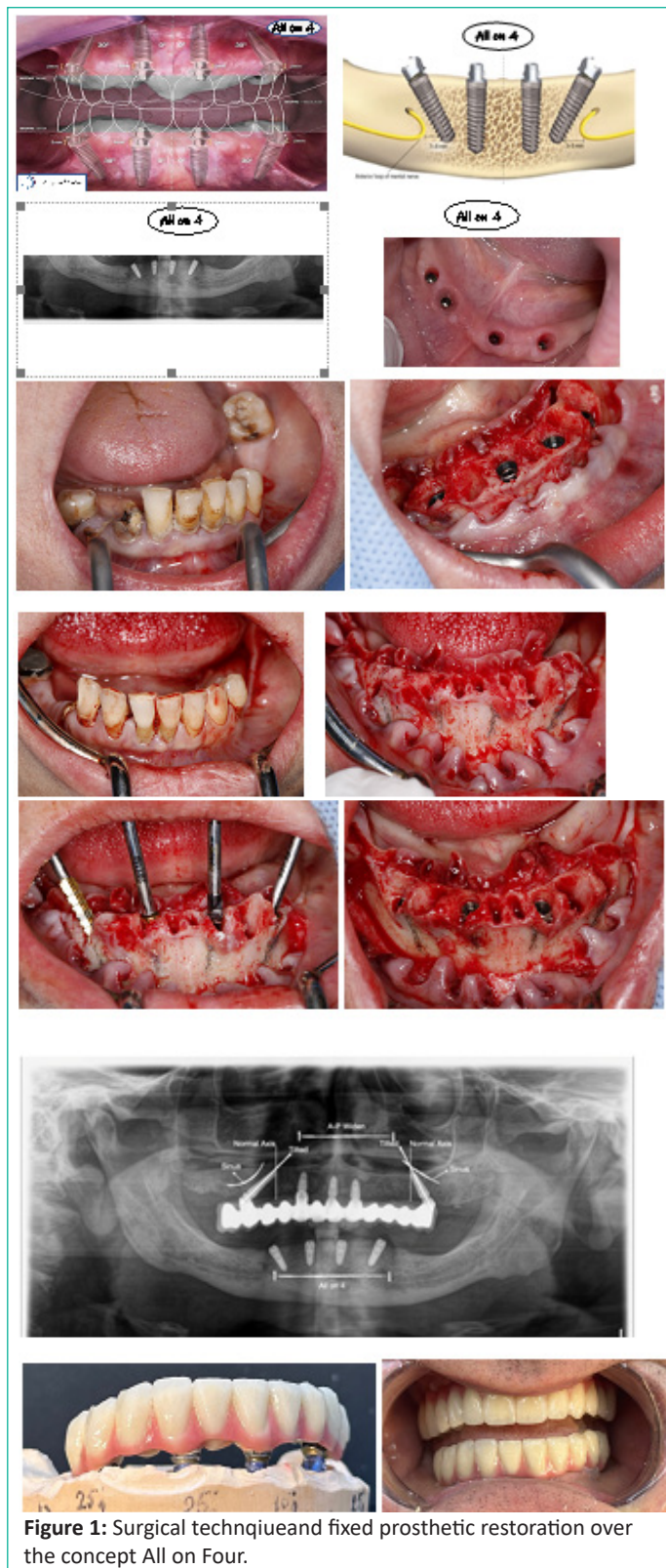


Figure 1: Surgical technique and fixed prosthetic restoration over the concept All on Four.

Material and Methods

In this review, studies involving maxilla and mandible applications of the current all-on-four technique, its advantages and disadvantages, surgical technique, antero-posterior spread and osseointegration and clinical survival rates were examined.

In the review performed in Pubmed and Cochrane Library between 2005 and 2023, Full arch implant-supported prosthesis, 4-implant full arc, osseointegration, inclined implant, total edentulism and different combinations in which some of these keywords were used together were chosen. 100 of the articles achieved from the review were evaluated with respect to the subject we examined.

The inclusion criteria for articles were as follows:

- 1-Articles were related to the all-on-four concept,
- 2-Abstracts were obtained when the full texts could not be obtained.

General Considerations for All on Four:

1. The first concern in all on four procedure is to achieve the primary stability of minimum 35Ncm up to maximum of 45 Ncm.
2. There should be minimum 5mm of bone width present in the implant placement site
3. Minimum of 10mm of bone height should be available from canine to canine region in the maxillary arch and 8mm in the mandibular edentulous arch.
4. Splinting of tilted implants can be done if the angulation of the implants placed is more than 30 degree.
5. In case of tilted implants placed in the posterior edentulous region, the access hole to the distal screw should be located at occlusal face of first molar, second premolar and on the first premolar [35-39].

Surgical Technique

Two distal implants were placed in the maxillary posterior edentulous region and these two implants are tilted anterior to the maxillary sinus, on the other hand in the mandibular arch, implants have been placed anterior to the mental foramen region. These implants should be inserted at an angulation ranging between 30 degree to 45 degree. Surgical guide help in ensuring the correct positioning of the implant. The surgical guide should be placed in the osteotomy in the Centre position of the maxilla and the mandible. A band should be constructed of titanium should be contoured to follow the arc of the opposite arch. The lines which are present over the surgical guide act as a reference for the drilling at correct angulation and that angulation over the surgical guide should be or must be not greater than 45 degree.

Angulated pins, dentures and templates can be used as an alternative for the surgical guide in the placement of implant at the implant site with proper angulation. Different abutments namely straight or 17 degree multiunit abutments and 30 degree angulated abutment with different height of collar should be placed over the implant to achieve relative parallelism so that the prosthesis should be seated easily and passively.

A study demonstrated survival rate of 93% at patient level and 98% at implant level after 5 year follow up [40,41].

The quality of bone, number of implants, length of implant being placed, patient systemic conditions, these all should be viewed accurately before under going for all on four surgical protocol.

The antero posterior spread of the implant and the stiffness of the prosthesis will result in reducing the bending of the implant, when implant itself is a part of multi implant supported prosthesis.

Shorter cantilever which results from more the distal position of the posterior implant helps in reducing the stress concentration values in the implant.

A study conducted by Krekmanov stated that, there is no significant differences found with respect to forces and bending movements in tilted implants and non tilted implants. A different study conducted by Bevilacqua et al revealed that, if the tilting of the distal implants done by 30 degree, results in decreasing the level of stress concentration by 52% in the compact bone and 47.6% in the cancellous bone when it is compared with fixed prosthesis supporting vertical implants along with longer cantilevers [47,48].

Splinted implants show less amount of stress concentration near the implants when compared with the axial implants. If the loading of the cantilever is done near the prosthesis or on the prosthesis, results in hinging effect that results in stress concentration on the implant, closet to the load application. If the length of the cantilever is excessive in distal cantilever it may lead to fracture of the screw or may lead to fracture of the whole framework. Prosthesis loaded with tilted implants does not show over loading or bending of the prosthesis, because the load was distributed to the supporting implants, the mesial implant and the distal implant through the prosthesis when the prosthesis is loaded.

A study evaluated the pattern on photo elastic strain around the distal most implant at 0 degree, 15 degree, 30 degree and at 45 degree. They found that there was no significant difference with respect to strain magnitude was found among different models of implants placed at 0 degree, 15 degree and 30 degree, but significant difference was found in case of implant placed at angulation of 45 degree with increase in strain pattern around the implant. Anteroposterior Spread According to Rangert the antero posterior spread of the prosthesis (the distance between the most anterior and most posterior implant) of 10 mm was proposed for a cantilever length of 20mm i.e. 2 x antero posterior spread. According to English the antero posterior length of cantilever in case of mandibular implant supported fixed prosthesis should be 1.5 time of the antero posterior spread. According to English this will provide 10 – 12mm of cantilever length in case of mandibular implant supported fixed prosthesis and in case of maxillary implant supported fixed prosthesis the cantilever length should be reduced to 6 – 8mm due to presence of low density bone in maxillary posterior region.

Multi unit impression coping of open tray is placed over the multi unit abutment, that was splinted with autopolymerising resin along with wire bars. This will ensure accurate transfer of the impression copings. An open tray impression is made with rigid polyvinyl siloxane material, to record the position of the implant along with soft tissue. After than the all acrylic provisional prosthesis is delivered to the patient, and was final torqued at 15Ncm. The patient is recalled after one week, than after 3 week and then after 3 months. At the end of 3rd month fabrication of the final prosthesis should be started [50].

Occlusal Scheme for Definitive Prosthesis for All on Four

1. There should be simultaneous bilateral contact present over cuspids and the posterior teeth with slight grazing contacts over the incisors.
2. In lateral movements, canine guidance should be given when opposing natural dentition is present.
3. Group function occlusion should be given when opposing implant supported bridge is present in posterior, flat linear pathways with minimal vertical imposition should be given.

4. If in case implant supported fixed prosthesis is occluding with removable partial denture, complete denture, cast partial denture or with implant supported over denture, the distal most tooth should remain slightly out of occlusion and in excursive movement, one or more balancing contact should be given.

5. The inclination of the cuspal planes, must be less than the condylar path inclinations.

Advantages:

1. Anatomical structure can be avoided by the use of angled implants in the posterior region.
2. Implants with longer dimensions can be anchored in the bone for better stability.
3. Span of the posterior cantilever is reduced.
4. Bone augmentation procedure can be avoided.
5. Immediate function
6. Better esthetics
7. Success rate is relatively higher
8. Economical, as number of implants are reduced.

Disadvantages

Length of the cantilever being given is limited and can not be extended beyond the limits. Very much technique sensitive, and requires pre surgical splint for the proper placement of implant at desired position and angulation [51-53].

Conclusion

Earlier the placement of dental implant in severely resorbed ridges of maxilla and mandible shows little success rate. But with the concept of All on Four the success rate is quite higher, while promising a treatment method of choice in severely compromised alveolar ridge cases.

Author Statements

Acknowledgements and Funding

We would like to express our sincere gratitude to the Ministry of Education and Sport of Albania, which, based on Order No. 468, dated 02.08.2022, for "Financing/Co-financing of Joint Projects in the Framework of Internationalization of Study Programs", financed the study and the project entitled "Evaluation of fixed metal-ceramics and all-ceramics implant supported restorations".

References

1. Ferreira EJ, Kuabara MR, Gulinelli JL. 'All-on-four' concept and immediate loading for simultaneous rehabilitation of the atrophic maxilla and mandible with conventional and zygomatic implants. *Br J Oral Maxillofac Surg.* 2010; 48: 218-20.
2. Misch CE. *Contemporary implant dentistry.* 3rd ed. Mosby: Elsevier. USA; 2008.
3. Balshi TJ, Wolfinger GJ, Slauch RW, Balshi SF. A retrospective analysis of 800 Brånemark System implants following the All-on-Four™ protocol. *J Prosthodont.* 2014; 23: 83-8.
4. Papaspyridakos P, Chen CJ, Chuang SK, Weber HP, Gallucci GO. A systematic review of biologic and technical complications with fixed implant rehabilitations for edentulous patients. *Int J Oral Maxillofac Implants.* 2012; 27: 102-10.

5. Malhotra AO, Padmanabhan TV, Mohamed K, Natarajan S, Elavia U. Load transfer in tilted implants with varying cantilever lengths in an All-on-Four situation. *Aust Dent J.* 2012; 57: 440-45.
6. Crespi R, Vinci R, Capparé P, Romanos GE, Gherlone E. A clinical study of edentulous patients rehabilitated according to the "all on four" immediate function protocol. *Int J Oral Maxillofac Implants.* 2012; 27: 428-34.
7. Maló P, Rangert B, Nobre MA. 'All-on-Four' immediate-function concept with Brånemark System implants for completely edentulous mandibles: A retrospective clinical study. *Clin Implant Dent Relat Res.* 2003; 5: 2-9.
8. Maló P, Rangert B, Nobre MA. All-on-4 immediate-function concept with Branemark System implants for completely edentulous maxillae: A 1-year retrospective clinical study. *Clin Implant Dent Relat Res.* 2005; 7: S88-94.
9. Agliardi E, Clericò M, Ciancio P, Massironi D. Immediate loading of full-arch fixed prostheses supported by axial and tilted implants for the treatment of edentulous atrophic mandibles. *Quintessence Int.* 2010; 41: 285-93.
10. Butura CC, Galindo DF, Jensen OT. Mandibular all-on-four therapy using angled implants: a three year clinical study of 857 implants in 219 jaws. *Dent Clin North Am.* 2011; 55: 795-811.
11. Asawa N, Bulbule N, Kakade D, Shah R. Angulated implants: an alternative to bone augmentation and sinus lift procedure: systematic review. *J Clin Diagnos Res.* 2015; 9: Z10-3.
12. Tealdo T, Bevilacqua M, Pera F, Menini M, Ravera G, Drago C, et al. Immediate function with fixed implant-supported maxillary dentures: a 12-month pilot study. *J Prosthet Dent.* 2008; 99: 351-60.
13. Capelli M, Zuffetti F, Del Fabbro M, Testori T. Immediate rehabilitation of the completely edentulous jaw with fixed prostheses supported by either upright or tilted implants: a multi center clinical study. *Int J Oral Maxillofac Implants.* 2007; 22: 639-44.
14. Menini M, Signori A, Tealdo T, Bevilacqua M, Pera F, Ravera G, et al. Tilted implants in the immediate loading rehabilitation of the maxilla: A systematic review. *J Dent Res.* 2012; 91: 821-7.
15. Graves S, Mahler BA, Javid B, Armellini D, Jensen OT. Maxillary all-on-four therapy using angled implants: A 16-month clinical study of 1110 implants in 276 jaws. *Oral Maxillofac Surg Clin North Am.* 2011; 23: 277-87.
16. Agliardi EL, Francetti L, Romeo D, Taschieri S, Del Fabbro M. Immediate loading in the fully edentulous maxilla without bone grafting: the V-II-V technique. *Minerva Stomatol.* 2008; 57: 251-63.
17. Calandriello R, Tomatis M. Simplified treatment of the atrophic posterior maxilla via immediate/early function and tilted implants: A prospective 1-year clinical study. *Clin Implant Dent Relat Res.* 2005; 7: S1-12.
18. Sorní M, Guarínós J, García O, Peñarrocha M. Implant rehabilitation of the atrophic upper jaw: a review of the literature since 1999. *Med Oral Patol Oral Cir Bucal.* 2005; 10: E45-56.
19. Block MS, Haggerty CJ, Fisher GR. Non grafting implant options for restoration of the edentulous maxilla. *J Oral Maxillofac Surg.* 2009; 67: 872-81.
20. Del Fabbro M, Ceresoli V. The fate of marginal bone around axial vs. tilted implants: a systematic review. *Eur J Oral Implantol.* 2014; 7: S171-89.
21. Cidade CP, Pimentel MJ, Amaral RC, Nóbilo MA, Barbosa JR. Photoelastic analysis of all-on-four concept using different implants angulations for maxilla. *Braz Oral Res.* 2014; 28: 1-7.
22. Krekmanov L, Kahn M, Rangert B, Lindström H. Tilting of posterior mandibular and maxillary implants for improved prosthesis support. *Int J Oral Maxillofac Implants.* 2000; 15: 405-14.
23. Maló P, Nobre A, Petersson U, Wigren S. A pilot study of complete edentulous rehabilitation with immediate function using a new implant design: case series. *Clin Implant Dent Relat Res.* 2006; 8: 223-32.
24. Babbush CA, Hahn JA, Krauser JT, Rosenlicht JL. The All on Four concept. In: *Dental implants: the art and science.* 2nd ed. St Louis: Saunders Elsevier. USA; 2011.
25. Van Lierde KM, Browaeys H, Corthals P, Matthys C, Mussche P, Van Kerckhove E, et al. Impact of fixed implant prosthetics using the "all-on-four" treatment concept on speech intelligibility, articulation and oromyo functional behavior. *Int J Oral Maxillofac Surg.* 2012; 41: 1550-7.
26. Gherlone EF, Ferrini F, Crespi R, Gastaldi G, Capparé P. Digital impressions for fabrication of definitive "all-on-four" restorations. *Implant Dent.* 2015; 24: 125-9.
27. Spinelli D, Ottria L, De Vico G, Bollero R, Barlattani A, Bollero P. Full rehabilitation with nobel clinician(®) and procera implant bridge(®): case report. *Oral Implantol.* 2013; 6: 25-36.
28. Ehsani S, Siadat H, Alikhasi M. Comparative evaluation of impression accuracy of tilted and straight implants in All-on-Four technique. *Implant Dent.* 2014; 23: 225-30.
29. Dellavia C, Francetti L, Rosati R, Corbella S, Ferrario VF, Sforza C. Electromyographic assessment of jaw muscles in patients with All-on-Four fixed implant-supported prostheses. *J Oral Rehabil.* 2012; 39: 896-904.
30. Malo P, de Araujo Nobre M, Lopes A. The use of computer guided flapless implant surgery and four implants placed in immediate function to support a fixed denture: preliminary results after a mean follow-up period of thirteen months. *J Prosthet Dent.* 2007; 97: S26-34.
31. Zampelis A, Rangert B, Heijl L. Tilting of splinted implants for improved prosthodontic support: A two-dimensional finite element analysis. *J Prosthet Dent.* 2007; 97: S35-43.
32. Mupparapu M, Singer SR. Implant imaging for the dentist. *J Can Dent Assoc.* 2004; 70: 32.
33. Hassine MBH, Bucci P, Gasparro R, Lauro AED, Sammartino G. Safe approach in "All-on-four" technique: A case report. *Ann Stomatol (Roma).* 2015; 5: 142-5.
34. Babbush CA. Post-treatment quantification of patient experiences with full-arch implant treatment using a modification of the OHIP 14 questionnaire. *J Oral Implantol.* 2012; 38: 251-60.
35. Babbush CA, Kanawati A, Kotsakis GA. Marginal bone stability around tapered, platform-shifted implants placed with an immediately loaded four-implant-supported fixed prosthetic concept: A cohort study. *Int J Oral Maxillofac Implants.* 2016; 31: 643-50.
36. Babbush CA, Kanawati A, Kotsakis GA, Hinrichs JE. Patient-related and financial outcomes analysis of conventional full-arch rehabilitation versus the All-on-4 concept: A cohort study. *Implant Dent.* 2014; 23: 218-24.
37. Bellini CM, Romeo D, Galbusera F, Taschieri S, Raimondi MT, Zampelis A, et al. Comparison of tilted versus nontilted implant-supported prosthetic designs for the restoration of the edentulous mandible: A biomechanical study. *Int J Oral Maxillofac Implants.* 2009; 24: 511-7.

38. Bellini CM, Romeo D, Galbusera F, Agliardi E, Pietrabissa R, Zampelis A, et al. A finite element analysis of tilted versus nontilted implant configurations in the edentulous maxilla. *Int J Prosthodont*. 2009; 22: 155-7.
39. Hussein MO, Rabie ME. Three-dimensional nonlinear contact finite element analysis of mandibular all-on-four design. *J Oral Implantol*. 2015; 41: e12-8.
40. Khatami AH, Smith CR. 'All-on-Four' immediate function concept and clinical report of treatment of an edentulous mandible with a fixed complete denture and milled titanium framework. *J Prosthodont*. 2008; 17: 47-51.
41. Babbush CA, Kanawati A, Brokloff J. A new approach to the All-on-Four treatment concept using narrow platform Nobel Active implants. *J Oral Implantol*. 2013; 39: 314-25.
42. Wiltfang J, Schultze-Mosgau S, Nkenke E, Thorwarth M, Neukam FW, Schlegel KA. Onlay augmentation versus sinus lift procedure in the treatment of the severely resorbed maxilla: A 5-year comparative longitudinal study. *Int J Oral Maxillofac Surg*. 2005; 34: 885-9.
43. Dellavia C, Rosati R, Del Fabbro M, Pellegrini G. Functional jaw muscle assessment in patients with a full fixed prosthesis on a limited number of implants: a review of the literature. *Eur J Oral Implantol*. 2014; 7: S155-69.
44. Bevilacqua M, Tealdo T, Pera F, Menini M, Mossolov A, Drago C, et al. Three-dimensional finite element analysis of load transmission using different implant inclinations and cantilever lengths. *Int J Prosthodont*. 2008; 21: 539-42.
45. Takahashi T, Shimamura I, Sakurai K. Influence of number and inclination angle of implants on stress distribution in mandibular cortical bone with All-on-four Concept. *J Prosthodont Res*. 2010; 54: 179-84.
46. Correa S, Ivancik J, Isaza JF, Naranjo M. Evaluation of the structural behavior of three and four implant-supported fixed prosthetic restorations by finite element analysis. *J Prosthodont Res*. 2012; 56: 110-9.
47. Patzelt SB, Bahat O, Reynolds MA, Strub JR. The all-on-four treatment concept: A systematic review. *Clin Implant Dent Relat Res*. 2014; 16: 836-55.
48. Babbush CA, Kutsko GT, Brokloff J. The all-on-four immediate function treatment concept with Nobel Active implants: a retrospective study. *J Oral Implantol*. 2011; 37: 431-45.
49. Mozzati M, Arata V, Gallesio G, Mussano F, Carossa S. Immediate post extraction implant placement with immediate loading for maxillary full-arch rehabilitation. A two-year retrospective analysis. *J Am Dent Assoc*. 2012; 143: 124-33.
50. Francetti L, Agliardi E, Testori T, Romeo D, Taschieri S, Del Fabbro M. Immediate rehabilitation of the mandible with fixed full prosthesis supported by axial and tilted implants: interim results of a single cohort prospective study. *Clin Implant Dent Relat Res*. 2008; 10: 255-63.
51. Francetti L, Romeo D, Corbella S, Taschieri S, Del Fabbro M. Bone level changes around axial and tilted implants in full-arch fixed immediate restorations. Interim results of a prospective study. *Clin Implant Dent Relat Res*. 2012; 14: 646-54.
52. Francetti L, Corbella S, Taschieri S, Cavalli N, Del Fabbro M. Medium- and Long-term complications in Full-Arch Rehabilitations Supported by Upright and Tilted Implants. *Clin Implant Dent Relat Res*. 2015; 17: 758-64.
53. Nocini PF, Albanese M, Castellani R, Zanotti G, Canton L, Bissoletti G, et al. Application of the "all-on-four" concept and guided surgery in a mandible treated with a free vascularized fibula flap. *J Craniofac Surg*. 2012; 23: e628-31.