

Research Article

A Non-Surgical Root Separation and/or Resection for the Treatment of Advanced Furcation Involved Molars - A Longitudinal Study for 5-18.5 Years

Hou GL*

Graduate Institute of Dental Science, Department of Periodontal Prosthesis, School of Dental Medicine, Kaohsiung Medical University, Kaohsiung, Taiwan and Periodontal-Prosthetic Therapeutic Center & Periodontal Dept, Chang Gung Memorial Hospital, Kaohsiung Medical Center, Taiwan

***Corresponding author:** Guey-Lin Hou, Graduate Institute of Dental Science, Department of Periodontal Prosthesis, School of Dental Medicine, Kaohsiung Medical University, Kaohsiung, Taiwan and Periodontal-Prosthetic Therapeutic Center & Periodontal Dept, Chang Gung Memorial Hospital, Kaohsiung Medical Center, Taiwan

Received: October 10, 2020; **Accepted:** November 02, 2020; **Published:** November 09, 2020

Abstract

Although, the treatment of angular defects in molars with guided tissue regeneration, emdogain has been reported and has exhibited significant and predictable results; but, it has, however, afforded very limited and less predictable results in the treatment of advanced class II and III maxillary furcation defects. Therefore, the majority of root resection procedures are commonly recommended for treating advanced molar furcation, in particular located at molars with class III furcation involvement. There is still some controversy regarding the results among different investigators who evaluated the long-term prognosis after treatment modalities.

In general, the root resection procedure is a surgical approach for simultaneously performing a periodontal flap operation at first and followed by the amputation and/or resection of maxillary molar root(s). There are some complications and disadvantages, such as post-operative pain and bleeding, swelling, infection, following surgical root resection and/or resection. Little or no report regarding the use of non-surgical Root Resection and Separation (RSR) in the treatment of molars with advanced class II and III furcation involvements is available. The purpose of this report is to details a non-surgical Root Separation and/or Resection (RSR) procedure following Therapeutic Provisional Prosthesis (TPP) for the treatment of advanced class II and III furcation-Involved molars. In addition, evidenced-based clinical trials of retrospective and longitudinal data were also prescribed here.

Keywords: Root resection; Root separation; Scaling

Introduction

The longitudinal observations of the various studies have evaluated the different treatment modalities of molars with advanced furcation involvement using Scaling and Root Planning (SRP), traditional flap operation with and/or without bone grafts, root resection techniques, regeneration therapy with and without GTR, obturation therapy with bio-adhesive materials, and growth factor's therapy. However, each of their reports exhibits some great discrepancies for the long-term evaluation of subsequent complications, which are susceptible to failure and eventually requiring extraction. Although, root resection procedures are most commonly recommended for treating advanced molar Furcation Involvement (FI), in particular located at molars with Class III FI, there is still some controversy regarding the results among different investigators who evaluated the long-term prognosis after different treatment modalities. [1-7]. The majority of the discrepancies center around the complications, such as root caries, root fracture, recurrent invasion of FI, incomplete personal and/or professional plaque control over the residual root concavity, [7] narrow Furcation Entrance Dimension (FED), [8-10] long root trunk [11-13], and extraction [14,15]. Although, the treatment of angular defects in molars with using guided tissue regeneration has been reported and has exhibited significant and predictable results at the mandibular molars with Class II FI; [16-18] it has, however,

afforded very limited and less predictable results in the treatment of Class II and III maxillary furcation defects [19-21]. Müller et al. [1] documented that about 44% of molars with Class III were extracted after periodontal surgery, irrespective of recall visits and subgingival scaling. They also concluded that the decision for selecting a treatment modality appears to depend on the degree of molar FI as well as tooth type. Therefore, conclusions indicated that the success rate of treatment modalities seems to depend essentially on the class of molar FI and root morphology, irrespective of the operator's skill, and severity of the periodontal disease [1,6,19,20,22].

Leon and Vogel found that ultrasonic debridement was more effective than hand scaling in class II and III molar FIs at reducing spirochetes and motile rods [23]. They speculated that curettes (width of working ends between 0.75 mm~1.1 mm) did not negotiate the furcal roof as well as ultrasonic tips (width means = 0.56 mm). In addition, some other studies also suggested roof size discrepancy of furcation entrance less than 0.75 mm could preclude effective debridement [8-13].

In monitoring above-mentioned viewpoints, such as the degree of molar FI, narrow furcal roof size, and limited and less predictable results for maxillary molar FI, the research for alternative methods to treat molars with advanced furcation lesions is necessary. Therefore, Root Resection and/or Separation (RSR) seem to be a

better effective measure than conventional periodontal surgeries or other regenerative procedures to solve the high risk problem of inaccessible furcations. A recent longitudinal study, presented by Hou et al. [6] on the treatment of advanced molar FIs, that employing the CSCTD as the removable periodontal prosthesis, has confirmed the fact that a remarkable improvement in periodontal parameters has been documented in molars with RSR as compared to those without RSR. This study strongly suggested that the use of CSCTD, removable periodontal prosthetic design following RSR appears to be suitable for treatment of molars with advanced FI with anatomical problems, such as narrow FED and long root trunk, related to high risk of periodontally-diseased molars.

Although, surgical root resection procedure is most recommended as a combined technique of root resection and/or amputation following the flap operation, but limited or no report regarding the use of non-surgical RSR in the treatment of molars with advanced class II and III molar FIs is available.

The purpose of this report is to detail a new method using non-surgical RSR procedure for the treatment of advanced furcation-involved molars, particularly in advanced class II and III molar FI lesions. In addition, evidenced-based clinical trials of retrospective and longitudinal data were also prescribed here.

Materials and Methods

The present article is one of extension of our serial study on the field of periodontal prosthetic therapy for the treatment of individuals with Severely Advanced Periodontitis (SAP, alveolar bone loss > 60%). The present study was based on a retrospective analysis from 26 patients, with a total of 78 teeth affected SAP and STFO during 1980 and 2000, were selected from Kaohsiung Medical University, School of Dental Medicine, Graduate Institute of Dental Sciences. Teeth consisted of both test group (36 teeth with RSR) and control group (42 teeth without RSR). The teeth with SAP and STFO treated using both TPP, NSPT, and RSR were signed as the test group (36 teeth), while the teeth involving SAP and STFO, treated using NSPT only, and were signed as the control group (without RSR). The mean age of the samples was 34.4 ± 6.4 - 64.3 ± 3.8 years. Record reviews confirmed that the total samples received TPP, NSPT, and CSCTD presented from 5.1 years to 18.5 years with a mean 11.8 ± 7.6 years.

Those patients who exhibited advanced classes II and III furcation defects at maxillary and/or mandibular molars with severely alveolar bone loss over 60% were initially polled for samples. Informed consent was obtained from twenty-six patients [26], with molars affected one or more advanced II & III furcation lesions, which accepted for treatment of molar FIs using non-surgical RSR procedure. No molar teeth of individuals were excluded from the present study.

The clinical examination of periodontal parameters conducted on the molars included Gingival Index (GI), Plaque Index (PII), periodontal probing depth, molar FI classification, [13] horizontal and vertical Clinical Attachment Levels (CAL: the distance in mm between the CEJ and apical end of the probing depth) at furcation sites, molar crown and root mobility recorded for six sites on each tooth surface, following, and 1 year post-nonsurgical RSR procedure follow-up. The removable TPP were fabricated not only for splinting the molars affected furcation lesions, but also for stabilizing the

separated and/or resected roots. Other additional advantages included easier cleaning at complete open space of furcation roof for personal plaque control by patient at home as well as for professional plaque control by clinician in when removable TPP was removed from the molars with non-surgical RSR sites.

Measurements

For each periodontal parameters analyzed, the GI, PII, periodontal probing depth, molar FI classification, horizontal and vertical clinical attachment levels at furcation sites, molar crown and root mobility for six sites on each tooth surface were calculated using statistical analysis. The differences were analyzed using two-sample t test. The means and standard deviations of HCAL and VCAL for each different score were also analyzed.

A statistical program was used for the statistical analysis of the periodontal parameters at each treatment group. The two-sample t test was used to compare the mean scores of all calculated clinical parameters from the baseline to those after 1 to 5 years for each treatment group. Comparison between the treatments groups at baseline and after 1 to 5 years were also analyzed using the paired t test. The significant level was set at 0.05.

Oral Hygiene Program

For 4 weeks prior to treatment, all patients were enrolled in an oral hygiene program and recalled for reinforced OHI at one- to bi-weekly appointments for personal plaque control by patient, as well as professional plaque control by clinician.

Clinical Procedures of Non-Surgical RSR

- Figure 1** shows that the flower charts of teeth with SAP, STFO, and molar Furcation-Involvement (FI) were treated using TPP, non-surgical root separation (RSR) and CSCTD procedures.
- Figure 2** demonstrates cross-sectional view of maxillary molar with RSR. A Cross section of maxillary molar root was performed in mesio-distal, mesio-palatal, and disto-palatal directions.
- Figures 3a** Maxillary root separation with inner crowns; **Figures 3b** CSC- telescopic denture.
- Figure 4** shows the longitudinal view of mandibular molar with RSR.
- Figure 5** Mandibular first molar with root separation after application Inner crown and second molar with inner crown using outer removable telescopic denture.

Results

Table 1 showed the differences of Radiographic Alveolar Bone Loss (RABL, mm) in the molar abutment with RSR (test group) and without RSR (control group) using routine periodontal therapy. The mean (SD; mm) of mesial surface of RABL on the molar tooth of treated group (with RSR) was $1.21 (\pm 1.08)$ mm as compared to the untreated group (without RSR) were $-3.15 (\pm 1.42)$ mm, respectively. The differences of RABL in the distal surface of the molar of treated group (with RSR) were $0.78 (\pm 1.67)$ mm as compared to that of the untreated group (without RSR) was $-3.31 (\pm 2.47)$ mm, respectively. Results indicated that the radiographic bone gains $+1.21 (\pm 1.08)$ mm and $0.78 (\pm 1.67)$ mm in both of the mesial and distal surfaces in the treated group (with RSR) of the molar tooth are greater than

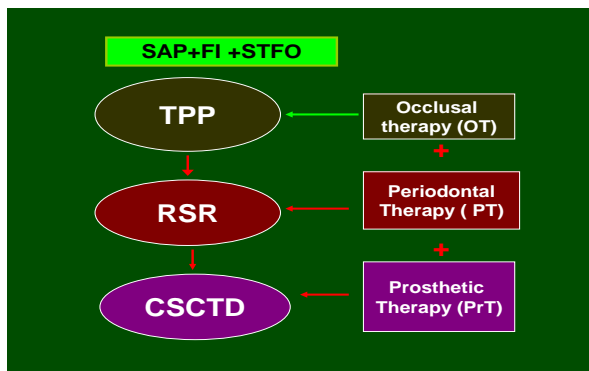


Figure 1: Shows that the flower charts of teeth with SAP, STFO, and molar furcation involvement were treated using TPP, non-surgical Root Separation (RSR) and CSCTD procedures.

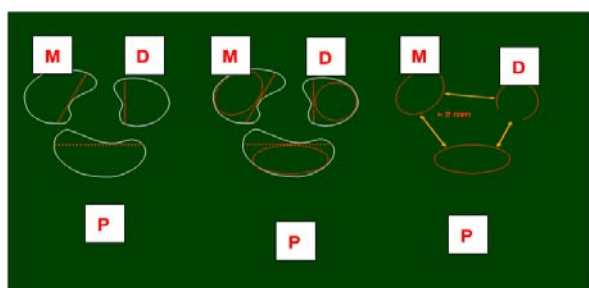
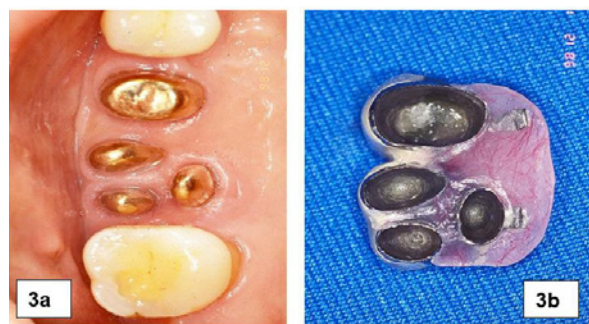

Figure 2: Demonstrates cross view of maxillary molar with RSR. A Cross section of maxillary molar root was performed in Mesio-Distal (MD), Mesio-Palatal (MP), and Disto-Palatal (DP) directions.



Figures 3: 3a) Maxillary root separation with inner crowns; Figures 3b) CSC-telescopic denture.

that of the untreated group (without RSR) with a loss of 3.15(±1.42) mm and 3.31(±2.47) mm, and both mesial and distal surfaces show a statistical significance of $p < 0.05$ and $p < 0.001$ between the treated and untreated group, respectively.

Table 2 demonstrated that the differences of radiographic alveolar bone loss (RABL, %) in the molar abutment with RSR and without RSR using routine periodontal therapy. The mean (SD; mm) of mesial surface of RABL on the molar tooth of treated group (with RSR) was 8.60(±7.11)% as compared to the untreated group (without RSR) were -21.38(±9.31)%, respectively. The differences of RABL in the distal surface of the molar of treated group (with RSR) were 7.04(±5.20) % as compared to that of the untreated group (without

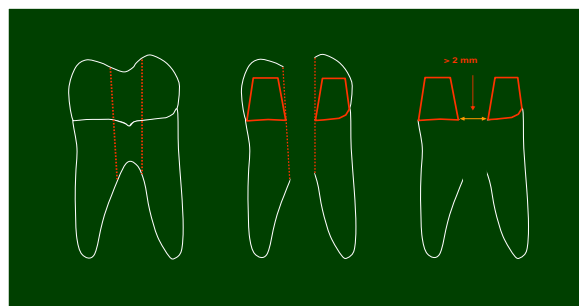


Figure 4: Shows the longitudinal view of mandibular molar with RSR.

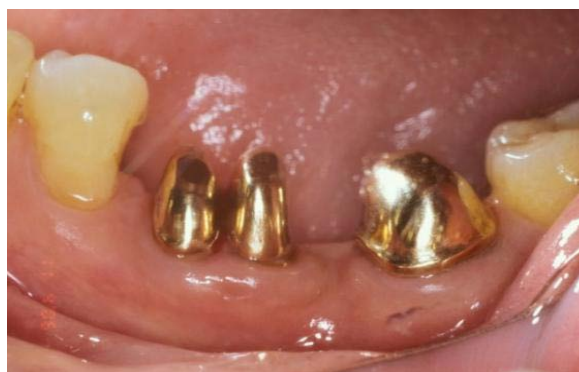

Figure 5: Mandibular first molar with root separation after application inner crown and second molar with Inner crown using outer removable telescopic denture.

Table 1: Showed the differences of radiographic alveolar bone loss (RABL, mm) in the molar abutment with RSR (test group) and without RSR (control group) using routine periodontal therapy (PP+NSPT+ RSR).

Molar Tooth	Treated group		Untreated group		F-value	significance
	RABL(mm) n	Mean (SD)	RABL(mm) n	Mean (SD)		
Mesial surface Range	1.21 (±1.08) 12	(-2.73~+4.31)	-3.15 (±1.42) 7	(-3.88~+1.20)	5.9928	$P < 0.05$ S*
Distal surface Range	0.78 (±1.67) 12	(-2.06~+2.91)	-3.31 (±2.47) 7	(-7.15~+0.06)	18.6869	$P < 0.001$ S***

Treated group: (Range: 5 - 18.5 years ; Mean(SD) = 11.58 (6.06) yrs.
 Untreated group: (Range: 4.5 - 9.5 years; Mean (SD) = 6.38 (1.88 yrs).

Table 2: Demonstrated that the differences of radiographic alveolar bone loss (RABL, %) in the molar abutment with RSR (test group) and without RSR (control group) using routine periodontal therapy.

Molar Tooth	Treated group		Untreated group		F-value	Significance
	RABL(%) n	Mean (SD)	RABL(%) n	Mean (SD)		
Mesial surface Range	8.60 (±7.11) 12	(-15.66~+45.45)	-21.38 (±9.31) 7	(-91.06~+1.20)	6.5478	$P < 0.05$
Distal surface Range	7.04 (±5.20) 12	(-17.35~+21.73)	-28.24 (±6.81) 7	(-68.56~+0.06)	16.9685	$P < 0.001$

RSR) was -28.24(±6.81) %, respectively. Results indicated that the radiographic bone gains +8.60(±7.11) % and 7.04(±5.20)% in both of the mesial and distal surfaces in the treated group (with RSR) of the molar tooth are greater than that of the untreated group (without RSR) with a loss of 21.38(±9.31)% and 28.24(±6.81)%.

The differences of RABL in the distal surface of the molar of treated group (with RSR) were 7.04(±5.20) % as compared to that of

the untreated group (without RSR) was $-28.24(\pm 6.81)$ %, respectively. Results indicated that the radiographic bone gains $8.60(\pm 7.11)$ % and $7.04(\pm 5.20)$ % in both of the mesial and distal surfaces in the treated group (with RSR) of the molar tooth are greater than that of the untreated group (without RSR) with a loss of $-21.38(9.31)$ % and $-28.24(\pm 6.81)$ %. There exists a statistical significance of both mesial ($p < 0.05$) and distal ($p < 0.001$) surfaces between the treated group (with RSR) and untreated group (without RSR), respectively.

Discussion

Provisional crown has been recommended as one of Therapeutic Periodontal Prosthesis (TPP) in the treatment of advanced periodontitis with guarded prognosis [6,24].

The majority of the discrepancies focused on the high prevalence of complications, such as root morphology, root fracture, recurrent invasion of Furcation Involvement (FI), incomplete plaque control over the residual root concavity, and treatment modalities. In addition, some studies [1,9,12,6,25] reported that factors such as anatomy and bony defects size between the bone and tooth, and amount and dimension of remaining periodontal tissues close to the defect are also important. However, these has more literatures related to the treatment of the abutments affected SAP with STFO using Surgical Periodontal Therapy (SPT) and combined SPT with GTR.

The longitudinal observations of the various studies have evaluated the different treatment modalities of molars with advanced furcation involvement using Scaling and Root Planning (SRP), traditional flap operation with and/or without bone grafts, root resection techniques, regeneration therapy with and without GTR, obturation therapy with bio-adhesive materials, and growth factor's therapy. However, each of their reports exhibits some great discrepancies for the long-term evaluation of subsequent complications, which are susceptible to failure and eventually requiring extraction. Although, the treatment of angular defects in molars with using guided tissue regeneration has been reported and has exhibited significant and predictable results at the mandibular molars with Class II FI; [16-18] it has, however, afforded very limited and less predictable results in the treatment of Class II and III maxillary molar furcation defects [19-21].

It has been determined that most favorable modality in periodontal therapy is the removal of all deposits on root surfaces exposed by advanced periodontal disease [1-3]. The prosthetic design provides some advantages, including stabilizing hypermobile abutments, easy plaque control, decrease torque force, and reduce leveling for ce on the weak abutments affected SAP with STFO [6,10,11,24].

The majority of the discrepancy focused on the high prevalence of complications, such as root morphology, root fracture, recurrent invasion of Furcation Involvement (FI), incomplete plaque control over the residual root concavity, and treatment modalities. In addition, some studies [1,6,9,12] reported that factors such as anatomy and bony defects size between the bone and tooth, and amount and dimension of remaining periodontal tissues close to the defect are also important. However, these has more literatures related to the treatment of the abutments affected SAP with STFO using Surgical Periodontal Therapy (SPT) and combined SPT with GTR.

Although, there still have many literatures associated with treatment of less periodontal bony support using the CSC retainers,

but most of the published data related to the successful treatment are limited on the case reports [24]. More recent literatures indicated a remarkable improvement in the periodontal parameters in advanced Class II and Class III molar FIs with RSR as compared to those without RSR. Little or no report associated with the longitudinal study on the survival rate of teeth as the abutments of CSCTD restoration in patient affected SAP with STFO. Present study seems to be the first report to explore and, retrospective to evaluate the survival rate of a treatment option using a conservative periodontal therapy, combined with the CSCTD restoration.

The present study showed that clinical assessments of periodontal parameters using TPP, NSPT, RSR, and CSCTD restoration design revealed a remarkable soft and hard periodontal healing in both anterior and posterior abutments. Additionally, periapical radiographs presented complete repair of bony defects by bone fills, and reappearance of the lamina dura surrounding periodontal areas.

References

- Muller HP, Eger T, Langer DE. Management of fraction-involved teeth-A retrospective analysis. *J Clin Periodontol.* 1995; 22: 911-917.
- Hamp SE, Nyman S, Lindhe J. Periodontal treatment of mulrooted teeth. Results after 5 years. *J Clin Periodontol.* 1975; 2: 126-135.
- Little LA, Beck FM, Bagci B, Horton JE. Lackof furcal bone loss follow- ing the tunneling procedure. *J Clin Periodontol.* 1995; 22: 637- 641.
- Hellden LB, Elliot A, Steffensen B, Steffensen JE. The prognosis of tunnel preparations in treatment of class III furcations. A follow-up study. *J Periodontol.* 1989, 60: 182-187.
- Hamp SE, Nyman S. Treatment of furcation-involved teeth. In: Text- book of Clinical Periodontology, 2nd edn. Lindhe J. 1989: 515 - 533.
- Hou GL, Tsai CC, Weisgold AS. Treatment of molar furcation involve- ment using root separation and a crown and sleeve-coping telescopic denture. A longitudinal study. *J Periodontol.* 1999; 70: 1098-1109.
- Bowers RC. Furcation morphology relative to periodontal treatment: Furcation root surface anatomy. *J Periodontol.* 1979; 50: 366-374.
- Bowers RC. Furcation morphology relative to periodontal treatment: Furcation entrance architecture. *J Periodontol.* 1979; 50: 23-27.
- Hou GL, Chen SF, Tsai CC. Furcation entrance dimension, divergent angle, and length of CEJ to furcation entrance relate to periodontal therapy. *Kaohsiung J Med Sci.* 1996, 12: 707-715.
- Hou GL, Chen SF, Wu YM, Tsai CC. The topography of the furcation entrance in Chinese molars. Furcation entrance dimensions. *J Clin Periodontol.* 1994; 21: 451-456.
- Hou GL, Chen SF, Wu YM, Tsai CC. The morphology of root fusion in Chinese adults (I) Grades, types, location, and distribution. *J Clin Periodontol.* 1994; 21: 231-236.
- Hou GL, Tsai CC, Huang JS. Relationship between molar root fusion and localized periodontitis. *J Periodontol.* 1997; 68: 313-319.
- Hou GL, Cheng YU, Tsai CC, Weisgold AS. A new classification of molar furcation involvement based on the root trunk and horizontal and vertical bone loss. *Inter J Periodontal & Restorative Dentistry.* 1998, 18: 257-265.
- Hirshfeld L, Wasserman B. A long-term survey of tooth loss in 600 treated periodontal patients. *J Periodontol.* 1978; 49: 225-237.
- Ross FI, Thompson RH. Furcation involvement in maxillary and mandibular molars. *J Periodontol.* 1980; 51: 450-454.
- Yukna RA. Clinical human comparison of expanded polytetra- fluoroethylene barrier membrane and freeze-dried dura mater allo- grafts for guide tissue regeneration of lost periodontal support. I. Mandibular molar Class II furcations. *J Periodontol.* 1992; 63: 431- 442.

17. Pontiriero R, Lindhe J, Nyman S, Karring T, Rosenberg E, Sanavi F. Guided tissue regeneration in degree II furcation-involved mandibular molars. A clinical study. *J Clin Periodontol.* 1988; 15: 247-254.
18. Pontiriero R, Lindhe J, Nyman S, Karring T, Rosenberg E, Sanavi F. Guided tissue regeneration in the treatment of furcation defects in mandibular molars. A clinical study of degree III involvement. *J Clin Periodontol.* 1989, 16: 170-174.
19. Pontiriero R, Lindhe J. Guided tissue regeneration in the treatment of degree II furcations in maxillary molars. *J Clin Periodontol.* 1995; 22: 756-763.
20. Pontiriero R, Lindhe J. Guided tissue regeneration in the treatment of degree III furcations in maxillary molars. *J Clin Periodontol.* 1995; 22: 810-812.
21. Metzler DG, Seamons BC, Mellonig JT, Gher ME, Gary JL. Clinical evaluation of guided tissue regeneration in the treatment of maxillary class II molar furcation invasions. *J Periodontol.* 1991; 62: 353-360
22. Hou GL, Hung CC, Tsai CC, Weisgold AS. Topographic study of root trunk type on Chinese molars with Class III furcation involvements: Molar type and furcation site. *Intern J Periodontal & Restorative Dent.* 2005; 25: 172-179.
23. Leon L, Vogel R. A comparison of the effectiveness of hand scaling and ultrasonic debridement in furcations as evaluated by differential darkfield microscopy. *J Periodontol.* 1987, 58: 86-94.
24. Yalisove IL. Crown and sleeve-coping retainers for removable partial denture. *J prosthet Dent.* 1966; 16: 1069-1085.
25. Hou, GL, Hou, LT. Therapeutic outcomes using the Sandwich's technique in treating severe advanced periodontitis with secondary occlusal trauma: A long-term study for 5.1-39 years. *Intern J Dent and Oral Health.* 2019; 5: 64-73.