

## Case Report

# Oral Lipoma in the Buccal Mucosa: Case Report and Literature Review

**Garcia-Blanco M\* and Puia SA**

Department of Oral and Maxillofacial Surgery, University of Buenos Aires, Argentina

\***Corresponding author:** Garcia Blanco M, Department of Oral and Maxillofacial Surgery, School of Dentistry, University of Buenos Aires, Buenos Aires, Argentina

**Received:** November 26, 2018; **Accepted:** December 11, 2018; **Published:** December 18, 2018

## Abstract

Lipomas are benign adipose mesenchymal neoplasms, which are uncommon in the oral cavity. They are likely to have originated from mature adipose tissue and some histological variants have been described and are identified according to the predominant type of tissue in addition to adipose tissue. Surgical excision is the treatment of choice and recurrence is not expected. The purpose of this case report is to describe a large oral lipoma in the buccal mucosa and provide a review of the literature.

**Keywords:** Oral lipoma; Benign tumor; Buccal mucosa; Surgical excision

## Introduction

A lipoma is a benign mesenchymal soft-tissue neoplasm of mature adipocytes. Although not common in the oral cavity, lipoma is the most common benign mesenchymal neoplasia of soft tissues in adults. Around 20% of the cases involve the head and the neck region and only 1 to 4% occur in the oral cavity [1-3].

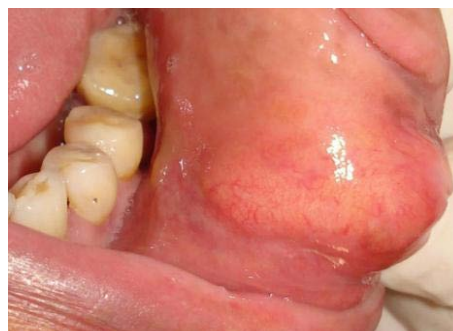Oral lipomas are found in specific anatomic sites within the oral and maxillofacial region, including, from most to least frequent, the following: parotid region, buccal mucosa, lip, submandibular region, tongue, palate, floor of mouth, and vestibule [1]. They usually present as painless, well-circumscribed, slow-growing submucosal masses [1-5]. Mean size of oral lipomas has been reported as 2 centimeters, and occurrence shows no gender preference [1,5]. Histopathologically, most oral lipomas are composed of mature fat cells surrounded by a thin fibrous capsule, arranged in a distinct lobular pattern [2,6-10].

The purpose of this article is to present a case report of an oral lipoma in the buccal mucosa, and provide a literature review of the pathology.

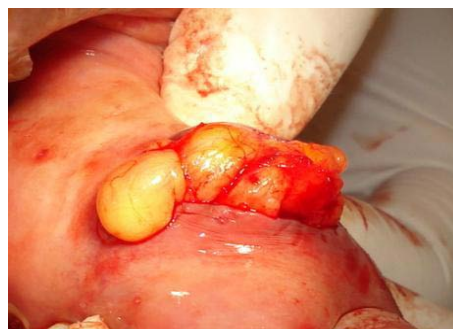## Case Presentation

A 44-year-old male with a slowly enlarging, painless swelling in the buccal mucosa visited the surgeon in October 2015. This lesion, with 15-month evolution, was not associated with trauma, dental infection, previous surgery, or systemic disease. It was palpable immediately beneath the mucosa, 3 centimeters in size, mobile, covered with normal mucosa, slightly yellowish, and depressible (Figure 1). No lymph nodes were palpable.

The lesion was presumptively diagnosed as oral lipoma, and differentially diagnosed as pleomorphic adenoma, mucoepidermoid carcinoma, fibroma, dermoid cyst, minor salivary gland tumors, mucocele, hemangioma, lymphangioma, rhabdomyoma or neuroma. Surgery was performed under local anesthesia, and the lesion was totally enucleated, with meticulous dissection of circumscriptive tissues (Figure 2). The wound was closed with 3.0 silk sutures (Figure 3). The resected tissue was fixed in formalin for histopathological examination (Figure 4). The postoperative period was uneventful (Figure 5). During the histological study, the tissue was stained with



**Figure 1:** Intra-oral view of the lesion.

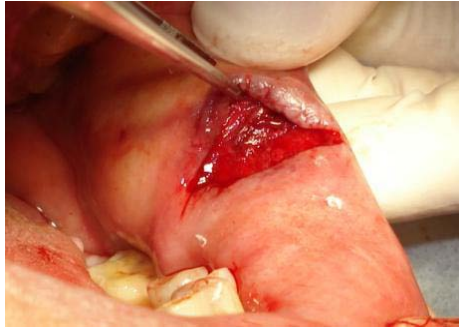


**Figure 2:** Surgical resection of oral lipoma.

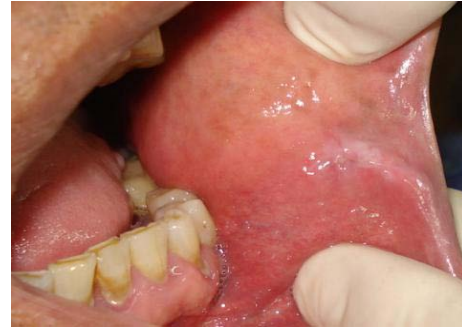hematoxylin and eosin, revealing mature fat cells arranged into lobules separated by septa of fibrous connective tissue. It was diagnosed as oral lipoma. No recurrence of the pathology was observed during a 2-year observation period.

## Discussion

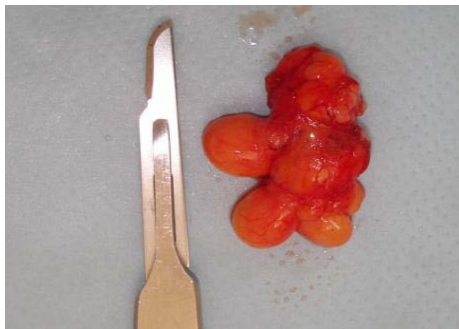
Oral lipoma was first described in 1848 by Roux, as 'yellowish epulis' [6]. Although trauma, infection and other factors have been proposed as etiological agents for lipomas, their etiology remains unknown [10]. A lipoma is usually an asymptomatic, mobile, soft, compressible submucosal mass with yellowish or normal mucosa color [1-5]. Mean size reported in the literature is 2 centimeters



**Figure 3:** Wound after resection.



**Figure 5:** Follow-up of the surgical site on day 10.



**Figure 4:** Resected tissue.

[1,4,5]. In the case report, the 3-centimeter diameter was relatively large; possibly due to its 15-month evolution. These tumors are usually observed in adult patients between the 4<sup>th</sup> and 6<sup>th</sup> decades of life, although an oral lipoma on a 6-year-old boy has been reported [2,5,6]. They generally do not show gender preference [1,5], but male preference [4], and a slight preference for females have been reported [1].

The most common sites of oral lipomas are the buccal mucosa and buccal vestibule, a region rich in fatty tissue [9]. Some studies have included lipomas of the parotid region, which I believe should also be considered oral lipomas [1]. Less common sites include tongue, floor of the mouth, palate and gingiva [2,11]. This distribution pattern corresponds to the quantity of fat deposits in the oral cavity [1,12-14]. The clinical course of oral lipomas is generally asymptomatic until they reach a large size. Large tumors can cause masticatory or swallowing difficulties [5,13].

Lipomas consist of mature fat cells arranged into lobules separated by septa of fibrous connective tissue [1-3,12]. Although morphologically indistinguishable from normal fat, lipomas differ from normal body fat in that they are usually surrounded by a thin fibrous capsule, and because their lipids are not available for normal metabolism [11]. Since there is a histological similarity between normal adipocytes and lipoma cells, accurate clinical and surgical information is very important in making a definitive diagnosis. In view of their similar clinical features, other tumors such as epidermoid cysts, pleomorphic adenomas, fibromas, thyroglossal duct cysts, ectopic thyrohyoid tissue, mucoepidermoid carcinoma, and oral dermoid and lymphoepithelial cysts should be included in the differential diagnosis [6,11]. The most frequent histological

subtype in the oral cavity is the simple lipoma, as presented herein [1,5]. The second most frequent subtype is the fibrolipoma, which is more frequent in the cheek mucosa and shows a slight predominance among females. Histologically, fibrolipomas consist of fat cells interspersed in broad bands of dense connective tissue [2,5,11]. The spindle cell lipoma consists of variable amounts of spindle cells of uniform appearance, typically in conjunction with a lipomatous component, while the pleomorphic lipoma consists of the presence of spindle cells with hyperchromatic giant cells [4,10]. Rarely, chondroid or osseous metaplasia may be seen in a lipoma which is described as chondroid lipoma, osteolipoma or ossifying lipoma [7-9]. Angiolipomas and myxoid lipomas are rare histological subtypes of lipoma and corresponded to less than 3% of all oral lipomas [1,12]. Angiolipomas mainly affect males in their early twenties. Careful examination should be performed to exclude angiosarcoma and Kaposi's sarcoma [12]. Myxoid lipomas of the oral cavity are well-circumscribed and contain adipocytes of variable size and myxoid areas. They are composed of solid proliferation of mature adipocytes admixed with abundant myxoid substances which contains scattered short spindle-shaped cells [2,4]. Occasionally, there is an extremely rare lipoma that may invade muscles or grow between the fibers, called infiltrating lipoma [14]. It is an uncommon mesenchymal neoplasm that characteristically infiltrates adjacent tissues and tends to recur after excision. Although rare, malignant transformation of oral lipomas to liposarcomas has been reported [13]. Malignant tumors are characterized by areas of lipoblastic proliferation, myxoid differentiation, cellular pleomorphism, increased vascularity, and mitosis [11]. In addition, the rare occurrence of multiple lipomas is associated with neurofibromatosis, Gardner's Syndrome, Cowden's syndrome, Dercum's disease, familial multiple lipomatosis, and Proteus syndrome [4-6].

The treatment of choice for oral lipomas is surgical resection [1,15]. However, advantages of suction-assisted lipectomy for large lipomas have been reported [5,13]. The prognosis for oral lipomas is excellent and recurrence is a rare event. No recurrence was observed in this patient.

## Conclusion

Lipomas are common in the head and neck region, but rare in the oral cavity. Although simple oral lipomas continue to be the main histological subtype, rare variants, such as myxoid lipoma and angiolipoma, should be considered. It is important to diagnose the lesion correctly in order to establish the prognosis. Conventional

surgical excision continues to be the treatment of choice for this pathology.

## Acknowledgment

The authors thank the Journal Section of the School of Dentistry of University of Buenos Aires and Dr. Stephanie Scanlan for assistance with this manuscript.

## References

1. Furlong MA, Fanburg-Smith JC, Childers EL. Lipoma of the oral and maxillofacial region: Site and subclassification of 125 cases. *Oral Surg Oral Med Oral Pathol Oral Radiol Endod.* 2004; 98: 441-450.
2. Fregnani ER, Pires FR, Falzoni R, Lopes MA, Vargas PA. Lipomas of the oral cavity: clinical findings, histological classification and proliferative activity of 46 cases. *Int J Oral Maxillofac Surg.* 2003; 32: 49-53.
3. Studart-Soares EC, Costa FW, Sousa FB, Alves AP, Osterne RL. Oral lipomas in a Brazilian population: a 10-year study and analysis of 450 cases reported in the literature. *Med Oral Patol Oral Cir Bucal.* 2010; 15: e691-e696.
4. Mehendiratta M, Jain K, Kumra M, Manjunatha BS. Lipoma of mandibular buccal vestibule: a case with histopathological literature review. *BMJ Case Rep.* 2016; 2016.
5. Egido-Moreno S, Lozano-Porras AB, Mishra S, Allegue-Allegue M, Mari-Roig A, López-López J. Intraoral lipomas: Review of literature and report of two clinical cases. *J Clin Exp Dent.* 2016; 8: e597-e603.
6. Venkateswarlu M, Geetha P, Srikanth M. A rare case of intraoral lipoma in a six year-old child: a case report. *Int J Oral Sci.* 2011; 3: 43-46.
7. Castilho RM, Squarize CH, Nunes FD, Pinto Júnior DS. Osteolipoma: a rare lesion in the oral cavity. *Br J Oral Maxillofac Surg.* 2004; 42: 363-364.
8. Darling MR, Daley TD. Intraoral chondroid lipoma: a case report and immunohistochemical investigation. *Oral Surg Oral Med Oral Pathol Oral Radiol Endod.* 2005; 99: 331-333.
9. Saghafi S, Mellati E, Sohrabi M, Raahpeyma A, Salehinejad J, Zare-Mahmoodabadi R. Osteolipoma of the oral and pharyngeal region: report of a case and review of the literature. *Oral Surg Oral Med Oral Pathol Oral Radiol Endod.* 2008; 105: e30-e40.
10. Coimbra F, Lopes JM, Figueiral H, Scully C. Spindle cell lipoma of the floor of the mouth. A case report. *Med Oral Patol Oral Cir Bucal.* 2006; 11: E401-E403.
11. Epivatianos A, Markopoulos AK, Papanayotou P. Benign tumors of adipose tissue of the oral cavity: a clinicopathologic study of 13 cases. *J Oral Maxillofac Surg.* 2000; 58: 1113-1117.
12. Altug HA, Sahin S, Sencimen M, Dogan N, Erdogan O. No infiltrating angioliipoma of the cheek: a case report and review of the literature. *J Oral Sci.* 2009; 51: 137-139.
13. Silistreli OK, Durmuş EU, Ulusal BG, Oztan Y, Görgü M. What should be the treatment modality in giant cutaneous lipomas?. Review of the literature and report of 4 cases. *Br J Plast Surg.* 2005; 58: 394-398.
14. Agarwal R, Kumar V, Kaushal A, Singh RK. Intraoral lipoma: a rare clinical entity. *BMJ Case Rep.* 2013; 2013.
15. Do Egito Vasconcelos BC, Granja Porto G, De Aguiar Soares Carneiro SC, De Freitas Xavier RL. Lipomas of the oral cavity. *Braz J Otorhinolaryngol.* 2007; 73: 722-871.