

## Research Article

# Condylar Height of the Mandible in Skeletal Class I Orthodontic Patients with Facial Asymmetry

Kajii TS<sup>1\*</sup>, Ooi K<sup>2</sup>, Fujita T<sup>1</sup> and Sakaguchi Y<sup>1</sup><sup>1</sup>Department of Oral Growth & Development, Fukuoka Dental College, Japan<sup>2</sup>Department of Oral & Maxillofacial Surgery, Kanazawa University, Japan

\*Corresponding author: Takashi S. Kajii, Section of Orthodontics, Department of Oral Growth & Development, Division of Clinical Dentistry, Fukuoka Dental College, Japan

Received: August 01, 2018; Accepted: August 29, 2018; Published: September 05, 2018

**Abstract**

**Purpose:** To evaluate the difference of the condylar height of the temporomandibular joint between shifted and non-shifted sides of the mandible in skeletal Class I orthodontic patients with facial asymmetry.

**Methods:** Twenty Japanese female patients with facial asymmetry with skeletal Class I malocclusion were examined. Pretreatment panoramic radiographs and cephalograms were used to measure condylar ratio and mandibular morphology, respectively.

**Results:** Condylar ratio was significantly smaller on the deviation side of the chin than on the non-deviation side. On the deviation side, there was no significant difference in condylar ratio between subjects with Idiopathic Condylar Resorption (ICR) and without ICR.

**Conclusions:** Condylar height was significantly longer on the non-deviation side of the chin than on the deviation side in skeletal Class I orthodontic patients with facial asymmetry. Facial asymmetry of skeletal Class I patients may be attributable to hemimandibular elongation on the non-shifted side of the mandible rather than ICR on the shifted side.

**Keywords:** Facial asymmetry; Temporomandibular joint; Hemimandibular elongation; Idiopathic condylar resorption; Osseous changes of the condyle; Backward rotation of the mandibular ramus

**Abbreviations**

TMJ: Temporomandibular Joint; H.H.: Hemimandibular Hyperplasia; H.E.: Hemimandibular Elongation; AICR: Adolescent Internal Condylar Resorption; ICR: Idiopathic Condylar Resorption; MRI: Magnetic Resonance Imaging; CH: Condylar Height; RH: Ramus Height

**Introduction**

Facial asymmetry denotes a dissimilarity or disproportionality between the right and left sides of the face, usually meant as an undesirable lack of balance. The asymmetry can be due to the underlying facial skeleton or to the soft tissue drape [1]. As a common clinical manifestation, abnormal skeletal development inducing facial asymmetry may be followed by chin deviation, mid-line shift, unilateral crossbite, and maxillary cant [2]. In facial asymmetry, asymmetry of the upper face is seen in only 5 %, whereas deviation of the chin is most obviously found [3,4].

Asymmetric growth and/or resorption of the condyle of the temporomandibular joint (TMJ) have been proposed for etiologic factor of acquired facial asymmetry [2,5,6], although the causes for facial asymmetry include congenital anomalies, trauma, and disease. Obwegeser [5] reported there are three clearly definable forms of condylar hyperactivity: Hemimandibular Hyperplasia (H.H.), Hemimandibular Elongation (H.E.), and hybrid form of H.H. and H.E. In H.H., the mandible on the affected side becomes larger in volume in all its sections without shifting the chin to the contralateral side. The occlusion is somewhat rotated, but there is no crossbite. In

H.E., elongation of the mandible on the affected side is found with shifting the chin to the contralateral side, with typical crossbite, but without an increase in volume of the affected side. Mandibular growth consists of a periosteal growth of cortical bone and an endochondral growth of the condyle. Active mandibular growth occurs in an endochondral growth of the condyle [7]. Bilateral mandibular hyperplasia and/or mandibular elongation can lead to mandibular prognathism (skeletal Class III malocclusion in anteroposterior skeletal pattern groups). H.E. is therefore seen in skeletal Class III and Class I orthodontic patients.

On the other hand, some studies [8-11] reported that unilateral osseous changes of the condyle are related to facial asymmetry with shifting the chin to the affected side. Wolford et al. [12] postulated that the articular disc becomes displaced anteriorly, and the condyle then is surrounded by the hyperplastic synovial tissue that continues to release chemical substrates [13,14] which penetrate the condylar head, causing osseous changes of the condyle in adolescent internal condylar resorption (AICR, formerly called idiopathic condylar resorption (ICR)). A few studies [13,15,16] reported the characteristics of maxillofacial morphology, backward (clockwise) rotation of the mandible, in skeletal Class II (retruded mandible) orthodontic patients with bilateral osseous changes of the TMJ condyle. Unilateral osseous changes of the condyle due to ICR therefore seem to be seen in skeletal Class II and Class I patients.

Patients with acquired facial asymmetry seem to include a lot of skeletal Class III patients and a few skeletal Class I and Class II patients. In skeletal Class I patients, some patients with facial asymmetry

might be attributed to H.E., while others might be attributed to unilateral osseous changes of the condyle due to ICR. Scientific evidence that facial asymmetry is attributed to the difference of the TMJ condylar size between affected and contralateral sides is still lacking. The objective of the present retrospective study is to evaluate the difference of the TMJ condylar height between deviation and non-deviation sides of the mandible in skeletal Class I orthodontic patients with facial asymmetry.

## Materials and Methods

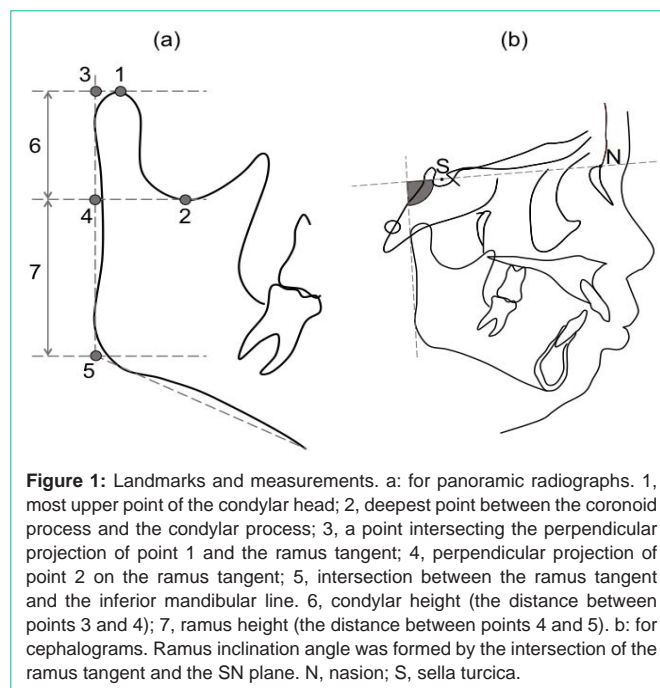
### Subjects

The Ethics Committee of the institutions of the authors' affiliations approved the protocols of this retrospective study (No. 267). All subjects provided their informed consent for participation in the study. Criteria for including a subject diagnosed with facial asymmetry and skeletal Class I malocclusion in this retrospective study were: 1) Japanese female; 2) age  $\geq 15$  years at initial examination, 3) undergoing orthognathic surgery; 4) chin deviation [17]  $> 2.0$  mm [4,10]; 5) ANB angle [18] of  $1.0^\circ$  to  $5.0^\circ$  [2]. Criteria for excluding a subject from the study were: 1) congenital anomalies; 2) history of rheumatoid arthritis; 3) history of trauma; and 4) previous orthodontic treatment. Postero-anterior and lateral cephalograms obtained at initial examination (pretreatment) from all subjects were used to analyze skeletal morphology. To measure condylar ratio [19,20], panoramic radiographs taken at initial examinations of all subjects were used. Radiographs were obtained using an AZ 3000 system (Asahi Roentgen, Kyoto, Japan), Cypher E system (Asahi Roentgen), or Veraviewepocs 2DE system (Morita, Tokyo, Japan). The head of the subject was exposed in an optimum position according to the operating instructions. If a subject showed osseous changes on the TMJ panoramic radiographs at the initial examinations, Magnetic Resonance Imaging (MRI) was obtained immediately after taking panoramic radiographs of the subject with a Philips 1.5-T INTERA Achieva Nova Dual R3.2 scanner (Philips Medical Systems, Best, the Netherlands) using a SENSE Flex-S Coil. Spin-echo proton density-weighted (1500 ms time of repetition [TR], 30 ms time of echo [TE]) and T2-weighted (2528 ms TR, 90 ms TE) pulse sequences were performed in the sagittal plane using 3-mm slice thickness and a 100-mm field of view (FOV). A T1-weighted (450 ms TR, 15 ms TE) pulse sequence was performed in the coronal plane using 3-mm slice thickness and a 100-mm FOV.

### Measurements and assessments

Deviation of the chin was measured with the methods recommended by Sassouni [17]. Briefly, Lo point was defined as an intersection of the oblique orbital line with the lateral contour of the orbits on the postero-anterior cephalograms. The facial midline was defined as a perpendicular to the line connecting bilateral Lo through neck of the crista galli. Chin deviation from the facial midline was measured. The condylar ratio derived from Kjellberg et al. [19] was measured. The panoramic landmarks and measurements used in this study were shown in Figure 1. The condylar ratio, Condylar Height (CH) / Ramus Height (RH), was measured. The lateral cephalometric measurement used in this study was also shown in Figure 1. Ramus inclination angle formed by the intersection of the mandibular ramus tangent and the SN plane was measured.

Two experienced readers who were blinded to the patients'



**Figure 1:** Landmarks and measurements. a: for panoramic radiographs. 1, most upper point of the condylar head; 2, deepest point between the coronoid process and the condylar process; 3, a point intersecting the perpendicular projection of point 1 and the ramus tangent; 4, perpendicular projection of point 2 on the ramus tangent; 5, intersection between the ramus tangent and the inferior mandibular line. 6, condylar height (the distance between points 3 and 4); 7, ramus height (the distance between points 4 and 5). b: for cephalograms. Ramus inclination angle was formed by the intersection of the ramus tangent and the SN plane. N, nasion; S, sella turcica.

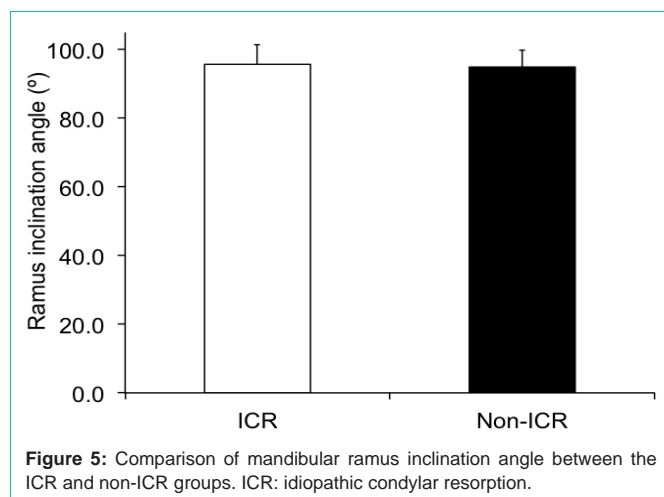
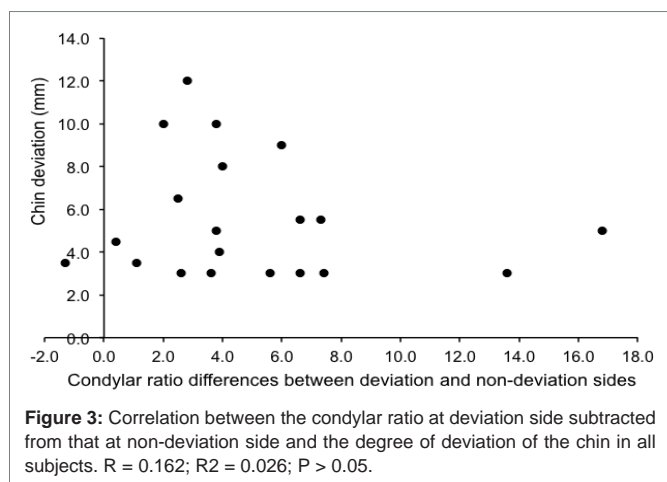
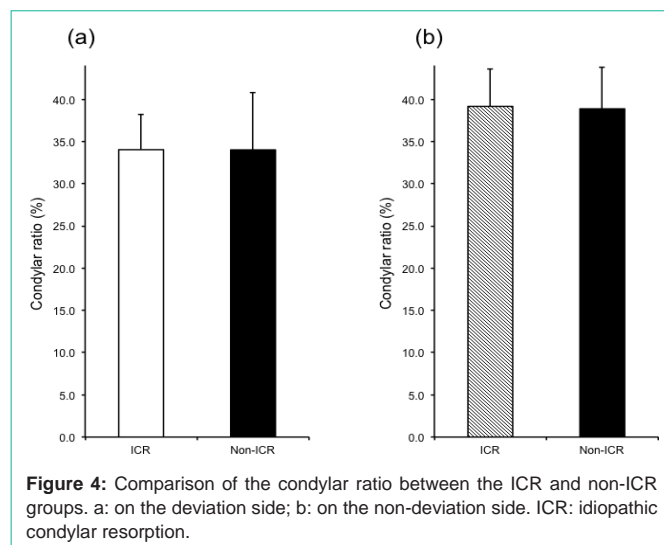
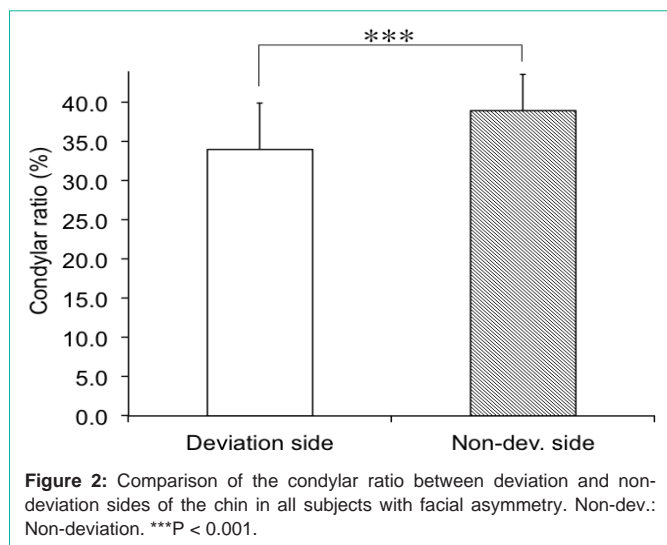
clinical information independently assessed osseous changes in the condyle using MRI for ICR diagnosis based on computed tomography findings [21,22] such as mandibular condyle erosion, osteophytes, subchondral cyst, generalized sclerosis, cortical sclerosis, and in addition, flattening [21]. The diagnosis of osseous changes was evaluated carefully, and some images without the clarity necessary for diagnosis (e.g., with disagreement on the diagnosis of osseous changes between two readers) were rejected.

### Statistical methods

Ten subjects were randomly selected to assess the reproducibility of these panoramic and cephalometric measurements. All measurements were repeated at least 4 weeks after the first measurements. The combined error (Se) and coefficient of reliability were calculated according to Houston [23]. Se was estimated using the formula  $Se^2 = \sum d^2 / 2n$ , where d is the difference between the first and second measurements, and n is the sample size. The coefficient of reliability was estimated by the formula  $1 - Se^2 / St^2$ , where St is the total variance of the measurement. For all measurements, the coefficient of reliability was above 95 % and was considered to be within acceptable limits. All variables of the condylar ratio and ramus inclination angle were normally distributed, so that paired t-test was used to compare condylar ratios between deviation and non-deviation sides of the chin. Student's or Welch's t-test was used to compare condylar ratios between the ICR and non-ICR subjects. Student's t-test was also used to compare mandibular ramus inclination angle between the ICR and non-ICR subjects. Pearson's correlation coefficient test was used to identify associations between deviation of the chin and condylar ratio. Statistical analyses were performed using the SPSS® version 23.0 statistical package (SPSS, Chicago, IL). The level of significance was set at a probability level of 0.05.

## Results

After removing 55 skeletal Class III patients and 4 skeletal Class



II patients with facial asymmetry satisfying inclusion criteria from 1) to 4) and all exclusion criteria, 20 subjects were evaluated. Mean ages at initial examination for the 20 subjects were 24.9 ± 7.2 (range: 15-39) years. Table 1 shows characteristics of this subjects with facial asymmetry with skeletal Class I malocclusion. Deviation of the chin was more frequent at left side than at right side. The number of facial asymmetry subjects with ICR (ICR group) and without ICR (non-ICR group) was 7 and 13, respectively. In all 7 unilateral ICR patients, ICR was observed on the deviation side of the chin.

Figure 2 shows comparison of the condylar ratio between deviation and non-deviation sides of the chin in all subjects with facial asymmetry. The mean value for condylar ratio on the deviation side was statistically significantly smaller than that on the non-deviation side (P < 0.001). Figure 3 shows correlation between the condylar ratio at deviation side subtracted from that at non-deviation side and the degree of deviation of the chin in all subjects. There was no significant correlation between the subtracted condylar ratio and the deviation of the chin (R = 0.162, R<sup>2</sup> = 0.026).

Figure 4 shows comparison of the condylar ratio between the ICR and non-ICR groups. On the deviation side of the chin, there was no significant difference in the mean value for condylar ratio between

the ICR and non-ICR groups. On the non-deviation side of the chin, there was also no significant difference in the condylar ratio between the groups.

Figure 5 shows comparison of the ramus inclination angle, which represents mandibular ramus backward (clockwise) rotation, between the ICR and non-ICR groups. There was no significant difference in the ramus inclination between the ICR and non-ICR groups.

### Discussion

In the present retrospective study, the number of patients satisfying inclusion criteria (Japanese female; age ≥15 years at initial examination; undergoing orthognathic surgery; chin deviation >2.0 mm) was 79. After removing 55 (70 %) skeletal Class III patients and only 4 (5 %) skeletal Class II patients, the number of skeletal Class I subjects was 20 (25 %). The results suggest that there are few patients with facial asymmetry with skeletal Class II malocclusion in Japanese population.

Although the use of panoramic radiography has limitation such as image distortion, projection artifacts, and differences in the liner measurements according to type of panoramic machine, some quantitative methods [19,20] have been used to measure not the

vertical dimension but the ratio. In the present study, we therefore statistically analyzed only condylar ratio.

In all subjects with facial asymmetry with skeletal Class I malocclusion, condylar ratio on the deviation side of the chin was statistically significantly smaller than that on the non-deviation side (Figure 2). The difference of the mandibular ramus size between deviation and non-deviation sides of the mandible was reported previously [6,9,11], but the present study first shows the difference of the condylar height between deviation and non-deviation sides of the mandible. In the present study, although condylar ratio was statistically significantly smaller on the deviation side than on the non-deviation side, there was no significant correlation between the subtracted condylar ratio and the deviation of the chin in all subjects with facial asymmetry (Figure 3). The no significant correlation between condylar height difference and chin deviation was similar to that reported previously [2].

The 20 subjects with facial asymmetry with skeletal Class I malocclusion included 7 (35 %) of unilateral (deviation side) ICR and 13 (65 %) of non-ICR patients (Table 1). On the deviation side of the chin, there was no significant difference in the condylar ratio between subjects with facial asymmetry with unilateral ICR and non-ICR (Figure 4). The novel finding of condylar height in the present study suggests that facial asymmetry of Skeletal Class I patients may be attributed to H. E. on the non-deviation side of the chin rather than osseous changes of the condyle on the deviation side of the chin. Stoustrup et al. [11] reported that the difference of condylar height between affected and contralateral sides of unilateral TMJ arthritis patients was significantly larger than that of a hypothetical symmetrical group. The inconsistent results of the condylar height on the affected side may be due to the difference of age of subjects. Mean ages at initial examination for subjects of Stoustrup et al. were 7.5 (range: 3-13) years, whereas the ages were 24.5 (range: 15-39) years in the present study.

In our previous study [16], the results suggested that skeletal Class II patients (retruded mandible) with “bilateral” ICR have shorter condylar height attributable to osseous changes of the TMJ condyle and that the shorter condylar height may affect subsequent further backward rotation of the ramus. The present study therefore evaluated relationship between unilateral ICR and backward rotation of the ramus.

Mandibular ramus of subjects with facial asymmetry with unilateral ICR on the deviation side of the chin did not incline significantly backward than that without ICR (Figure 5). The results were not similar to those of our previous study of bilateral ICR. The muscles attached to the mandibular ramus might retract the ramus upward [24] and forward [25]. The digastric and mylohyoid muscles of patients with short mandibular ramus height could retract the mandibular body backward and downward [24,26,27]. In patients with facial asymmetry, the muscular force on the deviation side of the chin could produce compressive deflection of the condyle, and compressive resorption of the condyle may result [13]. These findings and reports suggest that comparatively short condyle (and ramus) of patients with facial asymmetry with skeletal Class I malocclusion may affect subsequent osseous changes of the condyle on the deviation side of the chin (unilateral ICR), while osseous changes may affect

subsequent further backward rotation of the ramus in patients with bilateral ICR.

From the clinical viewpoint, orthognathic surgeons and orthodontists should pay attention to treatment plan for orthognathic surgery such as two-jaw surgery (Le Fort I osteotomy and bilateral sagittal splitting ramus osteotomy) on the mandibular deviation side of patients with facial asymmetry with ICR. If surgeons and orthodontists plan to elongate deviation side of distal segment of the mandible of the patient downward, the digastric and mylohyoid muscles on the deviation side produce a backward and downward directed force on the distal segment of the mandible [27]. In consequence, the force on the distal segment may cause the proximal segment on the deviation side of the mandible to be pushed upward, and the superior-anterior surface of the condyle may be compressed into the glenoid fossa, and subsequent idiopathic (or progressive) condylar resorption may occur [27,28,29]. The present study therefore supports the recommendation that deviation side of distal segment of the mandible should not be elongated downward by two-jaw surgery for surgical orthodontic treatment of patients with facial asymmetry with ICR.

## Conclusion

In patients with facial asymmetry with skeletal Class I malocclusion, TMJ condylar height on the non-deviation side of the mandible was significantly longer than that on the deviation side. On the deviation side in patients with facial asymmetry, there was no significant difference in the condylar height between with and without ICR.

The findings suggest that facial asymmetry of skeletal Class I patients may be attributed to H.E. on the non-deviation side of the mandible rather than ICR on the deviation side.

## Acknowledgments

The authors would like to thank Dr. Sachio Tamaoki (Section of Orthodontics, Fukuoka Dental College) for their contributions to this study.

## References

1. Daskalogiannakis J. Glossary of Orthodontic Terms. Berlin: Quintessence Publishing; 2000.
2. Zhang Y, Che B, Ni Y, Zhang H, Pan Y, Wang L, et al. Three-dimensional condylar positions and forms associated with different anteroposterior skeletal patterns and facial asymmetry in Chinese adolescents. *Acta Odontol Scand.* 2013; 71: 1174-1180.
3. Severt TR, Proffit WR. The prevalence of facial asymmetry in the dentofacial deformities population at the University of North Carolina. *Int J Adult Orthod Orthognath Surg.* 1997; 12: 171-176.
4. Haraguchi S, Takada K, Yasuda Y. Facial asymmetry in subjects with skeletal Class III deformity. *Angle Orthod.* 2002; 72: 28-35.
5. Obwegeser HL. Condylar hyperactivity. In: Obwegeser HL, editor. *Mandibular growth anomalies.* Berlin: Springer-Verlag; 2001. 139-144.
6. Kim SJ, Lee KJ, Lee SH, Baik HS. Morphologic relationship between the cranial base and the mandible in patients with facial asymmetry and mandibular prognathism. *Am J Orthod Dentofacial Orthop.* 2013; 144: 330-340.
7. Björk A. Prediction of mandibular growth rotation. *Am J Orthod.* 1969; 55: 585-599.

8. Yahata M, Yamada K, Hayashi T, Saito I. Unilateral condylar bone deformity and slope of articular eminence related to mandibular asymmetry. *Cranio*. 2009; 27: 261-267.
9. Matsumoto R, Ioi H, Goto TK, Hara A, Nakata S, Nakashima A, et al. Relationship between the unilateral TMJ osteoarthritis/osteoarthritis, mandibular asymmetry and the EMG activity of the masticatory muscles: a retrospective study. *J Oral Rehabil*. 2010; 37: 85-92.
10. Ooi K, Inoue N, Minowa K, Totsuka Y. Factors related to the prevalence of anterior disc displacement without reduction and bony changes of the temporomandibular joint in patients with facial asymmetry. *Oral Sci Int*. 2013; 10: 65-69.
11. Stoustrup P, Kùseler A, Kristensen KD, Herlin T, Pedersen TK. Orthopaedic splint treatment can reduce mandibular asymmetry caused by unilateral temporomandibular involvement in juvenile idiopathic arthritis. *Eur J Orthod*. 2013; 35: 191-198.
12. Wolford LM, Cassano DS, Gonçalves JR. Common TMJ disorders: Orthodontic and surgical management. In: McNamara JA, Kapila SD, editors. *Temporomandibular disorders and orofacial pain: Separating controversy from consensus*. Volume 46, Craniofacial growth series. Ann Arbor (MI): The University of Michigan; 2009; 159-198.
13. Arnett GW, Milam SB, Gottesman L. Progressive mandibular retrusion - idiopathic condylar resorption. Part II. *Am J Orthod Dentofacial Orthop*. 1996; 110: 117-127.
14. Kajii TS, Okamoto T, Yura S, Mabuchi A, Iida J. Elevated levels of  $\beta$ -endorphin in temporomandibular joint synovial lavage fluid of patients with closed lock. *J Orofac Pain*. 2005; 19: 41-46.
15. Chen S, Lei J, Fu KY, Wang X, Yi B. Cephalometric analysis of the facial skeletal morphology of female patients exhibiting skeletal Class II deformity with and without temporomandibular joint osteoarthritis. *PLOS ONE*. 2015; 10: e0139743.
16. Kajii TS, Fujita T, Sakaguchi Y, Shimada K. Osseous changes of the mandibular condyle affect backward-rotation of the mandibular ramus in Angle Class II orthodontic patients with idiopathic condylar resorption of the temporomandibular joint. *Cranio*. 2018; doi:10.1080/08869634.2017.1421446.
17. Sassouni V. Position of the maxillary first permanent molar in the cephalofacial complex: A study in three dimensions. *Am J Orthod*. 1957; 43: 477-510.
18. Stainer CC. Cephalometrics for you and me. *Am J Orthod*. 1953; 39: 729-755.
19. Kjellberg H, Ekstubbé A, Kiliaridis S, Thilander B. Condylar height on panoramic radiographs. A methodologic study with a clinical application. *Acta Odontol Scand*. 1994; 52: 43-50.
20. Ahn SJ, Kim TW, Lee DY, Nahm DS. Evaluation of internal derangement of the temporomandibular joint by panoramic radiographs compared with magnetic resonance imaging. *Am J Orthod Dentofacial Orthop*. 2006; 129: 479-485.
21. Ahmad M, Hollender L, Anderson Q, Kartha K, Ohrbach RK, Truelove EL, et al. Research diagnostic criteria for temporomandibular disorders (RDC/TMD): Development of image analysis criteria and examiner reliability for image analysis. *Oral Surg Oral Med Oral Pathol Oral Radiol Endod*. 2011; 112: 118-125.
22. Schiffman E, Ohrbach R, Truelove E, Look J, Anderson G, Goulet JP, et al. Diagnostic criteria for temporomandibular disorders (DC/TMD) for clinical and research applications: Recommendations of the international RDC/TMD consortium network and orofacial pain special interest group. *J Oral Facial Pain Headache*. 2014; 28: 6-27.
23. Houston WJ. The analysis of errors in orthodontic measurements. *Am J Orthod*. 1983; 83: 382-390.
24. Gonçalves JR, Cassano DS, Wolford LM, Santos-Pinto A, Márquez IM. Postsurgical stability of counterclockwise maxillomandibular advancement surgery: Affect of articular disc repositioning. *J Oral Maxillofac Surg*. 2008; 66: 724-738.
25. Aymach Z, Kawamura H. Facilitating ramus lengthening following mandibular-dependent surgical closing of a skeletal open bite with short ramus: a new modified technique. *J Craniomaxillofac Surg*. 2012; 40: 169-172.
26. Al-Moraisi EA, Wolford, LM. Does temporomandibular joint pathology with or without surgical management affect the stability of counterclockwise rotation of the maxillomandibular complex in orthognathic surgery? A systematic review and meta-analysis. *J Oral Maxillofac Surg*. 2017; 75: 805-821.
27. Hwang SJ, Haers PE, Sailer HF. The role of a posteriorly inclined condylar neck in condylar resorption after orthognathic surgery. *J Craniomaxillofac Surg*. 2000; 28: 85-90.
28. Kobayashi T, Izumi N, Kojima T, Sakagami N, Saito I, Saito C. Progressive condylar resorption after mandibular advancement. *Br J Oral Maxillofac Surg*. 2012; 50: 176-180.
29. Nogami S, Yamauchi K, Satomi N, Yamaguchi Y, Yokota S, Abe Y, et al. Risk factors related to aggressive condylar resorption after orthognathic surgery for females: retrospective study. *Cranio*. 2017; 35: 250-258.