

## Review Article

## Oral Ulcers - A Review

Sivapathasundharam B<sup>1\*</sup>, Sundararaman P<sup>1</sup> and Kannan K<sup>2</sup><sup>1</sup>Department of Oral Pathology, Meenakshi Ammal Dental College, Chennai, India<sup>2</sup>Department of Oral Medicine and Radiology, College of Dentistry, Majmaah University, Saudi Arabia

\*Corresponding author: Sivapathasundharam B, Department of Oral Pathology, Meenakshi Ammal Dental College, Chennai, India

Received: April 11, 2018; Accepted: May 22, 2018;

Published: May 29, 2018

## Abstract

Ulcer is a break in continuity of the epithelium brought about by molecular necrosis. Ulcers are most common in the oral region, for which the patient seeks help from their physician/dental surgeon. The presenting complaints are usually redness, burning sensation and/or pain. They can present in any part of the oral cavity but may be painful if it occurs in the movable area [1].

**Keywords:** Ulcers; Necrosis; Malignant

## Introduction

## Types

Based on the duration ulcers can be broadly classified into acute (short term) or chronic (long term). Acute ulcers persist no more than three weeks and regress spontaneously such as traumatic ulcers, aphthous ulcers, herpetic ulcers and chancres. Chronic ulcers persist for weeks and months such as major aphthous ulcers, ulcers from odontogenic infection, malignant ulcers, gummas, ulcers secondary to debilitating systemic disease and some traumatic ulcers (with a persistent traumatic element) [2].

In addition, they can also be typed as single or multiple depending on their presentation. The solitary lesions may result from a trauma, infection or it could be a carcinoma and can present as a single ulcerative lesion. Multiple lesions may be seen in viral infections or autoimmune diseases and can present with several ulcerations [3]. Recurrent ulcers may present with a history of similar episodes along with intermittent healing. The size of the ulcers can vary from a few millimeters to centimeters and occasionally may present with fever and regional lymphadenopathy [4].

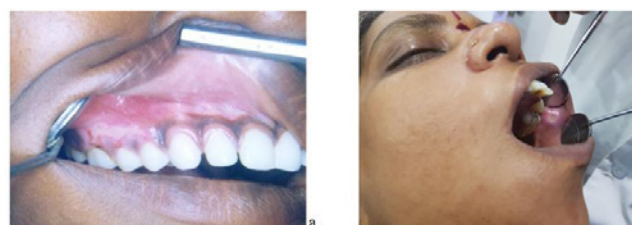Diagnosis of oral ulcers at times may be challenging and therefore it is important to consider the differential diagnosis. History taking should include duration, associated symptoms, pattern of occurrence or recurrence and associated systemic conditions.

## Acute ulcers

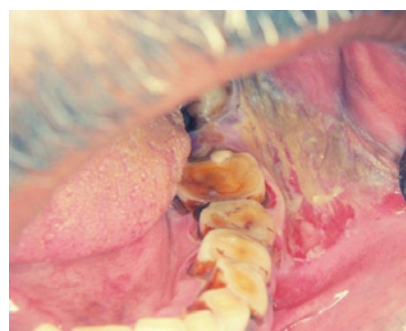**Traumatic ulcers:** Traumatic ulcers are quite common and acute in nature. The ulcers are caused usually by physical, thermal or chemical trauma to the oral mucosa causing tissue damage and resultant ulceration. Physical trauma can be caused during regular activities like tooth brushing (Figure 1a) or flossing, sharp edges of denture or tooth (Figure 1b), oral piercings and sometimes can be self-inflicted by the patient when he/she is under local anesthesia during a dental procedure [4].

The commonly encountered thermal burns occur when ingesting hot food substances or beverages like pizza, coffee or tea or from a heated dental instrument during a dental procedure.

Oral mucosal damage can result from unintentional use of therapeutic agents during dental procedures such as eugenol,



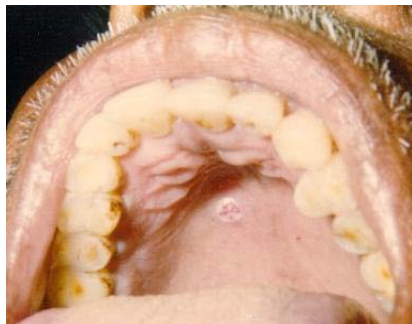**Figure 1:** a) Traumatic ulcer in the gingiva in brush injury, b) Traumatic ulcer due to sharp tooth.



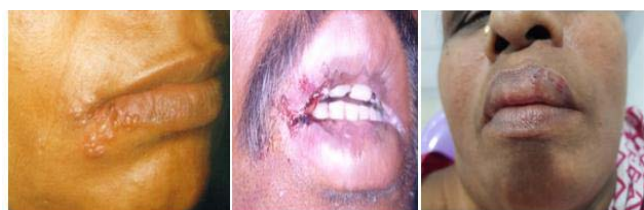**Figure 2:** Chemical burn produced by the placement of tablet aspirin.

formocresol, sodium hypochlorite, monomer and the like. Among the dental materials, liquids are likely to cause chemical oral burns because they can be difficult to manipulate. Chemical burns due to aspirin are seen in patients who keep the aspirin tablet to relieve pain (Figure 2) [5]. Mucosal alterations can also be caused by mouth washes or oral care products with high alcohol content.

The resultant ulcerations are acute and the extent of ulceration is based on the location and the aetiology of trauma. Lips are the common site for electrical burns and seen among young children. Burn injuries from food are small and localized to the hard palate and lips and seen in teenagers and adults. These present with tenderness and an area of erythema that develop into ulcers which may take several days to heal depending on the extent of injury. The ulcers have a yellowish white necrotic pseudomembrane with borders that are raised and erythematous. The ulcers of the lip are usually crusted [6].



**Figure 3:** Chronic nodular lesion with surface ulceration of Necrotizing sialometaplasia.



**Figure 4:** a) Showing Clusters of vesicles, b) showing large irregular ulcer due to the coalescence of multiple pin headed sized ulcers, c) Healing herpes labialis.

The traumatic ulcers usually heal within 7-10 days when the cause is removed. It is important to distinguish traumatic lesions from squamous cells carcinoma. If the ulcer does not heal within two weeks, a biopsy should be taken to rule out a deep fungal infection or malignancy [4]. These ulcers are usually single, however, syphilis may present as single ulcers in primary and tertiary stages.

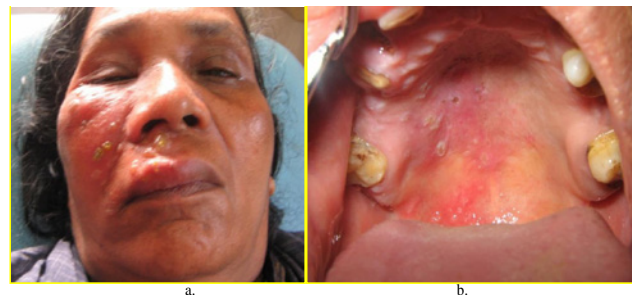### Necrotizing sialometaplasia

Necrotizing Sialometaplasia (NS) is both acute and chronic in nature. It is a self-limiting, benign, non-neoplastic, inflammatory disease of the salivary glands mimicking a malignancy both clinically and Histopathologically [7]. It is more frequently seen in middle aged men. Most common site of involvement is the palate, followed by lower lip, retromolar area, sublingual region, tongue and larynx. The lesion initially starts as a non ulcerated swelling associated with pain and later the necrotic tissue sloughs leaving a crater like ulcer. The ulcer is indurated with well delineated borders (Figure 3). The size of the lesion usually ranges from 1cm to more than 5cm [6]. The ulcer resolves on its own within 5 to 7 weeks [8].

### Primary herpetic gingivostomatitis

Primary herpetic gingivostomatitis is the most common oral manifestation of symptomatic herpes simplex virus (HSV) infection. More than 90% of the cases are caused by HSV-1 which occurs above the waist, whereas HSV-2 occurs below the waist. However, with the changing sexual practices, it is not unusual to culture HSV-2 from oral lesions [9]. Usually the age of occurrence is between 6 months to 5 years with a peak incidence between 2 and 3 years. Prodromal symptoms include fever, nausea, anorexia and irritability [10].

The initial contact with the virus is acquired by inoculation of the mucosa, skin, and eye with infected secretions resulting in primary



**Figure 5:** a) Vesicles and bulla located in the right maxillary dermatome and b) showing multiple small ulcers in the right half of palate not crossing midline in Shingles.

infection. The virus then establishes a chronic latent infection in the sensory ganglion such as the trigeminal ganglion by travelling along the sensory nerve axons [4].

The oral manifestations present as erythema and clusters of pin headed vesicles (Figure 4) and/or ulcers appear on the hard and soft palate, attached gingiva, tongue, buccal and labial mucosa within few days after the prodromal symptoms. The vesicles break down to form ulcers that range from 1 to 5 mm and coalesce to form larger ulcers. The borders are scalloped with erythema. The mouth is painful, red and often causes difficulty in swallowing and eating. Reactivation of HSV may lead to asymptomatic shedding of HSV in the saliva and oral secretions, which may also cause ulcers at the site of innervations usually in the vermillion border and perioral skin and they are called as herpeslabialis/cold sores/fever blisters [11]. Recrudescence HSV in immunocompromised patients occur chiefly on the keratinized mucosa with oral ulcers similar to primary HSV infection [12]. Recurrent HSV ulcers may also mimic traumatic ulcers seen on the palate.

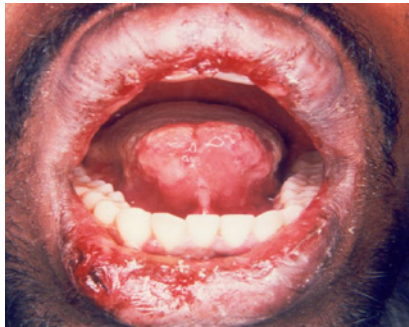In cases of recurrent herpes labialis, the vesicle rupture to form ulcers covered with crust of purulent exudates due to secondary infection. Primary herpetic gingivo-stomatitis might show ulcerations similar to coxsackie virus infections but the latter does not present ulcers on the gingiva and are not clustered. A viral culture or a cytology smear differentiates between the two.

A cytological smear or viral culture is necessary to rule out aphthous ulcers, necrotizing ulcerative gingivitis and ulcers secondary to cytomegalovirus infection from recurrent intraoral herpes in immunocompromised patients.

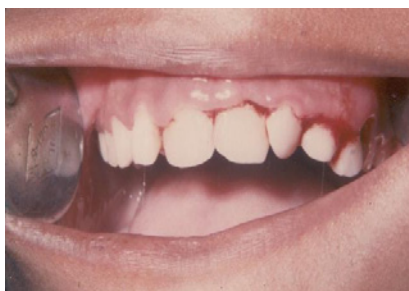### Varicella zoster virus infection

Primary VZV infection or chicken pox generally occurs in the first two decades of life. The disease begins with a low-grade fever, malaise, and the development of an intensely pruritic, maculopapular rash [13] and followed by "dewdrop-like" vesicles.

Some patients present with involvement of the trigeminal nerve and the condition is painful when the maxillary branch is involved. The patients undergo a prodromal phase of pain, burning sensation, usually on the palate [1]. After few days of the prodromal symptoms, ulcers occur in clusters measuring about 1-5mm in diameter, in a unilateral pattern especially on the hard palate or the gingiva (Figure 5). These ulcers coalesce to form larger ulcers with scalloped border.



**Figure 6:** Multiple large shallow irregular ulcers which bleed profusely with bloody crustations in lips in erythema multiforme.



**Figure 7:** The characteristic blunting and punched out ulcer of interdental papilla in ANUG.

These ulcers heal by 10 to 14 days [14].

The pain that is experienced in the prodrome before the onset of vesicles and ulcers may lead to an incorrect diagnosis of pulpitis, leading to unnecessary dental treatment. HSV and herpes zoster infection can be differentiated by culture. However, HSV if mild and localized to one side, should not be mistaken for herpes zoster. Autoimmune diseases like pemphigus and pemphigoid also present with skin and oral ulcerations but these lesions are chronic and do not present unilaterally. If the patient is immunocompromised, acute necrotizing ulcerative periodontitis should be considered which can be ruled out with appropriate tests.

### Erythema multiforme

Erythema Multiforme (EM) is an acute, self-limiting, mucocutaneous disease that manifests on the skin and often oral mucosa. The etiopathogenesis is considered as type III and IV hypersensitivity reaction precipitated by various factors like infection such as HSV, drug reactions to NSAIDs or anticonvulsants, sulphonamides and antibiotics [15].

The age group of 20 to 40 years is most commonly affected with a slight male predilection and 20% cases are seen in children too. EM has been categorized as minor, major, Steven-Johnson Syndrome or Toxic Epidermal Necrolysis. The former is the mildest type and the latter is the most severe one. Prodromal symptoms such as fever, lymphadenopathy, headache, malaise, cough, and sore throat may be noticed one week prior to onset of mucocutaneous erythema or blisters.

The skin lesions present as red macules, papules and vesicles that coalesce to form larger plaques on the skin that are called target

lesions.

The oral findings are mostly seen on the lips, buccal mucosa, tongue and labial mucosa. They range from mild erythematous macules on the lips and buccal mucosa to painful ulcerations with irregular borders and inflammatory halo (Figure 6). Bloody encrustations on the lip are a diagnostic feature for EM. In severe cases when the ulcers are large, there may be difficulty in eating, drinking and swallowing [16].

Primary herpetic gingivostomatitis with its viral prodrome and erosions and ulcerations may resemble EM but the lack of skin rash and culture negative tests can rule out viral infections. The viral lesions are small and circumscribed unlike EM. Pemphigus and pemphigoid lesions present more as a bulla than the lesions in EM that presents as maculopapular. Unlike pemphigus and pemphigoid the healing is considerable faster.

Acute Necrotizing Ulcerative Gingivitis (NUG) and Acute Necrotizing Ulcerative Periodontitis (NUP)

These lesions are acute, ulcerative inflammatory conditions of the gingiva and the periodontium that are associated with polymicrobial infection like treponema species, prevotellaintermedia etc. ANUG is also called 'Trench Mouth' since it was common among the soldiers in trenches during World War I. NUG and NUP are mostly associated with immunosuppression, smoking, poor oral hygiene and debilitation [17].

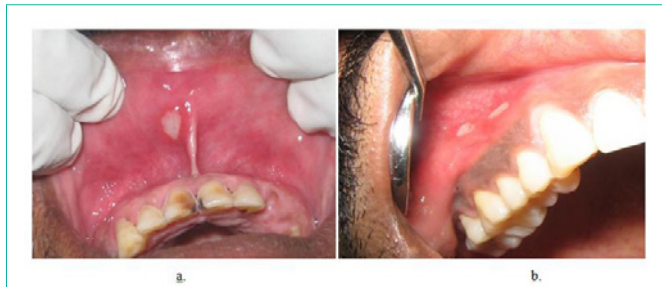Acute necrotizing ulcerative gingivitis is an inflammatory destructive disease of the gingiva characterized by punched out ulceration with a crater like depression at the crest of the interdental papilla (Figure 7). The crater is covered by a grayish pseudomembranous slough [18]. The lesion may involve the marginal gingiva, attached gingiva and may extend till the bone. The early symptoms are excessive salivation, a metallic taste and gingival sensitivity and bleeding along with halitosis. NUG and NUP may progress to Noma (Cancrumoris) in immunocompromised or malnutrition patients [19]. There is sloughing of the oral mucosa followed by sequestration of the exposed, necrotic bone and teeth. The diagnosis of NUG is based on sore gums, bleeding gums, and, the most diagnostic criterion, ulceration and necrosis of the interdental papillae.

### Recurrent aphthous stomatitis

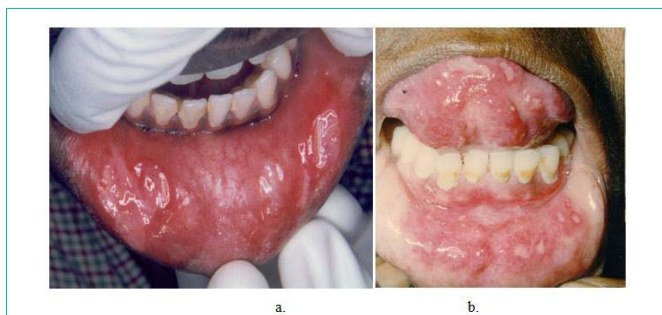
Recurrent Aphthous Stomatitis (RAS) is characterized by recurring ulcers confined to the oral mucosa in the absence of other signs of disease. They are classified as minor ulcers, major ulcers and herpetiform ulcers. The most common are the minor ulcers, which are less than 1cm in diameter. The major ulcers are over 1cm and take time to heal and often scar. Herpetiform ulcers are recurrent crops of dozens of small ulcers throughout the oral mucosa [20].

The aetiology is usually related to genetic factors, hematologic deficiencies immunologic abnormalities and trauma. There have been theories suggesting a link between RAS and oral streptococci, *H. pylori*, *Cytomegalo Virus*, herpes virus, and varicella zoster virus. However, the data is inconclusive linking RAS to a specific microorganism [21].

The ulcers are most common during the second decade of life and are confined to the oral mucosa. There is burning sensation of the oral



**Figure 8:** a) single round ulcer in upper labial mucosa with yellowish white slough in the floor with erythematous halo. b) Two ovoid ulcers of 3 mm size in the upper alveolar mucosa with yellowish slough in the floor and erythematous halo.



**Figure 9:** a) Aphthous major ulcer in lower labial mucosa with more than 2 cm in size. b) Multiple pin head sized ulcers with diffuse background of erythema in non-keratinized mucoa of ventral surface of tongue and lower labial mucosa in herpetiformeapthae.

mucosa 24 to 48 hours before the ulcer appears. During this initial period, a localized area of erythema develops. Within hours, small white papules form, ulcerates, and gradually enlarges over the next 48 to 72 hours.

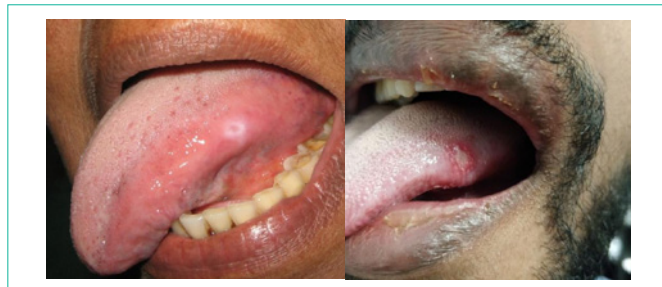The lesions are painful, round, symmetric and shallow with fibrin covered mucosal defects and an erythematous border (Figure 8). It is most commonly seen on non-keratinized healthy mucosa and sometimes on the keratinized mucosa especially in patients with immune deficiency [1].

In mild RAS, the lesions reach a size of 0.3 to 1.0 cm and begin healing within a week. Healing without scarring is usually complete in 10 to 14 days. Most patients experience multiple episodes per year with two to six lesions each time [4].

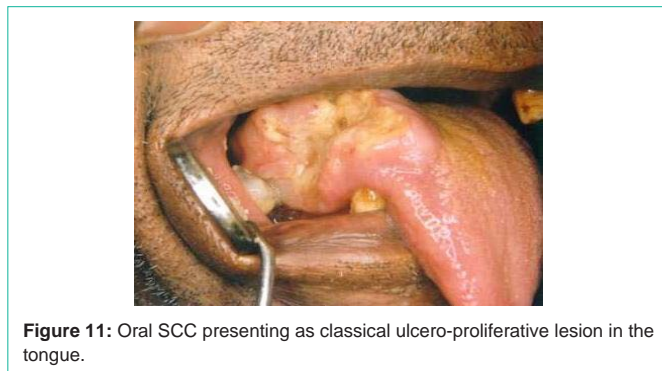
Major ulcers (Sutton ulcer) are more than 1 cm in diameter and last for weeks to months. In severe cases, the entire mucosa may be covered with ulcers, which are painful and debilitating (Figure 9). The lesions may last for months and sometimes be misdiagnosed as squamous cell carcinoma, chronic granulomatous disease or pemphigoid. The lesions heal slowly with scarring [1].

The least common variant is the herpetiform type, which tends to occur in adults characterized by small punctate ulcers scattered over large portions of the oral mucosa. Recurrent oral aphthous ulcers are seen in Behcet’s syndrome along with skin, eye and genital lesions [22].

A detailed history and examination can distinguish RAS from acute viral ulcers or chronic autoimmune lesions, drug reactions and



**Figure 10:** a & b – A chronic traumatic ulcer in left lateral border of tongue due to sharp edges of molars.



**Figure 11:** Oral SCC presenting as classical ulcero-proliferative lesion in the tongue.

connective tissue disease.

**Behçet disease [BD (Behçet Syndrome)]**

Behçets disease (BD) is a multisystem inflammatory disease characterized by recurring episodes of oral aphthous ulcers, genital ulcers, other skin lesions, and ocular lesions [23].

The pathogenesis of BD is unknown but mostly related to autoimmunity. It can affect all age groups but it is rarely seen before puberty and after sixth decade of life.

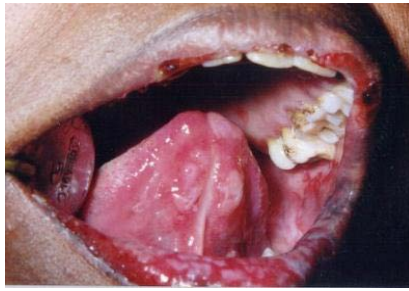The most common are the oral ulcers, which are recurrent and painful in most of the cases and cannot be distinguished either clinically or histological from RAS. Some lesions are mild and recurrent and others have deep, large and scarring lesions. A diagnosis of Behcet’s is made when recurrent aphthous ulcers are seen along with two of the following lesions, namely oral, genital ulcers, ocular lesions and skin lesions [24].

**Ulcers in other Systemic Disorders**

**Uremic stomatitis**

Uremic stomatitis is a rare oral mucosal disorder associated with a renal disorder. The renal function is impaired and with a decreased glomerular filtration rate (GFR), and accumulation and retention of various products of renal failure changes the oral cavity progressively through an azotemic to a uremic state [25].

Etiology is unknown although it has been suggested that it may be due to increased levels of ammonia compounds and stomatitis may appear when the blood urea levels are higher than 300 mg/ml [26]. Other possible causes include hemorrhagic diathesis commonly seen in uremia, causing decrease of viability of the affected tissues allowing bacterial infection, that can result in ulceration and pseudomembrane formation.



**Figure 12:** Pemphigus ulcers showing extensive ulcerations and bloody crustations in lips.

Four forms of stomatitis that have been recognized are ulcerative form, hemorrhagic form, nonulcerative pseudomembranous form and hyperkeratotic form. The latter two are commonly appear as white lesions. The hyperkeratotic form presents as multiple, painful white keratotic lesions with thin projections whereas the nonulcerative form may exhibit a erythematous pultaceous form characterized by red mucosa covered with a thick exudates and a pseudomembrane. The tongue and the floor of the mouth are more frequently affected. Xerostomia, unriniferous breath, dysgeusia and burning sensation are common symptoms [25].

In some patients, the oral lesions may clear within a few days after dialysis and may also extend till 2-3 weeks. Younger patients have more impairment in taste modalities than older patients, but they may have a better recovery of neural taste function following dialysis.

### Crohn's disease

Crohn's Disease (CD) is an immune-mediated disorder, multisystem, inflammatory disorder of the gastrointestinal (GI) tract. Crohn's disease along with ulcerative colitis, comprises the two major subsets of the Inflammatory Bowel Disease (IBD) [27].

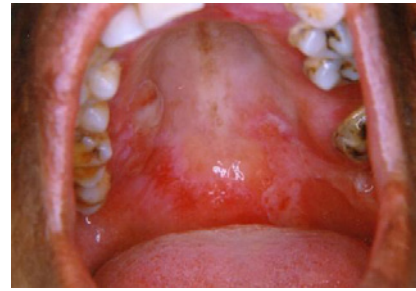The underlying etiology is not clear but likely is an inappropriate mucosal response to intestinal microbes due to effects in mucosal immunity and intestinal epithelial barrier function in genetically susceptible individuals [28]. Oral lesions are seen in about 80% of the patients and may precede intestinal manifestations.

Oral lesions considered to be pathognomonic for CD include persistent lip swelling, cobblestone appearance of the oral mucosa, mucogingivitis, deep linear or serpiginous ulcerations surrounded by epithelial hyperplasia, and tissue tags or polyps [29]. Aphthous ulcers along with angular cheilitis and perioral dermatitis may also be seen.

### Diabetes mellitus

Diabetes mellitus is a metabolic disorder resulting from a deficiency of insulin which may be absolute due to pancreatic  $\beta$ -cell destruction (type 1) or relative due to an increased resistance of the tissues to insulin (type 2). Oral manifestations are usually gingivitis, periodontitis, oral mucosal diseases that favor infections such as candidiasis, salivary gland dysfunction, altered taste, glossodynia, and stomatopyrosis. Oral lesions such as lichen planus and recurrent aphthous ulcerations have also been diagnosed in these patients [30].

Some studies have shown prevalence of ulcers, both traumatic and aphthous mostly in patients with type 2 diabetes. Oral mucosal alterations in diabetes may cause symptoms such as glossodynia,



**Figure 13:** Bullous pemphigoid showing ruptures bullous lesion appearing as large irregular ulcers in the palate.

stomatopyrosis, and dysgeusia and thus, the occurrence of oral ulcers causes pain, discomfort and burning affecting the oral health of patients [31].

Some patients also show the presence of actinic cheilitis which may be an important finding due to its malignant potential especially in elderly patients.

### Sjögren syndrome

Sjögren syndrome is a systemic autoimmune disorder of unknown aetiology presenting with xerostomia, xerophthalmia, and arthritis. The most common oral manifestations in primary and secondary Sjögren syndrome are angular cheilitis, increased lip dryness, non-specific ulcerations, aphthae and aphthoid conditions [32].

Depending on the degree of xerostomia, the patients complain of dry or burning sensation, soreness and pain of the mucous membrane though the oral mucosa appears normal. When the salivary deficiency is more, there may be alterations of the mucosa which will appear dry and atrophic, either inflamed or pale and translucent. The tongue may show atrophy of papillae, inflammation, fissuring and cracking [33].

Decreased secretion of saliva may increase the risk of opportunistic infections, mainly fungal infections by *Candida albicans* (*C. albicans*). Oral candidiasis is usually the chronic form which may be asymptomatic or may show as fissured tongue, median rhomboid glossitis, non-specific ulcerations, prosthetic stomatopathies, or generalised candidiasis. *Candida albicans* infection accompanies angular cheilitis and exfoliative cheilitis and very often observed in Sjögren syndrome patients [32]. However, exfoliative cheilitis may also be observed in patients with HIV or Leukemia.

## Chronic Ulcers

### Sustained traumatic ulcers (Decubitus ulcer)

Chronic injury to the oral mucosa may lead to long standing traumatic ulcers characterized by fibrosis surrounded by ulcerations. They are mostly seen on the tongue, lips, buccal mucosa and floor of the mouth at the lingual sulcus (Figure 10). Traumatic ulcers heal within 7 to 10 days but some persist for weeks to months due to constant traumatic insults and irritation or secondary infection [34].

### Squamous cell carcinoma

Squamous cell carcinoma is the most common oral malignancy and accounts for more than 90% of oral cancers. It can present as an exophytic, ulcerative, red, and white or a mixed lesion. It has a male

predilection over 40 years of age and most commonly with a history of tobacco or alcohol consumption. It presents as a non healing ulcer that can persist for days and weeks. It is usually asymptomatic and the patient is unaware till the lesion progresses.

The ulcerative SCC presents as a crater like lesion with rolled out margins and indurated border (Figure 11). Lips, floor of the mouth, lateral and ventral borders of the tongue are commonly involved. The lesion is usually solitary. The lesion is destructive and timely diagnosis and treatment is crucial in determining the prognosis of the patient.

### Traumatic ulcerative granuloma (Eosinophilic ulcer of the tongue)

Eosinophilic Ulcer (EU) or Traumatic Ulcerative Granuloma with Stromal Eosinophilia (TUGSE) is a chronic solitary ulcer of oral mucosa seen frequently in patients over 40 years of age but sometimes can be seen in children and young patients. The tongue is the most commonly involved site followed by the buccal mucosa, retromolar region, floor of the mouth and lips.

These are traumatic ulcers but the penetrating nature of inflammation results in myositis. Similar ulcers can be seen on the ventral tongue in infants when the tongue rasps against newly erupted primary incisors, a condition known as Riga-Fede disease [35].

The tongue is also the common site of involvement in adults, which presents as an ulcer that may not be painful in two-thirds of cases and may persist for months with a history of trauma in most of the cases. The ulcers are clean, punched out with surrounding erythema ranging from 0.5 cm to several centimeters in size. The surrounding tissue is usually indurated. Buccal mucosa, labial mucosa, floor of the mouth and vestibule and sites with abundant underlying skeletal muscle can also be involved. In some cases, the lesions present as an ulcerated, mushroom-shaped, polypoid mass on the lateral tongue [36].

Unlike RAS there is lack of pain and surrounding erythema. The presence of induration raises the suspicion for squamous cell carcinoma (especially if it is on the tongue) or other malignancy of salivary gland or lymphoid origin. Some cases that had been diagnosed as traumatic ulcerative granuloma have subsequently been shown to represent T-cell lymphomas.

### Pemphigus and pemphigoid

These lesions are a group of autoimmune, life threatening diseases that present with blisters and erosions of the skin and mucous membranes.

**Pemphigus:** Pemphigus vulgaris is the most common form of pemphigus, accounting for over 80% of cases. The antibodies are targeted against DSG3 (a transmembrane glycoprotein adhesion molecule present on desmosomes). When the lesion is confined to the mucosa and targeted against DSG1 and DSG3, when there is involvement of both the skin and the mucosa [37].

The oral lesions may start as a bulla which breaks to form shallow ulcers. A thin layer of epithelium peels away leaving a denuded basereferred as Nikolsky's sign named after Pyotr Nikolsky (1858–1940), a Russian physician [37]. The lesions are mostly seen along the occlusal plane on the buccal mucosa. Palate and gingiva are also other sites of involvement. The oral lesions are present for months before

the skin lesions (Figure 12).

These lesions can be misdiagnosed for herpes or candidiasis which can mask the clinical appearance of pemphigus. However, the duration of the lesion is important to differentiate from viral ulcers. If the lesion is treated early, there is chance for remission and control. It is also essential to distinguish these lesions from RAS. The lesions in the latter may be severe but heal and recur. The lesions in pemphigus extend over weeks to months. The lesions are not round and symmetric as seen in RAS.

**Pemphigoid:** Pemphigoid are broadly classified as mucous membrane and bullous pemphigoid. The auto antibodies are targeted against BP180 and BP230 seen at the basement membrane.

Oral lesions in bullous form occur in 30 to 50% of patients. The oral lesions are smaller, form slowly and are less painful than pemphigus. The gingiva is edematous, inflamed and shows desquamation with discrete vesicle formation (Figure 13). Early remission is seen in this form of pemphigoid.

The lesions of Mucous membrane pemphigoid present as desquamative gingivitis and the gingiva appears bright red mimicking erosive lichen planus and pemphigus. The lesions may present as vesicles on the gingiva or other mucosal surfaces [38]. But these lesions progress more slowly than pemphigus and are self limiting.

### Mucormycosis

Mucormycosis (phycomycosis) is an opportunistic infection caused by a saprophytic fungus normally occurring in soil or mold over decaying food. Infection occurs in patients with decreased host resistance, such as patients with poorly controlled diabetes, hematologic malignancies, those undergoing cancer chemotherapy or immunosuppressive drug therapy. The fungus invades arteries and causes damage secondary to thrombosis and ischemia. The fungus may spread from the oral and nasal region to the brain resulting in death in many cases.

The oral lesions present as ulcerations of the palate which result from necrosis due to invasion of a palatal vessels. The ulcer is large and deep causing denudation of underlying bone. The other oral sites involved are the gingiva, lip and alveolar ridge [39].

The dentist must include mucormycosis in the differential diagnosis of large oral ulcers occurring in patients debilitated from diabetes, chemotherapy, or immunosuppressive drug therapy.

### Tuberculous ulcers

Granulomatous diseases can cause ulcerative lesions in the oral mucosa. Oral manifestations of tuberculosis and leprosy can occur secondary to systemic presentations but are however rare.

Tuberculosis can be pulmonary or extra pulmonary. Pulmonary TB can be primary, secondary or miliary. Primary TB is usually seen in children. It is mostly asymptomatic sometimes with febrile illness and dry or productive cough. Oral lesions are uncommon and are secondary to primary disease. It is likely the organisms are carried in the sputum and enter the mucosal tissue through a small break in the surface. Oral manifestations of secondary tuberculosis may occur at any oral site, the tongue being the most commonly affected site. The other sites involved are the gingiva, floor of the mouth, palate, lips

and buccal mucosa.

The oral ulcers are chronic, indurated with irregular undermined edge and thick mucous material in its base. Tuberculous ulcers are painless, chronic in nature, are typically angular with over-hanging or undermined edges and a pale floor, but can be ragged and irregular which may often be painful [40].

The diagnosis of the infection can be confirmed with special microbial stains and culture of infected tissue or sputum. The presence of acid fast bacilli in the sputum is usually demonstrated for the diagnosis of tuberculosis. Chest radiographs and tuberculin test are supplemental in TB diagnosis. The demonstration of the tubercle bacilli in respiratory specimen is diagnostic of TB.

The differential diagnosis of tuberculous ulcer includes traumatic ulcer, syphilitic ulcer, and oral SCC. Biopsy of the ulcer can help determine the diagnosis and prognosis of the lesion.

### Syphilitic ulcers

Primary syphilitic ulceration usually occurs as a result of orogenital or oroanal contact with an infectious lesion. It rarely involves the oral cavity and it seldom diagnosed, due to its shorter duration.

A chancre develops on the lips, tongue, pharynx or tonsils as a solitary ulcer. The upper lip is more commonly affected in males and the lower lip in females, probably due to the anatomy involved with fellatio and cunnilingus. The ulceration is usually deep, with a red purple or brown base ragged rolled border and accompanied by cervical lymphadenopathy [1].

The differential diagnosis includes chronic traumatic ulcerations and squamous cell carcinomas. A detailed history of sexual and social life helps in proper diagnosis of these lesions.

Tertiary syphilis manifest as punched out ulcers on the tongue. Tertiary syphilis begins as a swelling, sometimes with a yellowish centre which undergoes necrosis, leaving a painless deep ulcer. The ulcer is rounded, with soft, punched-out edges. The floor is depressed and pale [1].

The diagnosis can be made by examining the exudates for spirochetes under a dark field microscope. Serological tests are highly sensitive and are specific such as fluorescent treponemal antibody absorption and *T.pallidumhaem* agglutination assays.

## Other Uncommon Ulcers

### Hand, foot, mouth disease

Hand, Foot, and Mouth Disease (HFMD) is a highly infectious viral disease usually affecting the infants and children usually below the age of 5 years. It is caused by coxsackievirus A16 and most commonly seen during summer. It is characterized by vesicles that are typically seen in the hands, feet and oral cavity [41].

Intraoral lesions may show vesicles that ulcerate presenting with erythematous halos or may sometimes appear as erythematous macules approximately 2mm in diameter [42]. The ulcers are seen usually on the tongue, palate, buccal mucosa, gums and lips. Oral lesions may cause drooling of saliva along with discomfort, making oral feeding difficult [43].

### Cyclic neutropenia

Cyclic neutropenia is a rare blood disorder of the neutrophils. There are recurrent episodes of abnormally low levels of neutrophils in the body. The lack of neutrophils increases the risk of oral infections such as stomatitis, periodontitis and recurrent, painful oral ulcerations affecting the tongue and palate. They are similar to major aphthous ulcers and heal with scarring in about 14 days [44].

### Radiation induced mucositis

Radiation is one of the treatment modality in the treatment of cancer. It may cause injury to the oral mucosa. The non keratinized mucosa, such as labial, buccal mucosa, floor of the mouth and soft palate are affected and presents as an erythema and progresses to solitary white elevated desquamative patches. Later, painful contiguous pseudo membranous lesions follow with associated dysphagia and decreased oral intake. Oral lesions usually heal within two to three weeks [45].

## Diagnosis

### Microbiological test

- Dark field microscopy is used to identify organism such as treponema that can help in establishing a diagnosis of syphilis.
- PCR can help in detection of HSV, CMV or *H.Pylori*.
- Quantiferon gold test is a gold standard test to confirm tuberculosis to rule out false negative result [46].

### Hematological test

- Cyclic neutropenia can be diagnosed by reduced count of neutrophils periodically.
- Blood glucose levels are done to assess anemias, nutritional deficiency and Diabetes that will help in the diagnosis or corresponding ulcers.
- Renal function tests are done to confirm with urea status related to uremic stomatitis.

### Bio-assay

- ELISA is used to find the proteins of suspected microorganism, whether the ulcer is healing or non healing, or due to certain immunological reasons (immunoglobulins), auto antibodies in crohn's disease, tissue specific antibodies, antisalivary duct antibodies, anti nuclear antibodies as in sjogren syndrome [47].
- Western blot is useful in diagnosis of microorganism and their pathogenic strains, sometimes proved to be more beneficial than ELISA in oral biological samples compared to serum.

### Cytological smear

- Cells such as Anitschkow cells are seen in smears taken from ulcers in inflammatory condition as in RAS. These are elongated cells with linear bar of chromatin extending towards nuclear membrane.
- A smear taken from the base of vesicle (tzank smear) showing the presence Tzank cells (acantholytic cells) can suggest a herpes virus infection or pemphigus.

### Histopathological test

- It is considered the gold standard test to confirm the

diagnosis, special stains can be used to confirm microorganism in case of suspicion to ulcer secondary to tuberculosis, syphilis, or mucormycosis.

- Necrotising sialometaplasia is confirmed by biopsy to rule out neoplasm.

### Specialised tests

- Immuno-histochemistry can be done to rule out non healing ulcer of squamous cell carcinoma and certain ulcers like TUGSE which does not show clear histopathological features but are strongly positive for CD 30.1
- Direct immunofluorescence showing binding of antibodies to intercellular substance can confirm Pemphigus.

## Management

Traumatic ulcers are treated initially by removing the etiological agent and observed for signs of remission. For painful ulcers, the surface is treated with fluocinonide or triamcinolone acetonide in an emollient base after meals and before bed time. This usually relieves pain and decreases duration of healing. Any ulcer not showing signs of healing for 2 weeks need biopsy to rule out malignancy by biopsy.

Mild cases of recurrent aphthous ulcers are treated with protective emollient like Orabase, topical anesthetic gel for pain relief. In more severe cases, the use of a high potency topical steroid preparation is advised, such as 1.5% cortisone acetate, hydrocortisone acetate, triamcinolone, fluocinonide, clobetasol cream, beclomethasone spray placed directly on the lesion shortens healing time and reduces the size of the ulcers, intralesional injection of triamcinolone acetonide for aphthous major ulcers. Other agents tried with varying levels of success include tetracycline mouth wash 250mg / 5ml four times daily for 5 to 10 days, chemical cauterizing agents reduces the pain but no other beneficial effect. For severe cases several systemic drugs have been used to treatment, including systemic corticosteroids steroids like prednisone 20-40 mg / day for week, half the dose for next week and then taper the dose gradual, dapsone (Tap Daps one 25/50/100mg), colchicine, thalidomide, pentoxifylline, low-dose interferon- $\alpha$  [48,49]. Levamisole, (Tab Dewormis, Vermisol, Diceris, 50/150mg) an anthelmintic drug that can modulate immune responses, has been used successfully as a monotherapy and as an adjunct to treatment in a variety of diseases. Because of its modulating effects on immune responses, levamisole has been used in a wide range of diseases with varying degrees of success [50].

For primary HSV Infection, aspirin or acetaminophen is administered for fever, IV fluids to maintain proper hydration and electrolyte balance, topical anaesthetics preferred before meals to reduce the difficulty during eating and drinking like (i) 0.5% dyclonine hydrochloride. (ii) 5 mg/ml diphenhydramine hydrochloride plus equal amount of milk of magnesia. (iii) 10% Benzocaine hydrochloride (Mucopain ointment). Acyclovir is prescribed as it reduces viral shedding and infectivity by inhibiting viral replication. HSV infections in immunocompromised hosts should be treated with systemic antivirals to prevent dissemination to other sites (e.g., HSV *esophagitis*). Recurrent herpetic lesions are self limiting and the use of topical antivirals reduces shedding, infectivity, pain, and the size and duration of lesions. The recommended systemic acyclovir for

adults is 200mg for 5 times a day for 5 days and for children below 2 years 100 mg 5 times a day for 5 days. For children above 2 years dose similar to adults. Regarding the treatment of herpes zoster Systemic acyclovir 800 mg 5 times daily is recommended and also Prednisone 40-60 mg/daily for one week to prevent post herpetic neuralgia in old patient. (ACIVIR 200 mg, 400 mg, 500 mg DT – Dispersible tablet) • Tab. Herperax 200 mg, Zovirax Tab. 200 mg, 100 ml suspension 400 mg/5ml, Ocuvir Tab. 200 mg, 400 mg, 800 mg)

In cases of mucormycosis, the ulcers are treated with a combination of surgical debridement of the infected area with systemic amphotericin B; other antifungal agents used are posaconazole and isavuconazole. The underlying predisposing factor must be addressed which may affect the outcome of the treatment.

The mild form of erythema multiforme can be managed with topical analgesics for pain, corticosteroids, antiseptic mouth washes, soft or liquid diet, intravenous rehydration and anti pyretic and supportive care. The disease is self limiting and resolves within a few weeks. Severe cases are treated with systemic corticosteroids prednisone 30-50 mg/day for one week and dose should be tapered and stopped.

Vesiculo bullous lesions like pemphigus and pemphigoid are treated with topical and systemic corticosteroids depending on the severity of symptoms or site and extent of involvement. If the treatment is started when the lesion is confined to oral mucosa, the prognosis is good. For full blown disease state systemic corticosteroids are indicated, Steroid sparing agents like Cyclosporine or azathioprine administered to reduce the dose of steroids. Combinations of topical and systemic steroids are preferred for pemphigus involving only the oral mucosa. Other recommended modalities are parenteral gold therapy, etretinate, dapsone and plasmapheresis.

## Summary

Ulcers are common in the oral cavity and patients tend to overlook the lesions if it does not cause discomfort. However, it is the utmost responsibility of the dentist to look into such lesions even during regular visits, counsel the patients and plan the treatment accordingly. Proper history taking including the personal history and a thorough clinical examination is must to rule out malignancy.

## References

1. Mortazavi H, Safi Y, Baharvand M, Rahmani S. Diagnostic features of common oral ulcerative lesions: An updated decision tree. *Int J Dent.* 2016; 2016: 1-14.
2. Muñoz-Corcuera M, Esparza-Gómez G, González-Moles MA, Bascones-Martínez A. Oral ulcers: clinical aspects. A tool for dermatologists. Part I. Acute ulcers. *Clinical and Experimental Dermatology.* 2009; 34: 289-294.
3. Wood NK, Goaz PW, editors. *Differential Diagnosis of Oral and Maxillofacial Lesions.* 1997; Mosby, St Luis, Mo, USA.
4. Greenberg MS, Glick M, Ship JA. *Burket's Oral Medicine.* 2008; BC Decker, Hamilton, Canada.
5. Dayakar MM, Pai PG, Madhavan SS. Tetracycline hydrochloride chemical burn" as self-inflicted mucogingival injury: A rare case report. *Journal of Indian Society of Periodontology.* 2012; 16: 282-285.
6. Neville BW, Damm DD, Allen CM, Bouquot JE. *Oral and Maxillofacial Pathology.* 2002; Saunders, St Luis, Mo, USA.
7. Suomalainen A, Törnwall J, Hagström J. CT findings of necrotizing



- sialometaplasia. *Dentomaxillofacial Radiology*. 2012; 41: 529-532.
8. Femopase FL, Hernández SL, Gendelman H, Criscuolo MI, López-de-Blanc SA. Necrotizing sialometaplasia: report of five cases. *Medicina Oral*. 2004; 9: 304-308.
  9. Roberts C. Genital herpes in young adults: changing sexual behaviours, epidemiology and management. *Herpes*. 2005; 12: 10-14.
  10. Kolokotronis, S. Doumas. Herpes simplex virus infection, with particular reference to the progression and complications of primary herpetic gingivostomatitis. *Clinical Microbiology and Infection*. 2006; 12: 202-211.
  11. Wald A, Zeh J, Selke S, Ashley RL, Corey L. Virologic characteristics of subclinical and symptomatic genital herpes infections. *N Engl J Med*. 1995; 333: 770-775.
  12. Woo SB, Lee SF. Oral recrudescence of herpes simplex virus infection. *Oral Surg Oral Med Oral Pathol Oral Radiol Endod*. 1997; 83: 239-243.
  13. Mueller NH, Gilden DH, Cohrs RJ, Mahalingam R, Nagel MA. Varicella Zoster Virus Infection: Clinical Features, Molecular Pathogenesis of Disease, and Latency. *Neurol Clin*. 2008; 26: 675-697.
  14. Mohan RPS, Verma S, Singh U, Agarwal N. Acute primary herpetic gingivostomatitis. *BMJ Case Reports*. 2013; 1-3.
  15. Hasan S, Jangra J, Choudhary P, Mishra S. Erythema Multiforme: A Recent Update. *Biomed Pharmacol J* 2018;11: 167-170.
  16. Ayangco L, Rogers RS. Oral manifestations of erythema multiforme. *DermatolClin*. 2003; 21: 195-205.
  17. Hu J, Kent P, Lennon JM, Logan LK. Acute necrotizing ulcerative gingivitis in an immunocompromised young adult. *BMJ Case Rep*. 2015; 1-4.
  18. Magan-Fernandez A, O'Valle F, Pozo E, Liebana J, Mesa F. Two cases of an atypical presentation of necrotizing stomatitis. *J Periodontal Implant Sci*. 2015; 45: 252-256.
  19. Enwonwu CO, Falkler WA, Idigbe EO. Oro-facial gangrene (noma/cancrumoris): Pathogenetic mechanisms. *Crit Rev Oral Biol Med*. 2000;11:159-171
  20. Stoopler ET, Musbah T. Recurrent aphthous stomatitis. *CMAJ : Canadian Medical Association Journal*. 2013;185: E240-E241.
  21. Bankvall M, Sjöberg F, Gale G, Wold A, Jontell M, Östman S. The oral microbiota of patients with recurrent aphthous stomatitis. *J Oral Microbiol*. 2014; 6: 10.
  22. Akintoye SO, Greenberg MS. Recurrent Aphthous Stomatitis. *Dental clinics of North America*. 2014; 58: 281-297.
  23. Aysin Kokturk. Clinical and Pathological Manifestations with Differential Diagnosis in Behçet's Disease, *Patholog Res Inte*. 2012.
  24. Keogan MT. Clinical Immunology Review Series: An approach to the patient with recurrent orogenital ulceration, including Behçet's syndrome. *Clin Exp Immunol*. 2009; 156: 1-11.
  25. Sudarshan R, Annigeri RG, Mamatha GP, Vijayabala GS. Uremic stomatitis. *Contemporary Clinical Dentistry*. 2012; 3: 113-115.
  26. Yuan Q, Xiong QC, Gupta M, López-Pintor RM, Chen XL, Seriwatanachai D, et al. Dental implant treatment for renal failure patients on dialysis: a clinical guideline. *International Journal of Oral Science*. 2017; 9: 125-132.
  27. Matricon J, Barnich N, Ardid D. Immunopathogenesis of inflammatory bowel disease. *Self Nonself*. 2010; 1: 299-309.
  28. König J, Wells J, Cani PD. Human Intestinal Barrier Function in Health and Disease. *Clinical and Translational Gastroenterology*. 2016; 7: 196.
  29. Woo VL. Oral Manifestations of Crohn's Disease: A Case Report and Review of the Literature. *Case Reports in Dentistry*. 2015.
  30. Silva MFA, Barbosa KGN, Pereira JV, Bento PM, Godoy GP, Gomes DQ de C. Prevalence of oral mucosal lesions among patients with diabetes mellitus types 1 and 2. *AnaisBrasileiros de Dermatologia*. 2015; 90: 49-53.
  31. Miguel F. Prevalence of oral mucosal lesions among patients with diabetes mellitus types 1 and 2. *An Bras Dermatol*. 2015; 90: 49-53.
  32. Blochowiak K, Olewicz-Gawlik A, Polańska A, Nowak-Gabryel M, Kocięcki J, Witmanowski H. Oral mucosal manifestations in primary and secondary Sjögren syndrome and dry mouth syndrome. *Advances in Dermatology and Allergology. PostępyDermatologii i Alergologii*. 2016; 33: 23-27.
  33. Margaix-Mu-oz M, Bagán JV, Poveda R, Jiménez Y, Sarrión G. Sjögren syndrome of the oral cavity. Review and update. *Med Oral Patol Oral Cir Bucal*. 2009; 14: E325-30.
  34. Ariyawardana Anura. Traumatic Oral Mucosal Lesions: A Mini Review and Clinical Update. *OHDM* 2014; 13.
  35. Van der Meij EH, de Vries TW, Eggink HF, de Visscher JG. Traumatic lingual ulceration in a newborn: Riga-Fede disease. *Ital J Pediatr*. 2012; 38: 20.
  36. Chavan SS, Reddy P. Traumatic ulcerative eosinophilic granuloma with stromal eosinophilia of tongue. *South Asian Journal of Cancer*. 2013; 2:144.
  37. Hammers CM, Stanley JR. Mechanisms of Disease: Pemphigus and Bullous Pemphigoid. *Annual review of pathology*. 2016;11: 175-197.
  38. Hasan S. Desquamative gingivitis - A clinical sign in mucous membrane pemphigoid: Report of a case and review of literature. *J Pharma Bioallied Sci*. 2014; 6:122-126.
  39. Manjunatha BS, Das N, Sutariya RV, Ahmed T. Mucormycosis of the hard palate masquerading as carcinoma. *Clin Prac*. 2012; 2: e28.
  40. Krawiecka E, Szponar E. Tuberculosis of the oral cavity: an uncommon but still a live issue. *Advances in Dermatology and Allergology/PostępyDermatologii i Alergologii*. 2015; 32: 302-306.
  41. Muppa R, Bhupatiraju P, Duddu M, Dandempally A. Hand, foot and mouth disease. *J Indian SocPedodPrev Dent*. 2011; 29: 165-167.
  42. Kashyap R-R, Kashyap R-S. Hand, foot and mouth disease - a short case report. *J Clin Exp Dent. Dentistry*. 2015; 7: e336-e338.
  43. Rao PK, Veena KM, Jagadishchandra H, Bhat SS, Shetty SR. Hand, Foot and Mouth Disease: Changing Indian Scenario. *Int J ClinPediatr Dent*. 2012; 5: 220-222.
  44. R. EbruTirali, ZeynepYalçinkaya-Erdemci, S. Burçak Çehreli. Oral findings and clinical implications of patients with congenital neutropenia: a literature review. *Turk J Pediatr*. 2013; 55: 241-245.
  45. Satish Kumar PS, Balan A, Sankar A, Bose T. Radiation Induced Oral Mucositis. *Indian J Palliat Care*. 2009; 15: 95-102.
  46. Çağlayan V1, Ak O, Dabak G, Damadoğlu E, Ketenci B, Ozdemir M, et al. Comparison of tuberculin skin testing and QuantiFERON-TB Gold-In Tube test in health care workers. *Tuberk Toraks*. 2011; 59: 43-47.
  47. Benedict C. Nwomeh, Hui-XiuLiang, KelmanCohen, Dorne R.Yager, et al. MMP-8 Is the Predominant Collagenase in Healing Wounds and Nonhealing Ulcers. *Journal of surgical research*. 1999; 81: 189-195.
  48. Burruano F, Tortorici S. Major aphthous stomatitis (Sutton's disease): etiopathogenesis, histological and clinical aspects. *Minerva Stomatol*. 2000; 49: 41-50.
  49. Vujevich J, Zirwas M. Treatment of severe, recalcitrant, major aphthous stomatitis with adalimumab. *Cutis*. 2005; 76: 129-132.
  50. Sun A, Wang JT, Chia JS, Chiang CP. Levamisole can modulate the serum tumor necrosis factor-alpha level in patients with recurrent aphthous ulcerations. *J Oral Pathol Med*. 2006; 35: 111-116.