

Case Report

Guided Surgery in a Full Arch Rehabilitation of an Edentulous Maxilla

Carneiro TAPN^{1*}, Oliveira MTF², Simamoto-Júnior P¹, de Paulo LFB², Neves FD¹ and Zanetta-Barbosa D²

¹Department of Occlusion, Fixed Prosthesis, and Dental Materials, School of Dentistry, Universidade Federal de Uberlândia, Brazil

²Department of Oral and Maxillofacial Surgery, School of Dentistry, Universidade Federal de Uberlândia, Brazil

*Corresponding author: Carneiro TAPN, Department of Oral and Maxillofacial Surgery, Universidade Federal de Uberlândia, Brazil

Received: July 06, 2016; Accepted: July 26, 2016;

Published: July 28, 2016

Abstract

Recently, dentistry has passed through many changes in clinical practice and technology has become more accessible and applicable. Many modern features were incorporated and have shown promising results. Consequence of these conceptual technological developments in implant treatment, the guided surgery appears as a good alternative. This technology is based on precise images of the bone anatomy, obtained by computed tomography and a personalized surgical guide that enables a flapless faster implant surgery. For many professionals it is still a distant, difficult and expensive technology. The purpose of this article is to demystify and clarify this concept, presenting a case with the placement of six dental implants for a maxillary full arch rehabilitation using a computer generated surgical guide. The guided surgery may be considered as a viable alternative for rehabilitation of edentulous jaws when provided within the correct indications.

Keywords: Dental implants; Guided surgery; Flapless implant surgery

Introduction

In last decades, the clinical dental practice has passed through many changes and technology has become more popular and applicable. Many modern features were incorporated and have shown promising results. The increase in popularity and hence demand of dental implants has encouraged the advancement in research and clinical practice, with the development in technology and improvement of the materials, bringing better clinical outcomes and patient compliance [1]. The improvement of imaging and the incorporation of computed tomography brought clearer and better anatomical structure images with real proportions and dimensions, turning the surgical planning into a more precise and accurate procedure. Through these three-dimensional images, associated to the concept of stereo lithography and CAD/CAM technology, it becomes possible to generate prototyped surgical guides with high accuracy [2].

Consequence of these conceptual and technological developments in implant treatment, the guided surgery is proposed. This technology is based on precise images of the bone anatomy, obtained by computed tomography. These images are then inserted into specific software for image manipulation, which allows the virtual implant surgery planning, where the position, diameter and its length can be planned according to the available bone [3]. The guided surgeries are indicated for the more variable types of rehabilitation with implants, including total or partial edentulous patients. In full arch rehabilitations, to obtain success with this therapy, achieving optimal aesthetic and functional results, a proper study on the selection of cases and careful planning is required [4].

Despite this, for many professionals it is still a distant, difficult and expensive technology, the purpose of this article is to demystify and clarify this concept. This study describes a clinical case with the placement of six dental implants for a full arch rehabilitation of the

maxilla with the aid of a computer generated surgical guide.

Case Presentation

A 62 years old male patient, presented for treatment at the Oral & Maxillofacial Surgery and Implant Dentistry department at Federal University of Uberlandia, seeking for full arch rehabilitation of the maxilla with dental implants. After clinical evaluation and interview, it was found that the patient had no deviation from normality and had no systemic diseases that could alter the tissue integration. The patient's upper denture was in good condition, with mandibular prostheses as antagonist (Figure 1).

The patient underwent radiographic imaging exams, with cone bean CT scan. From the CT scan, it was possible to observe proper bone availability of the superior alveolar ridge, and the absence of any bone pathology (Figure 2). Thus, the CT images were exported to specific software (Dental -slice - Bioparts, Brasília, Brazil) where virtual simulation of implant placement was performed (Figure 3). Then, it was selected the optimal diameters and lengths of the 6 (six) planned implants for rehabilitation. Then a computer generated surgical guide based on virtual planning was manufactured using stereo lithography technology.

Under local anesthesia by blocking the upper, middle and anterior

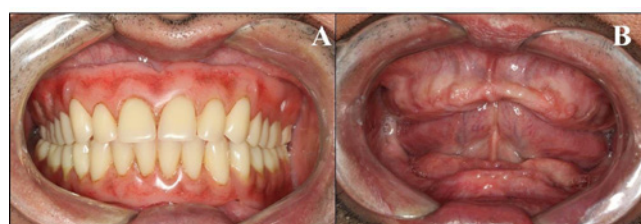


Figure 1: Initial condition of the patient. A) Patient using both maxillary and mandibular complete dentures. B) Intra-oral aspect without the complete dentures.

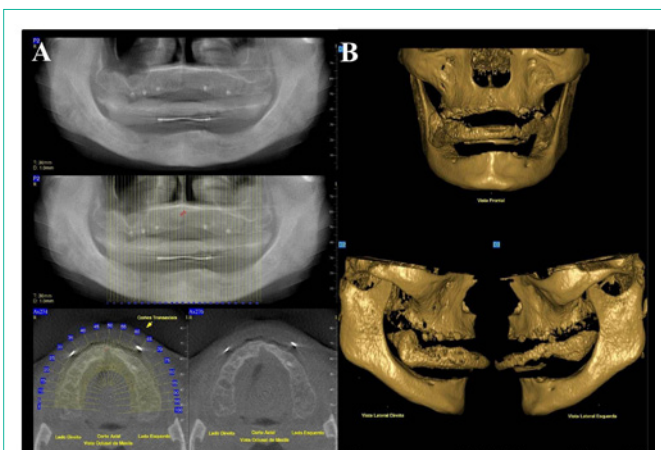


Figure 2: Imaging exams. A) Panoramic radiography. B) Tomographic images of the lower and middle third of the face.

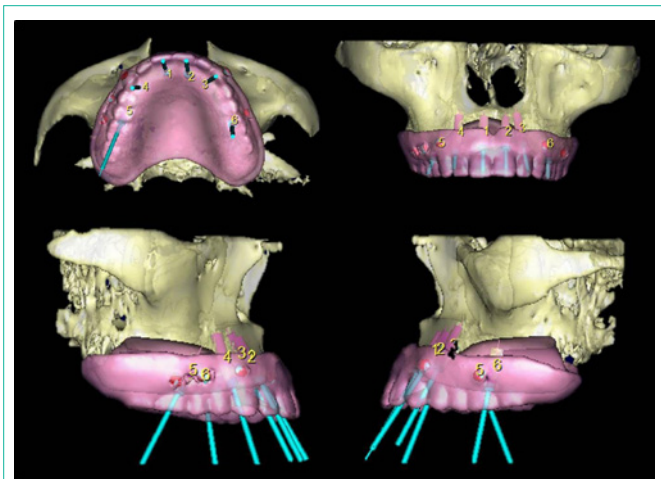


Figure 3: Virtual surgical planning using the specific software.

alveolar nerves, and also the greater and lesser palatine nerves, the surgical guide was positioned and fixed with pins to stabilize the guide. To implement the technique, a specific surgical kit (Neoguide - Neodent, Curitiba, Brazil) was used. After stabilization of the guide, the mucosa was removed only in the areas where the implants had to be placed. For this, was used a circular scalpel coupled to the hand piece. Then, was started the bone drilling instrumentation using a 2 mm guided drill, followed by the 2.8 mm instrumentation, only in the entrance of the perforation, to increase the primary stability. After the planned instrumentation, Morse Tapered implants Titamax EX - Neodent, Curitiba, Brazil) were placed following the same sequence of instrumentation. The implants were distributed in the areas of central incisor, canine and first molar for both sides (Figure 4).

After implant placement, the surgical guide was then removed and held the installation of the respective abutments (Mini-Pilar - Neodent, Curitiba, Brazil), after the recommended torque by the manufacturer, provisional titanium sleeves were installed and proceeded the capture of the full removable denture and transforming this into an implant-supported prostheses (Figure 5). The final radiograph showed a very good accuracy of the implant placement when compared to the virtual panning (Figure 6).

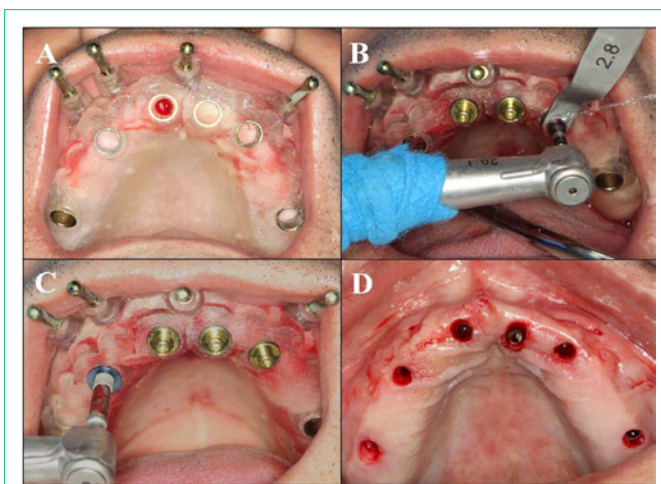


Figure 4: A) Surgical guide placement. B) Guided drilling following the virtual planning. C) Implant placement using the surgical guide. D) Immediate post-operative condition after flapless guided surgery.

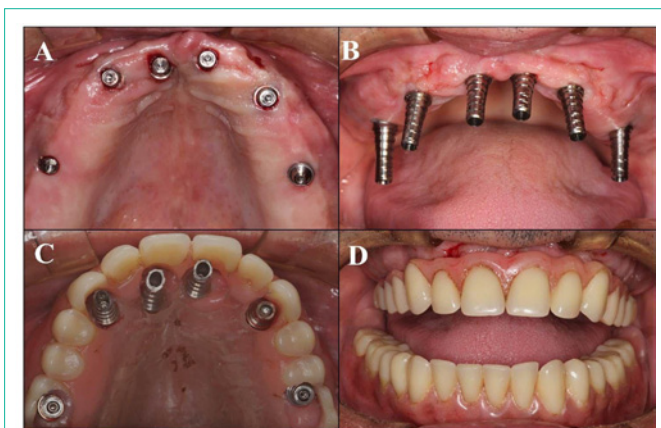


Figure 5: A) Abutment placement over the implants. B) Titanium sleeves installation. C) Preparation of the maxillary complete denture for immediate capture in the mouth. D) Maxillary immediate rehabilitation with the transformation of the removable complete denture into implant-supported hybrid prostheses.

Discussion

Major advantages over conventional techniques have been reported by several authors, showing that performing the surgery using the prototyped guide, without incision and flap opening, better postoperative results are observed when compared to conventional surgery [5,6]. In the present case, the patient showed a comfortable postoperative result without the need of analgesics.

It is important to observe the patient’s mouth opening, it is necessary between 4 and 5 cm to compensate the surgical guide thickness and the length of the cutters [6]. It is also very important to note the amount of keratinized mucosa as well as the resilience of the soft tissues where the implants will be placed. For aesthetic and functional resolutions with optimized results, the full arch rehabilitations needs a well-executed reverse planning, the prosthesis has to be designed respecting a protocol official aesthetic analysis and information obtained from the patient, such as smiling line, facial symmetry and proportions, dental proportions and color, among

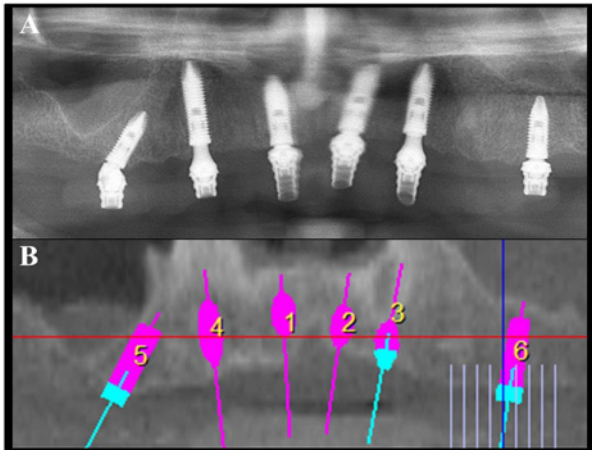


Figure 6: Postoperative CT scan in comparison to the virtual planning.

others [7]. Based on that, was suggested the option of implant-supported fixed prosthesis with discrete vertical compensation [4], anchored in six implants placed by guided surgery.

During surgery, the guide should not have any kind of movement or weighbridge, it is necessary to keep perfectly adapted, avoiding the possibility of positional changing during the surgery, a major cause of failure during this kind of surgery is related to this issue⁵. It is recommended the use of local anesthetic techniques lock away from areas where the guide will be based, aiming to avoid mismatches due to edema caused by excessive anesthetic solution in the region.

Clinical studies have shown that the success rate of implants in guided surgery is very similar to that one's placed with conventional technique, with high absolute survival rate around 95% [8]. The guided surgery brings an important contribution to the prosthetic resolution, decreasing compensation of the dental implant position related original lost teeth, with previsualization of the prosthesis related to available bone before the implant placement. This protocol allows the simplification of the procedure for both patient and clinical team. Because of being a minimally invasive and flapless procedure, the technique consumes less time and has less postoperative morbidity, bleeding and a high satisfaction degree of the patients [6,8,9].

A recent study concluded that the inexperience of the executor surgeon has no influence on the accuracy of implant placement in edentulous jaws, when all steps needed for the procedure are supervised by experienced dentists [10]. The accuracy of this concept depends on several factors, from dataset acquisition to the surgical procedure. A recent published meta-analysis of the in vitro and in vivo studies revealed a total mean error of 1.12 mm at the entry point and 1.39 mm at the apex [11].

Although it appears extremely simple to perform, requires technical expertise of the involved staff and detailed planning to avoid

any complication during the procedure. The guided surgery may be considered as a viable alternative for rehabilitation of edentulous jaws when provided within the correct indications. The highlight of this technique is the mandatorily detailed planning done prior to the surgery that must be executed in all the clinical situations guided or not.

Conclusion

The expected results were obtained and the patients expectations were met, the torques for immediate installation of a maxillary complete denture were achieved and implant positioning on postoperative imaging showed accuracy and fidelity to the virtual planning made previously on the computer.

References

1. Patel N. Integrating three-dimensional digital technologies for comprehensive implant dentistry. *J Am Dent Assoc.* 2010; 141: 20-24.
2. Wohllers T. Rapid prototyping & tooling, state of industry annual. Word wide Progress Report. Wohler's Associates. 2004.
3. Ganz SD. Presurgical planning with CT-derived fabrication of surgical guides. *J Oral Maxillofac Surg.* 2005; 63: 59-71.
4. Neves FD, Mendonça G, Fernandes Neto AJ. Analysis of influence of lip line and lip support in esthetics and selection of maxillary implant-supported prosthesis design. *J Prosthet Dent.* 2004; 91: 286-288.
5. Sarment DP, Sukovic P, Clinthorne W. Accuracy of implant placement with a stereolithographic surgical guide. *Int J Oral Maxillofac Implants.* 2003; 18: 571-577.
6. van Steenberghe D, Glauser R, Blomback U, Andersson M, Schtyser F, Pattersson A, et al. A computed tomographic scan-derived customized surgical template and fixed prosthesis for flapless surgery and immediate loading of implants in fully edentulous maxillae: a prospective multicenter study. *Clin Implant Dent Relat Res.* 2005; 1: 111-120.
7. Garber DA, Salama M. The aesthetic smile: diagnosis and treatment. *Periodontol.* 2000; 11: 18-28.
8. Sanna AM, Molly L, Van Steenberg D. Immediately loaded CAD/CAM manufactured fixed complete dentures using flapless implant placement procedures a cohort study of consecutive patients. *J Prosthet Dent.* 2007; 97: 331-339.
9. Malo P, de AraujoNobre M, Lopes A. The use of computer-guided flapless implant surgery and four implants placed in immediate function to support a fixed denture: preliminary results after a mean follow-up period of thirteen months. *J Prosthet Dent.* 2007; 97: 26-34.
10. van de Wiele G, Teughels W, Vercruyssen M, Coucke W, Temmerman A, Quirynen M. The accuracy of guided surgery via mucosa-supported stereolithographic surgical templates in the hands of surgeons with little experience. *Clin Oral Implants Res.* 2014.
11. Tahmaseb A, Wismeijer D, Coucke W, Derksen W. Computer technology applications in surgical implant dentistry: a systematic review. *Int J Oral Maxillofac Implants.* 2014; 29: 25-42.