

## Case Report

## Zimmermann Laband Syndrome: A Rare Case Report

Afsar A<sup>1\*</sup>, Gupta R<sup>2</sup>, Dahiya P<sup>3</sup> and Gupta M<sup>4</sup><sup>1</sup>MDS 3rd Year Student, Department of Periodontics, Himachal Institute of Dental Sciences, HP, India<sup>2</sup>MDS, Professor and Head of Department of Periodontics, Himachal Institute of Dental Sciences, HP, India<sup>3</sup>MDS, Professor, Himachal Institute of Dental Sciences HP, India<sup>4</sup>MDS, Professor, DAV Dental College, Yamunanagar, India**\*Corresponding author:** Afsar A, MDS 3rd Year Student, Department of Periodontics, Himachal Institute of Dental Sciences, HP, India**Received:** June 08, 2022; **Accepted:** July 05, 2022;**Published:** July 12, 2022

## Introduction

Gingival enlargement is the overgrowth of the gingiva characterized by an expansion and accumulation of the connective tissue with occasional presence of increased number of cells. It is caused by several factors, such as inflammation, leukemia, drugs, and inheritance. The inheritance condition in which the gingival tissue spontaneously and progressively enlarges is identified as hereditary gingival fibromatosis (HGF) [1].

Zimmermann-Laband Syndrome (ZLS) is a very rare condition characterized by gingival fibromatosis, coarse facial appearance and malformed nails or distal phalanges of hands/feet and sometimes hepatosplenomegaly. The term Zimmermann-Laband Syndrome was for the first time given by Carl Jacob Witkop [2]. It was found that there is mutations in KCNH1 and ATP6V1B2 occurs which causes Zimmermann-Laband syndrome.

Most commonly it is associated with local or diffuse non-hemorrhagic gingival enlargement. The underlying alveolar bone is not directly influenced by gingival hyperplasia, but the gingival excess can allow plaque accumulation, causing biofilm-induced gingivitis, pseudo pockets, caries, and halitosis and there is failure of deciduous and permanent tooth eruption often occurs [3]. The most common extra oral clinical features present in this condition are bulbous soft nose, thick floppy ears, nail aplasia or hypoplasia, hypertrichosis, joint hyperextensibility, hepatosplenomegaly, and intellectual disability with or without epilepsy [4].

## Case Report

A 14-year-old male patient was reported to the hospital with the chief complaint of increase in thickness of the gums and no visibility of teeth in the upper and lower anterior region causing difficulty in chewing and also an unpleasant smile. During history examination it was revealed that the increase in size starts 1 year ago had reached the present size. There was no familial history elicited during examination. On general examination the child was systemically healthy and was not on any medication.

## Abstract

The Zimmermann Laband Syndrome was first described by Zimmermann in the year 1928. It is an extremely rare autosomal dominant congenital disorder. It is mainly characterized by gingival fibromatosis, multiple unerupted teeth, coarse facial appearance, hypertrichosis and sometimes hepatosplenomegaly. The characteristics are highly variable. The present case report is of a 14 year old boy who was diagnosed as Zimmermann Laband Syndrome based on the classical sign of gingival overgrowth.

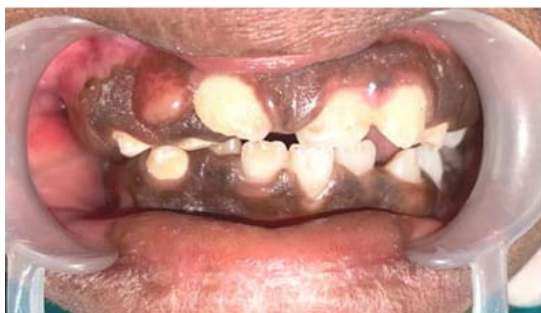**Keywords:** Zimmermann; Hypertrichosis; Hyperplasia; Enlargement; Dentistry

On intraoral examination of patient it was observed that there was thick enlargement of maxillary and mandibular gingiva and all the four quadrants were involved. There was minimal bleeding on probing was present and the teeth present were partially or fully covered with gingival overgrowth. Also there were multiple carious teeth and presence of plaque and calculus. During extra oral observation there was increase in the size of the lips which gives prominent labial fullness. Patient's nose was bulbous and ears were folded including the feature of hypertrichosis as shown in (Figure I and II).

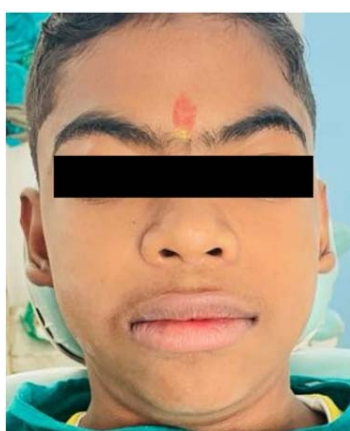For radiographic examination panoramic x-ray was advised and it was observed there were multiple retained deciduous teeth were present. A picture of mixed dentition with no underlying bone abnormality was observed on OPG as shown in (Figure III). On normal blood examination, the values were in normal range without any abnormality. For the detection of hepatosplenomegaly abdomen ultrasonography was advised and it was observed that liver and spleen were found within normal range but there was presence of renal obstruction. On histological examination gingival tissue showed hypertrophy of stratified squamous epithelium with elongated rete pegs. There were dense bundles of collagenous fibrous tissue beneath the epithelium. The child was diagnosed with Zimmermann Laband Syndrome based on clinical features as shown in (Figure IV and V).

Treatment was planned according to the chief complaint to improve esthetic of the child. In initial phase of the treatment deep scaling was done and oral hygiene instructions were given. After two weeks of maintenance phase surgical removal of the tissue including gingivectomy, gingivoplasty as well as osteoplasty wherever required was done. During surgical phase retained deciduous teeth were extracted simultaneously to facilitate the eruption of embedded permanent teeth. Surgery was done under local anesthesia and excised tissue was sent for histologic examination. Patient was prescribed with anti-inflammatory analgesic medication and with chlorhexidine mouthwash after every surgical phase.

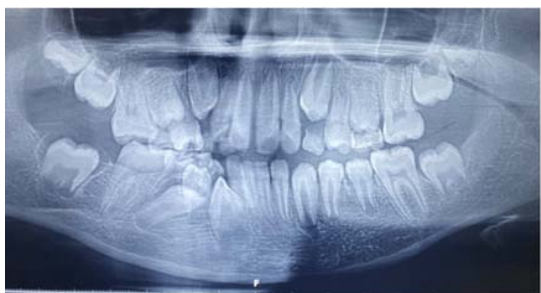Postoperative photographs showed esthetic improvement. Patient was kept on oral hygiene instructions and periodically recalled for



**Figure I:** Pre operative intraoral picture showing enlargement.



**Figure II:** Picture of extraoral feature showing hypertrichosis, thick lips and bulbous nose.

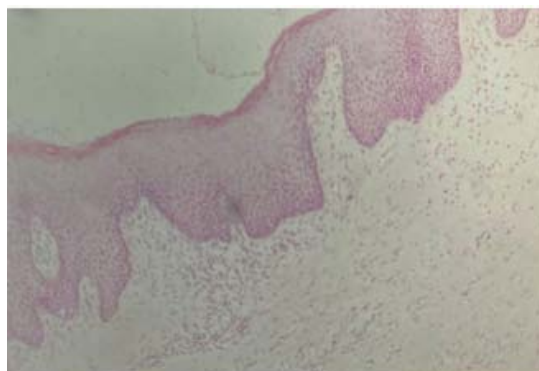


**Figure III:** Radiographic picture showing mixed dentition.

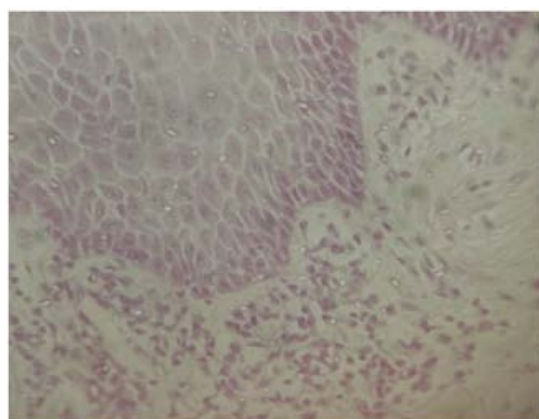
maintenance therapy as shown in (Figure VI).

## Discussion

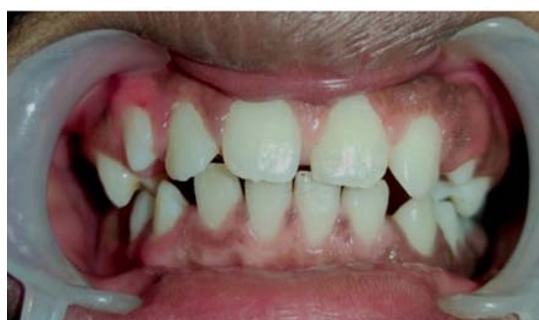A rare syndrome known as Zimmermann-Laband Syndrome or Laband's syndrome was first reported by Zimmermann (1928) [5]. It is an autosomal dominant disease characterized by a triad of extensive gingival enlargement (gingival fibromatosis), abnormalities of the nose and ears, absence or hyperplasia of the nails or terminal phalanges of the hands and feet. The most common facial features are marked gingival fibromatosis, thick, floppy ears, and bulbous soft nose [2]. A total of forty cases have been reported till 2010 [5]. It was seen that there is heterozygous missense mutations in *KCNH1* account for a significant proportion of ZLS [4]. This syndrome is coded with phenotype MIM number 135500. The gene responsible for



**Figure IV:** Histopathologic picture showing hyperplasia of epithelium at 10X.



**Figure V:** Histopathologic picture showing dense connective tissue at 40X.



**Figure VI:** Post operative picture after surgical excision after 3 months.

Zimmermann-Laband syndrome is located in 3p14.3 and implicates four likely candidate genes in this region.

This syndrome is not a life-threatening disorder. During the diagnosis of generalized gingival enlargement, a detailed medical and systemic history should be evaluated to differentiate gingival fibromatosis from other types of acquired generalized gingival enlargement such as during the pregnancy, leukemia, and in case of drug reactions such as phenytoin, diltiazem, cyclosporine, verapamil, and nifedipine [5].

Shah and Gupta reported a case of Zimmermann-Laband syndrome in a young child of age 3½ years associated with bilateral

**Table 1:** Showing reported case of syndrome with most common clinical feature.

Case reports of zimmermann syndrome	Common clinical features
1. Bakeen G (1991) [8]	Gingival fibromatosis, enlarged nose, no hepato-splenomegaly.
2. Shah N (2004) [6]	Massive gingival overgrowth, thick lips, fleshy nose, no hepato-splenomegaly.
3. Sawaki K (2012) [7]	Gingival overgrowth, fleshy nose, malformed external earlobes, no hepato-splenomegaly.
4. Manoj K (2013) [5]	Excessive growth of gingival tissue, hypertrichosis, bulbous nose, no signs of hepato-splenomegaly.
5. Castori M (2013) [9]	Gingival overgrowth in maxilla and mandible.
6. Lal V (2018) [2]	Excessive growth of gingiva, bulbous nose and increase in size of the lips, no signs of any abnormality in the size of liver as well as the spleen.
7. Reddy M (2018) [10]	Gingival enlargement of the maxillary and mandibular gingival, multiple carious teeth, prominent labial fullness, no hepato-splenomegaly.
8. Guglielmi F (2019) [3]	Hypertrophy of gingival, a delay in dental eruption.

developmental cataract [6]. Sawaki et al. stated that the major clinical findings of Zimmermann–Laband syndrome would be gingival fibromatosis, hyperplasia or absence of the terminal pharynx or nails of hand and feet, bulbous soft nose, thick lips, large ears, and enlargement of soft tissues of the face [7]. In most case reports the common feature is gingival enlargement which is listed in (Table 1).

In this present case extraction of the deciduous teeth followed by internal bevel gingivectomy with osseous recontouring was done which was beneficial to improve the facial esthetics. Orthodontic intervention where, ever required will be planned after complete eruption of permanent dentition.

## Conclusion

With summary, it is concluded that zimmermann syndrome is not a life-threatening condition and a surgical correction can improve the esthetics of the patient. A periodic regular checkup should be maintained to prevent any further functional and esthetic complication.

## References

- Coletta RD, Graner E. Hereditary Gingival Fibromatosis: A Review. *J Periodontol.* 2006; 77: 753-764.
- Lal V, Panwar M, Kumar S, Kosala M. Zimmermann-Laband syndrome: A Rare Case Report. *J Interdiscipl Med Dent Sci.* 2018; 6: 1-3.
- Guglielmi F, Staderini E, Iavarone F, Tonno LD, Gallenzi P. Zimmermann-Laband-1 Syndrome: Clinical, Histological, and Proteomic Findings of a 3-Year-Old Patient with Hereditary Gingival Fibromatosis. *Biomedicines.* 2019; 7(3): 48. doi:10.3390/biomedicines7030048.
- Kortüm F, Caputo V, Bauer CK, Stella L, Ciolfi A, Alawi M, et al. Mutations in *KCNH1* and *ATP6V1B2* cause Zimmermann-Laband syndrome. *Nature Genetics.* 2015; 47(6): 661-667. doi:10.1038/ng.3282.
- Mallela MK, Moogala S, Polepalle LT, Reddy VC. Zimmermann-Laband syndrome: A rare case report of father and son. *J Dr. NTR Uni Health Sci.* 2013; 2: 147-149.
- Shah N, Gupta YK, Ghose S. Zimmermann-Laband syndrome with bilateral developmental cataract - a new association?. *International journal of paediatric dentistry.* 2004; 14(1): 78-85. doi:10.1111/J.1365-263X.2004.00471.X.
- Sawaki K, Mishima K, Sato A, Goda Y, Osugi A, Nakano M. Zimmermann-Laband syndrome: a case report. *The Journal of clinical pediatric dentistry.* 2012; 36(3): 297-300. doi:10.17796/JCPD.36.3.K854128176U764L8.
- Bakaeen G, Scully C. Hereditary gingival fibromatosis in a family with the Zimmermann-Laband syndrome. *Journal of oral pathology & medicine: official publication of the International Association of Oral Pathologists and the American Academy of Oral Pathology.* 1991; 20(9): 457-459. doi:10.1111/J.1600-0714.1991.TB00438.X.
- Castori M, Valiante M, Pascolini G, Leuzzi V, Pizzuti A, Grammatico P. Clinical and genetic study of two patients with Zimmermann-Laband syndrome and literature review. *European journal of medical genetics.* 2013; 56(10): 570-576. doi:10.1016/j.ejmg.2013.08.004.
- Reddy M, Mehete V, Gir PJ, Ranmare V. An Extremely Rare Presentation of Zimmermann–Laband Syndrome in a Twin. *Annals of Maxillofacial Surgery.* 2018; 8(2): 352. doi:10.4103/ams.ams\_203\_17.