

Case Report

Prosthetic Rehabilitation of a Patient with Ameloblastoma using an Unconventional Cast Partial Denture

Ferreira AN*, Aras M, Chitre V and Mascarenhas K

Goa Dental College and Hospital, Bambolim, Goa, India

*Corresponding author: Amanda Nadia Ferreira, Goa Dental College and Hospital, Bambolim, Goa, India

Received: April 04, 2018; Accepted: May 07, 2018;

Published: May 14, 2018

Abstract

This case report describes the prosthodontic rehabilitation of a patient with a previous history of follicular ameloblastoma, in the third quadrant which was treated by marginal resection of the mandible and an immediate replacement of missing bone with an iliac crest bone graft. An unconventional Cast partial denture design was used, due to the complete obliteration of the labial vestibule and the limited amount of mesio-distal space for the placement of the denture teeth.

Keywords: Ameloblastoma; Denture teeth; Obliteration

Introduction

Ameloblastoma of the jaw is an aggressive benign tumor of epithelial origin. It is the most common odontogenic neoplasm affecting the jaws, yet it accounts for only 1% of all tumors of the maxilla and mandible [1-3]. Men and women are equally affected [4] with a peak incidence in the 3rd-4th decade of life. The most common site for ameloblastoma is mandibular (80%) region, and the remaining in the maxillary region (20%).

Ameloblastomas can be classified as solid/multicystic, intraosseous or unicystic, with peripheral subtypes [5,6] even though it is a benign tumor, it is treated aggressively because of the myeloid nature of its growth. Primary resection is considered as the only predictable treatment option [6-10]. This leaves the patient with a defect in the affected site and impaired swallowing, speech, saliva, mastication, and cosmesis. The rehabilitation of such a patient poses a serious challenge to the prosthodontists as well as the laboratory personnel.

Case Presentation

A 53 year old patient was referred to the department of Prosthodontics for the replacement of missing teeth. The patient's medical/dental history referred to three recurrences of a tumor, which was classified as unicystic mural ameloblastoma. The tumor was located in the posterior right mandibular region encompassing six teeth, specifically the lateral incisor, canine, first and second premolars and the first and second molar. Excision of the lesion was carried out followed by the marginal resection of the mandible and immediate placement with an iliac crest bone graft and stabilized with miniplates. All six teeth were removed along with the tumor. Intra oral examination revealed several missing teeth 36, 42, 43, 44, 45, 46, 47. There was reduced mesio-distal space for the replacement of 36, also a complete obliteration of the labial vestibule in the defect site was seen. 48 were severely lingually tilted. There was a tori in the anterior lingual vestibule (Figure 1).

After extra and intra-oral examination, the treatment plan was

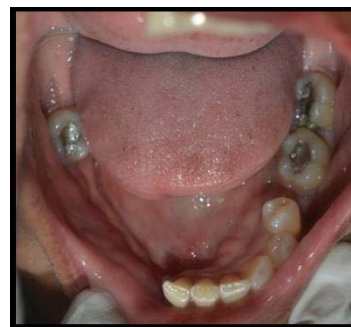

Figure 1: Mandibular dental arch.

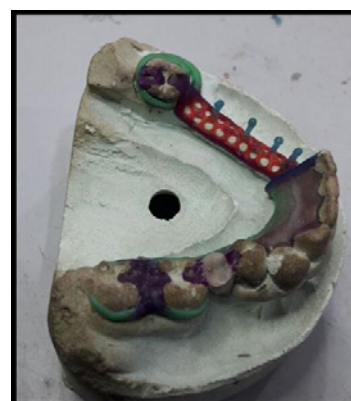

Figure 2: Wax pattern fabricated.

discussed with the patient. An implant-retained prosthesis was suggested to the patient because of the increased retention, stability and support. However due to financial constraints, the patient opted to carry out the rehabilitation with a cost effective, conventional method. The conventional cast partial denture (CPD) needed to be modified to account for the absence of the labial vestibule




Figure 3: Framework cast in cobalt chromium alloy.

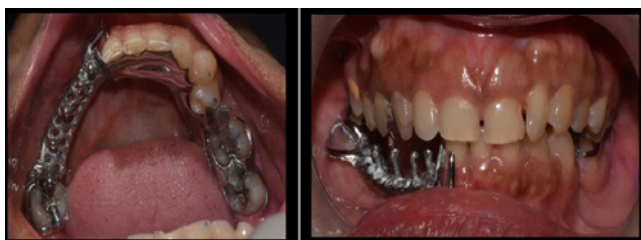

Figure 4: Framework fit verified.

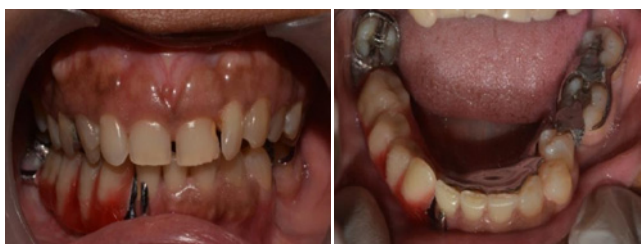

Figure 5: Try in.

Treatment Procedure

Preprosthetic treatment included the surgical removal of the torus mandibularis as it would hinder the path of placement and removal of the cast partial denture. Diagnostic impressions were made and diagnostic casts were obtained. The diagnostic cast was surveyed to identify the most desirable path of placement with minimal interferences, distinguish proximal surfaces which will act as guide planes and establish and measure undercuts.

The CPD design included a lingual plate as a major connector, a ring clasp on 48 to accommodate for the severe lingual tilt. An I bar on 42, an embrassure clasp on 36, 37. A metal pontic with porcelain veneered facially was planned to replace 36 and included in the metal framework due to the limited Mesio-distal space. Vertical struts (4-5mm) were made on the minor connector for additional retention onto which tube teeth were to be fitted, to compensate for the complete obliteration of the buccal vestibule.

Mouth preparations were done for various cast partial components and an impression was made of the mandibular arch with addition silicone (Aquasil, Dentsply) using the two step putty wash technique. The master cast was poured in type IV die stone (Kalabhai) and surveyed to ascertain and check parallelism of guide planes, survey lines and useful undercuts in final designing of the framework. Block out procedure was done and the cast was duplicated in reversible

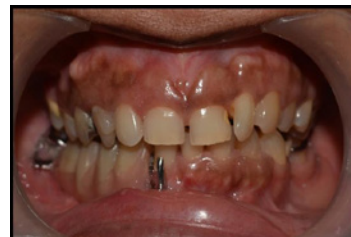

Figure 6: Final CPD insertion.

hydrocolloid material and poured with refractory material (Wirovest, BEGO). Wax pattern fabrication using stippled, grid retention and the beading wax (Figure 2). The CPD was cast in a conventional manner (Figure 3). The finished metal framework was tried in the patient's mouth to assess the fit and availability of interarch space (Figure 4). Wax rims were adjusted to record the vertical dimension. Casts were mounted in centric relation. The acrylic teeth were arranged in a mutually protected occlusal scheme. Shade was selected for the denture teeth and the veneering porcelain on 36. Try in was done and fabricated denture was inserted (Figure 5 and 6).

The radio graphical examination after two year revealed no reoccurrence of the lesion. Clinical examination showed that the patient was maintaining satisfactory oral hygiene. The patient was extremely satisfied with the cast partial denture.

Discussion

The treatment of a patient with cancer of the mandible may include surgery, radiation therapy, chemotherapy, or a combination of these modalities. The extent of surgery interrupts mandibular continuity and leads to facial disfigurement and mandibular function impairment but maintaining continuity helps preserve normal muscle function and facial contours and leads to better rehabilitation of prosthesis. For this patient, a fixed partial denture (FPD) was not suitable, as it would have resulted in overly long pontics compromising the biomechanics of the prosthesis. Hence, considering the reoccurrence rate of the ameloblastoma and financial status, an unconventional CPD was used to rehabilitate Kennedy Class III. The inclusion of the pontic in the CPD design, and the incorporation of the ring clasp on the severely tilted mandibular molar, was a conservative approach as it prevented the need for intentional root canal therapy and tooth preparation of the abutment teeth. The vertical struts included in the minor connector design were used to support the denture bases which had excess length as a result of mandibular resection on right side.

References

1. Gorlin RJ, Chaudhry AP, Pindborg JJ. Odontogenic tumors: Classification, histopathology clinical behaviour in man and domesticated animals. *Cancer*. 1961; 14: 73–101.
2. Adekeye EO. Ameloblastoma of jaws: A survey of 109 Nigerian patients. *J Oral Surg*. 1980; 38: 36–41.
3. Adekeye EO, Lavery KM. Recurrent ameloblastoma of the maxillofacial region. Clinical features and treatment. *J Maxillofac Surg*. 1986; 14: 153–157.
4. Reichart PA, Philipsen HP, Sonner S. Ameloblastoma: biological profile of 3677 cases. *Eur J Cancer B Oral Oncol*. 1995; 31: 86–99.
5. Ghandhi D, Ayoub AF, Pogrel MA, MacDonald G, Brocklebank LM, Moos KF. Ameloblastoma: a surgeon's dilemma. *J Oral Maxillofac Surg*. 2006; 64: 1010–1014.

6. Carlson ER, Marx RE. The ameloblastoma: primary, curative surgical management. *J Oral Maxillofac Surg.* 2006; 64: 484–494.
7. Peterson LJ, Ellis E, Hupp J, Tucker MR. Contemporary oral and maxillofacial surgery. St. Louis: Elsevier Health Sciences. 2002: 345–357.
8. Shatkin S, Hoffmeister FS. Ameloblastoma: a rational approach to therapy. *Oral Surg Oral Med Oral Pathol.* 1965; 20: 421–435.
9. Sehdev MK, Huvos AG, Strong EW, Gerold FP, Willis GW. Ameloblastoma of maxilla and mandible. *Cancer.* 1974; 33:324–333.
10. Müller H, Slootweg PJ. The ameloblastoma, the controversial approach to therapy. *J Maxillofac Surg.* 1985; 13: 79–84.