

Prospective

Simplified Impression Technique for Asymmetric Mandibular Arches

Singh H^{1*}, Sharma P¹, Pranav K¹ and Maurya RK²

¹Department of Orthodontics and Dento-facial Orthopedics, ESIC Dental College and Hospital, India

²Dental officer & Orthodontist, Bhopal Military Station, India

*Corresponding author: Harpreet Singh, Department of Orthodontics and Dento-facial Orthopedics, ESIC Dental College and Hospital, India

Received: September 12, 2015; Accepted: September 15, 2015; Published: September 18, 2015

Introduction

Patients with facial asymmetry often present with varying degrees of in the size and shape of upper and lower dental arches, and in the position of teeth on either side of the dental arch. A morphogenetic pattern of these patients tends to result in abnormal maxillary and mandibular bony architectures [1]. In such patients with grossly asymmetric mandibular arches, obtaining good lower impressions with conventional lower stainless steel trays is often difficult (Figure 1) since the process requires precise adjustment of flanges of the

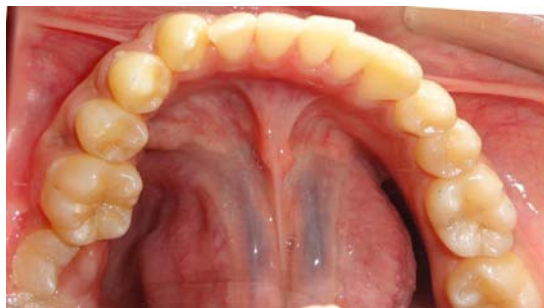

Figure 1: Intraoral occlusal view showing asymmetric mandibular arch form.

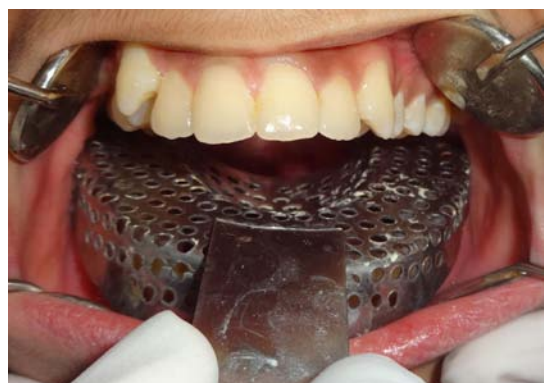

Figure 2: Intraoral view showing correct positioning of maxillary dentulous tray for taking impression of the mandibular arch.

Abstract

Accurate impression taking in patients with asymmetric mandibular arches and limited mouth opening often poses a challenge to the orthodontist. This article proposes a simple, yet effective impression technique using conventional upper stainless steel tray (with minimal or negligible adjustment) for taking the impression of asymmetric mandibular dental arches.

Keywords: Arches; Asymmetric; Impression; Mandibular

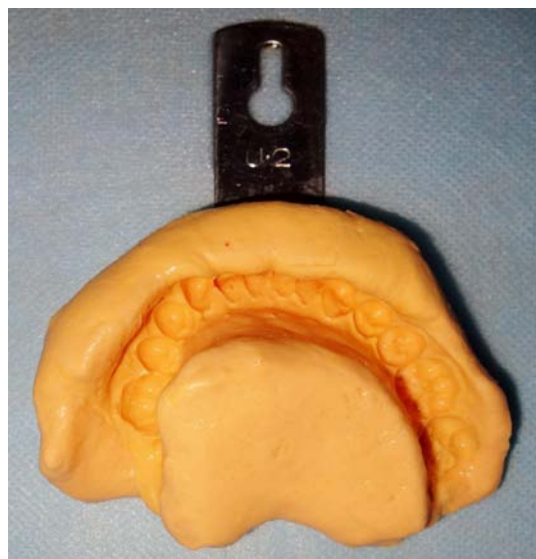


Figure 3: Final mandibular alginate impression taken with upper stainless steel tray.

trays in order to confirm them to the shape of the lower dental arch and prevent impingement of the soft tissues. The increased time and manipulation required in this procedure is obvious and it also leads to patient discomfort, especially in those with limited mouth opening. Moreover, the difficulty in adjustment of plastic trays also limits their use for such impressions.

Technique

Here, an innovative clinical tip is presented which proposes the use of conventional maxillary stainless steel tray (with minimal or negligible adjustment) for taking the impression of lower asymmetric dental arches (Figure 2). While taking the impression, the patient is instructed to partially retract his/her tongue in the floor of the mouth in order to obtain good depth of lingual vestibular sulci on both sides. Once the impression is made, the tongue area is reshaped by carefully manipulating the freshly mixed alginate impression material with fingers and thumb [2]. The final lower impression and the retrieved study model are shown in Figures 3 & 4 respectively. This method is

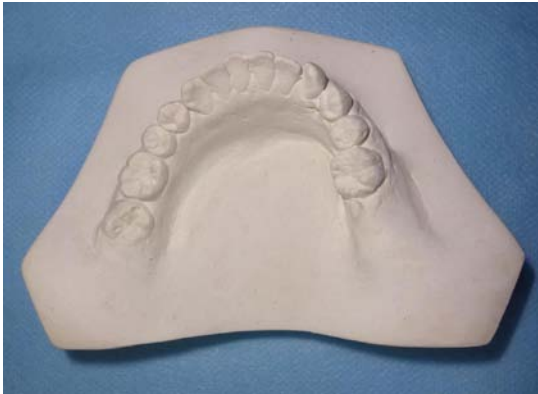

Figure 4: Retrieved study model of a patient with asymmetric mandibular arch form.

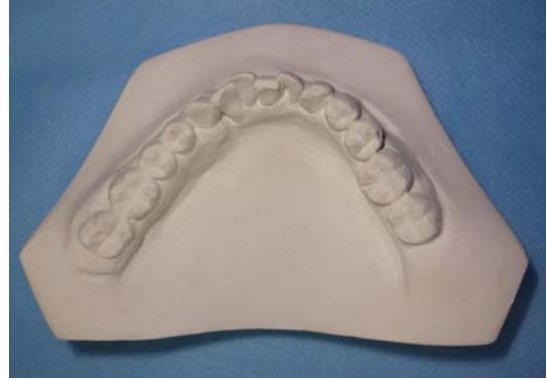

Figure 5: Mandibular study model of a patient with asymmetric and excessive intra-arch width in premolar and molar region.

also beneficial in patients exhibiting asymmetric and excessive intra arch mandibular width in premolar and molar region (Figure 5). Moreover, patients with traumatic injuries of mandible with limited mouth opening can also benefit from such an impression technique.

This novel technique obviates the need for manipulation of the lower impression tray, thus significantly reducing the chair side time and also minimises the discomfort to the patients while taking impressions.

References

1. Legan HL. Orthodontic considerations for orthognathic surgery. Peterson LJ, Editor In: Principles of Oral and Maxillofacial Surgery. 1992; 1237–1278.
2. Kharbanda OP, Darendeliler MA, Kalra S. Alginate base to evade lingual trimming of the mandibular cast. Contemp Clin Dent. 2014; 5: 527.