

Case Report

Covid-19 Combined with Stress Cardiomyopathy: Case Report and Review of the Literature

Ren S¹, Li Y², Hao G¹, Long L¹, Shen L¹ and Zhao H^{1*}

¹Department of Intensive Care Unit, Hebei General Hospital, Hebei, China

²Emergency Department, Cangzhou Central Hospital, Hebei, China

*Corresponding author: Heling Zhao, Department of Intensive Care Unit, Heping West Road, Xinhua Area, Shijiazhuang, Hebei Province, China

Received: September 14, 2021; Accepted: October 08, 2021; Published: October 15, 2021

Abstract

Introduction: Severe COVID-19 can cause multiple organ dysfunction or failure, often associated with cardiac dysfunction, known as stress cardiomyopathy or apical spherical syndrome.

Patient Concerns: Severe COVID-19 patients in Hebei province have 5 cases of stress cardiomyopathy. Two cases in Cangzhou are summarized from Feb 2020 to May 2020.

Diagnosis: Based on the precipitating factor, pathophysiology, Mayo diagnostic criteria and differential diagnosis of stress cardiomyopathy, the patients were diagnosed with stress cardiomyopathy, which is characterized by elevated biomarkers, hemodynamic instability, and cardiomyopathy.

Interventions: Early and dynamic monitoring of ECG, myocardial enzymes, cardiac troponin and echocardiography are needed to predict and assess the risk of stress-induced cardiomyopathy. Noradrenaline and dobutamine were continued to be given, and neokine, levosimendan, Cediland and other drugs were given successively to strengthen the heart.

Outcomes: After several days of supportive care, the patients's cardiac output and the apical movement were gradually improved.

Conclusion: Reversible stress cardiomyopathy may occur in the setting of COVID-19 infection with elevated cardiac biomarkers and an abnormal ECG and echocardiographic. We should pay more attention to the treatment of stress cardiomyopathy.

Keywords: COVID-19; Takotsubo Cardiomyopathy; Cardiomyopathy; Acute Coronary Syndrome; Novel Coronavirus

Abbreviations

COVID-19: Corona Virus Disease 2019; ECG: Electrocardiogram; ICU: Intensive Care Unit; BNP: B type Natriuretic Peptide; ARDS: Acute Respiratory Distress Syndrome; NT-proBNP: N terminal pro B type Natriuretic Peptide; CK-MB: Isoenzyme of Creatine Kinase; EF: Ejection Fraction; PiCCO: Pulse Indicator Continuous Cardiac Output; CO: Cardiac Output; CI: Cardiac Index; Hs-TNT: High Sensitivity Troponin T; ACE2: Angiotensin-Converting Enzyme 2

Introduction

COVID-19 has become a common challenge for all mankind. COVID-19 is classified as light, normal, heavy and severe. According to statistics, COVID-19 incidence accounts for about 20% of the total cases in China, and the mortality rate in Hubei is about 3%. The diagnosis standard of severe COVID-19 is one of the following: 1. Respiratory failure and mechanical ventilation; 2. Shock; 3. ICU monitoring and treatment combination with other organ failure. Severe COVID-19 can cause multiple organ dysfunction or failure, often associated with cardiac dysfunction, known as stress cardiomyopathy or apical spherical syndrome. It is transient left ventricular wall motion abnormalities caused by physical or mental stress factors. Laboratory tests show that myocardial enzymes, muscle calcium protein or BNP increase, and ECG and echocardiographic

abnormalities can also occur, such as arrhythmia, left ventricular dysfunction. The decrease of ventricular function can lead to the decrease of cardiac function. When the primary stress factors are controlled, the cardiac function can return to normal. The cardiac function should be closely monitored, and the cardiogenic shock, left ventricular outflow tract obstruction, left ventricular thrombosis and various malignant arrhythmias should be vigilant, such as ventricular fibrillation, atrioventricular block and cardiac arrest [1,2]. Severe COVID-19 patients in Hebei province have 5 cases of stress cardiomyopathy, 2 cases in Cangzhou, including 1 deaths and unknown sources of stress. Two cases of COVID-19 complicated with stress cardiomyopathy in Cangzhou are summarized as follows:

Case Presentation

Case 1

Male, 61 years old, was hospitalized on January 29, 2020, mainly due to fever for 7 days and chest tightness for 4 days. COVID-19 was diagnosed in January 28th. It has history of type 2 diabetes, chronic obstructive pulmonary disease, bronchiectasis, resection of left lung cancer and hypertension. After admission, the patients were given noninvasive ventilator to assist breathing. The oxygenation was poor and circulation was unstable. Dopamine was used to maintain blood pressure at 5µg/kg. Min. severe COVID-19, ARDS, multiple organ

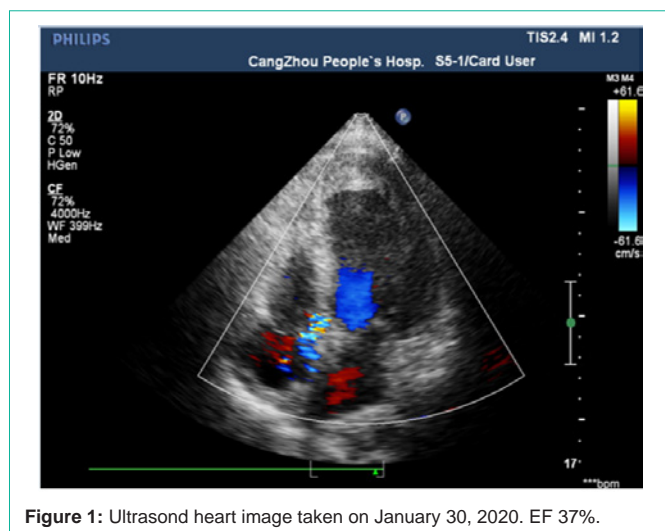


Figure 1: Ultrasound heart image taken on January 30, 2020. EF 37%.

dysfunction syndrome (respiratory failure, shock, heart failure) were diagnosed on January 30, blood pressure and heart rate decreased. NT-ProBNP 210pg/ml, CK-MB 18.1U/L, 2-1 NT-ProBNP 35000pg/ml, CK-MB to 39.5U/L, LDH 775U/L, and myocardial enzymes were all higher than normal range. ECG showed sinus rhythm, low and flat T wave in leads I and AVL, and inverted T wave in leads V2-V6. Echocardiography showed that the left ventricle was enlarged and the range of motion was decreased, especially at the apex of the heart, with EF 37% (Figure 1). In consideration of the existence of stress cardiomyopathy, noradrenaline and dobutamine were continued to be given, and neokine, levosimendan, Cediland and other drugs were given successively to strengthen the heart. The hemodynamic parameters were monitored by PiCCO on February 4, CO 3.27l/min, CI 1.67l/min/m², the cardiac output gradually increased to normal, and the apical movement was improved on February 5. EF was 56% (Figure 2) and apical movement was improved on February 8.

Case 2

Female, 61 years old, was admitted to the hospital at 2-6, 2020, 17:40, mainly due to fever for 12 days and suffocation for 4 days. The novel coronavirus pneumonia (critical weight) was diagnosed 2-5 days later, and the 2-12 day was performed by endotracheal intubation. The circulation was unstable. Norepinephrine was used to maintain blood pressure. The echocardiographic return was observed on the 2-18 day: the left ventricular apical movement was weakened, the spherical heart was manifested clearly, EF33%, the electrocardiogram V2 lead ST elevated 0.1mv, and the V3-4 turned from negative to positive, negative and bidirectional. The evolution of myocardial infarction was considered as stress cardiomyopathy, cardiogenic shock, NT proBNP 2882pg/ml, CK 51U/L, CK-MB 12.3 U/L, hsTNT was 0.179ng/ml, which was treated with dopamine, neokine and levosimendan on February 21, the left ventricular apex wall became thinner, and the range of motion decreased gradually, EF 69%. The patients stopped using vasoactive drugs on March 14, and the echocardiography was obviously improved.

Discussion

All two patients with severe COVID-19 suffered from stress cardiomyopathy during treatment, and their heart function

improved after 1 weeks through active treatment. Definite diagnosis or suspected patients with COVID -19 was related with myocardial injury .There is a myocardial injury marker troponin elevation, and no myocardial ischemia clinical evidence, and can be accompanied by B type Natriuretic Peptide (BNP) or N terminal B type Natriuretic Peptide (NT-ProBNP) level rise. About 1/3 patients with COVID -19 can have transient left ventricular function decline. About 1/3 of the elderly patients show elevated peripheral resistance. Fluid management is very important. Excessive inappropriate fluid replacement can induce acute left heart failure, especially in elderly patients, resulting in sudden death [3]. About 23% of COVID -19 will develop , characterized by temporary wall motion abnormality, usually 1-2 weeks, most of which will return to normal in most cases in January [4]. 5%-10% patients with stress cardiomyopathy may develop into cardiogenic shock.

Precipitating factor

Mental Stress (for example: anxiety) was almost in all patients with COVID -19, especially in severe patients. In the stress state, catecholamine is released in large quantity, and its cardiotoxicity and vasoconstriction may lead to arrhythmia and high blood pressure adverse reactions, but 1/3 of the patients have no clear stressor.

Pathophysiology

Stress syndrome is multifactorial [5-8]. The main mechanism may be myocardial ischemia, left ventricular outflow tract obstruction, myocardial toxicity caused by catecholamine release, signal interruption mediated by adrenaline, and neural regulatory system dysfunction caused by sympathetic nervous system over activation, including local cardiac sympathetic nerve damage and noradrenaline release.

The pathogenesis may be related to the following factors: first, virus infection causes myocardial cell damage. Secondly, ACE2 receptor is widely expressed in cardiovascular system, which can damage myocardium through ACE2 related signal pathway. Thirdly, novel coronavirus pneumonia patients may have imbalance between Th1 and Th2, which can damage the myocardium by triggering cytokine storm.

Mayo diagnostic criteria

1. The abnormal left ventricular wall motion (dyskinesia, hypokinesia and no motion) exceeds the vascular area temporarily;
2. ECG manifestations: new ST segment elevation or T wave inversion, troponin elevation;
3. No plaque or coronary artery occlusion on angiography;
4. Except myocarditis or chromaffin cell tumor.

Laboratory examination: Abnormal ECG: ischemic ST segment elevation, T wave inversion, or simultaneous occurrence, ST segment elevation accounted for 44%, ST segment depression accounted for 8%, T wave inversion accounted for 41%, left ventricular block accounted for 5%. Myocardial necrosis: the elevation of troponin is lower than that of acute coronary syndrome. High troponin indicates poor prognosis.

In the death cases of COVID-19 reported by the National Health Protection Committee, there were no cardiovascular diseases, obvious heart damage during the course of disease progression, and other cases were abnormal myocardial enzymes and ST segment changes

in ECG, and the performance was sudden heart rate decline, heart sounds could not be heard [9]. Patients with COVID-19 were treated in January 1, 2020 to January 22, 2020 showed that the increase of myocardial enzymes, especially the increase of myocardial kinase (CK) and myocardial kinase isozyme (CK-MB), suggested that the disease was serious and tended to deteriorate.

Differential diagnosis

Acute coronary syndrome: Stress cardiomyopathy and acute coronary syndrome show similar characteristics, including symptoms: pain under the sternum, dyspnea, ECG changes (ST segment elevation, T wave inversion and QT interval extension), arrhythmia and positive myocardial markers. Dynamic monitoring ECG, ultrasonic examination for apical spherical change. Compared with acute myocardial infarction, patients with stress cardiomyopathy have higher levels of soluble thrombomodulin, tumor suppressor 2, high-sensitivity C-reactive protein, lower levels of peptide and troponin. Coronary artery occlusion can occur on angiography.

Explosive myocarditis: The cause of the disease is common in virus, poisoning and other factors. Coronary angiography was normal in patients with explosive myocarditis. Endomyocardial biopsy is the gold standard for diagnosis. Explosive myocarditis is characterized by severe systolic dysfunction, increased wall thickness, reactive myocardial edema, and significant improvement in ventricular function at 6 months [10].

Treatment

For the treatment of stress cardiomyopathy, there is lack of specific treatment means, mostly support treatment at present. Principles of myocardial injury treatment: bed rest, support treatment, ensure sufficient heat, maintain water, electrolyte and acid-base balance, timely oxygen therapy and respiratory support, prevent and treat complications. Mild disease can be evaluated, dredged and treated. Stress cardiomyopathy often combines with acute heart failure or shock. It needs close monitoring. Severe patients may have cardiogenic shock, which is life-threatening.

Drug treatment recommendations [11]: Levosimendan: EF < 55%, no left ventricular outflow tract obstruction, arterial pressure >90mmHg, β receptor blocker: QTc <500ms, left ventricular outflow tract obstruction, ACE inhibitor/ang receptor antagonist: reduce recurrence rate, diuretics: reduce edema, nitrates: no left ventricular outflow tract obstruction, avoid the use of catecholamines. β -blockers can be used in patients with stable hemodynamics. Patients with hemodynamic instability may choose milrinone or levosimendan, and if necessary, aortic balloon counterpulsation or extracorporeal membrane oxygenation.

COVID-19 diagnosis and treatment expert consensus proposal: COVID-19 patients with acute myocardial injury, can be given nutritional myocardium drugs, such as coenzyme Q, vitamin C, creatine phosphate, polarized liquid and so on. Be alert to the occurrence of acute fulminant myocarditis. Patients with elevated troponin need to be closely monitored and the level of troponin should be rechecked every day. At the same time, they need to be aware of drug-related heart damage, such as: abidol, azithromycin, quinolones and other drugs may increase the incidence of heart failure.

Conclusion

In conclusion, COVID-19 is highly needed in severe COVID-19 patients through these two case reports and literature review. Early and dynamic monitoring of ECG, myocardial enzymes, cardiac troponin and echocardiography are needed to predict and assess the risk of stress-induced cardiomyopathy. COVID-19 should be monitored early, so as to reverse the course of disease, avoid more serious complications and improve the success rate of treatment for COVID-19.

Declarations

Ethics approval and consent to participate: The study was established, according to the ethical guidelines of the Helsinki Declaration and was approved by the Human Ethics Committee of Hebei General Hospital. Written informed consent was obtained from individual or guardian participants.

Consent for publication: Written informed consent for publication was obtained from all participants.

Availability of data and materials: The datasets generated and analysed during the current study are not publicly available. Please contact the corresponding author for data requests.

References

1. National health and Health Committee, The novel coronavirus pneumonia diagnosis and treatment plan (Trial Seventh Edition), Journal of cardiopulmonary vascular disease, 2020; 2: 103-107.
2. Zhang M, Li C. Novel coronavirus pneumonia and cardiovascular diseases, Medical Journal of the Chinese People's Armed Police Forces, 2020; 2: 93-96.
3. Meng QY. Analysis of 13 kinds of sudden deaths in the treatment of coronavirus diseases in 2019, Chinese Journal of Critical Care Medicine 2020; 2: 25.
4. Yang X, Yu Y, Xu J, et al. Clinical course and outcomes of critically ill patients of 2019 novel coronavirus pneumonia: a single-centered retrospective observational study from Wuhan, China [J]. Lancet Respir Med. 2020; 24.
5. Hu SS, Gao RL, Liu LS, Zhu ML, Wang YJ, Wu ZS, et al. Summary of China cardiovascular disease report 2018. China Journal of circulation. 2019; 34: 209-220.
6. Zhao Y, Zhao ZX, Wang YJ, Zhou Yu, Zuo Wu. Single-cell RNA expression profiling of ACE2, the putative receptor of Wuhan 2019-nCoV. Bio Rxiv. 2020.
7. Guo D, Guo WG, Liu PY, et al. Cardiac manifestations of novel coronavirus infection. Cardiac Journal. 2020; 32: 1-3.
8. Huang C, Wang Y, Li X, Ren Li, Zhao Ji, Hu Yi. Clinical features of patients infected with 2019 novel coronavirus in Wuhan, China. Lancet, 2020; 395: 497-506.
9. Højagergaard MA, Hassager C, Christensen TE, Bang Li, Gotze JP, Ostroet al. Biomarkers in patients with Takotsubo cardiomyopathy compared to patients with acute anterior ST-elevation myocardial infarction. Biomarkers. 2020; 25: 137-143.
10. Zhu ZX, Wang M, Zhu HY. Progress in diagnosis and treatment of explosive myocarditis. Journal of clinical emergency. 2019; 9: 687-691.
11. Chinese Research Hospital Association of Critical Care Medicine, Youth Committee of Chinese Research Hospital Association of Critical Care Medicine. Chinese experts consensus on diagnosis and treatment of severe and critical new coronavirus pneumonia, Chin Crit Care Med. 2020; 32: 129-134.