

Case Report

Metachronic Small Bowel Metastasis of a Squamous Cell Carcinoma of the Cervix

Meriam S^{1*}, Dorra T², Nawel B², Asma O², Fatma K¹, Norsaf B², Hela E² and Dalila G²

¹Department of Pathology. Habib Thameur Hospital, Tunisia

²Department of Gastroenterology. Habib Thameur Hospital, Tunisia

*Corresponding author: Sabbah Meriam, Department of Pathology. Habib Thameur Hospital, Tunisia

Received: January 02, 2020; Accepted: January 23, 2020; Published: January 30, 2020

Case Report

We report a case of a woman 33 years old with past medical fact of hypertension, in whom squamous cell carcinoma of the cervix was diagnosed within post coital bleeding. The tumor was classified stage Ib according to FIGO classification and were treated with brachytherapy followed by hysterectomy with oophorectomy and external iliac lymphadenectomy. The evolution was favorable and she remained asymptomatic for 3 years. She was than hospitalized for obstructive syndrom. Abdominal X ray showed hydro-aeric levels and abdominal computed tomography showed grelic tumor with distension of the small bowel (Figure 1). Laparotomy exploration objectified a distended small bowel among a stenosis at 50 cm from the ileocecal valve and resection of 20 cm of small bowel was performed. Histological examination and immunochemistry of the surgical specimen confirmed the small bowel localization of a squamous cell carcinoma of the cervix (Figure 2). After surgery, she underwent adjuvant radiotherapy. She died after 5 months.

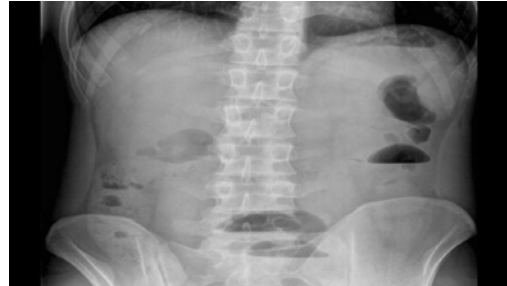


Figure 1: Abdominal X Ray showing grelic hydro-aerial levels.

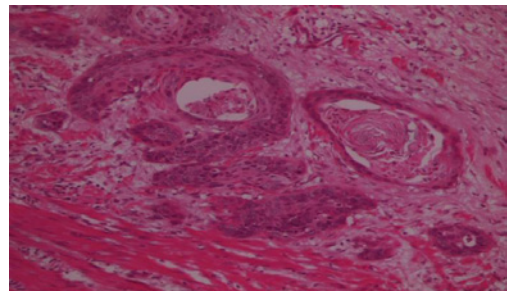


Figure 2: Histopathological Examination of the grelic resection (HE): infiltration of small bowel by uterine squamous cell carcinoma.