

## Case Report

# Ocular Coherence Tomography Findings in an Unusual Case of Isolated Dermatomyositis Associated Retinopathy: A Case Report

**Osman N\*, Mathew C and Arora R**

Department of Ophthalmology, Salisbury District Hospital, Odstock Road, Salisbury, SP2 8BJ, UK

**\*Corresponding author:** Mohamed Osman, Department of Ophthalmology, Salisbury District Hospital, Odstock Road, Salisbury, SP2 8BJ, UK**Received:** December 20, 2021; **Accepted:** January 20, 2022; **Published:** January 27, 2022

## Introduction

Dermatomyositis (DM) is a chronic inflammatory disorder of the skin and muscles producing muscle inflammation, skin rashes and swelling. Ocular manifestations have commonly been reported among the spectrum of clinical features of dermatomyositis [1]. Heliotrope eyelid eruptions are considered the hallmark of the disease affecting the eye [2]. Other common ocular manifestations are periorbital redness and oedema producing ptosis, chemosis and exophthalmos [3]. Additional features include conjunctivitis, iritis, episcleritis and uveitis with glaucoma [3,4]. Involvement of the extraocular muscles is extremely rare and can cause pain and ophthalmoplegia. (3,4) First described by Bruce in 1983, retinopathy is thought to be rarely associated with dermatomyositis and has only been sporadically reported in literature [5]. But, some reports indicate that the incidence of DM associated retinopathy is significantly underestimated as patients often are asymptomatic and do not routinely receive a formal ophthalmic assessment prior to commencing therapy [1,6]. We are presenting a rare case of isolated retinopathy with dermatomyositis which not only highlights the need for early fundoscopy as part of the routine examination for cases of dermatomyositis but also the potential for optical coherence tomography (OCT) in diagnosing retinal changes when fundus fluorescein angiography (FFA) may be clinically unsuitable or contraindicated.

## Case Presentation

We present the case of a 48-year-old male who was referred by the medics as an inpatient to the emergency eye clinic with 5 days history of headaches and a decline in vision. He was previously reviewed in the eye clinic around 6 months back for mild dry eyes with 6/6 BCVA both eyes. He was admitted under the medics as he was systemically unwell with fatigue, vomiting, arthralgia, headache, and reduced vision. On presentation BCVA had declined to 6/12 in the right eye and 6/18 in the left eye. He was already under the medical team for management of dermatomyositis and was on 80mg prednisolone and methotrexate. General investigations including chest X-ray, ECG, abdominal X-Ray, and CT brain were normal. On general physical examination, his vitals were within normal limits.

On eye examination, anterior segment examination was

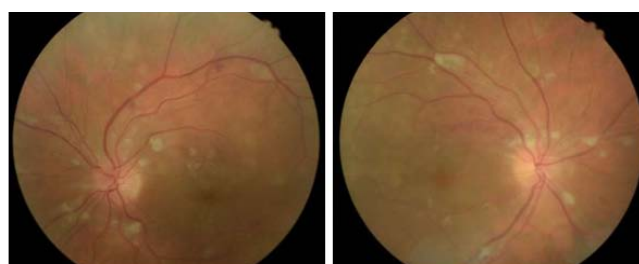
unremarkable with no evidence of common ocular manifestations of dermatomyositis such as periorbital heliotrope eyelid eruptions, periorbital erythema, oedema, ptosis, chemosis, or exophthalmos and no signs of anterior segment or vitreous inflammation. Dilated fundus examination showed symmetrical bilateral macular swelling extending to the discs, multiple cotton wool spots around optic discs and minimal haemorrhages. Peripheral retina was flat with no obvious tears or detachments. OCT showed extensive loss of segmentation of the retinal layers in the inner retina with scattered hyper-reflective dots. There was neurosensory retinal detachment with some macular oedema. The ganglion cell layer was hyper-reflective and thickened in few parts. In the areas of cotton wool spots, inner nuclear and outer plexiform layer was typically wavy.

He was investigated for other causes of retinopathy including syphilis, HCV, CMV and TB but his tests were negative. Despite oral steroids there was worsening of retinopathy with extensive ischaemic changes in the inner retina. Due to deteriorating ocular and systemic function, he needed urgent transfer to a tertiary centre for consideration of renal biopsy and management of deteriorating renal function within a week of presentation. Moreover, his systemic condition precluded the possibility of additional ocular imaging including FFA (Figure 1-3).

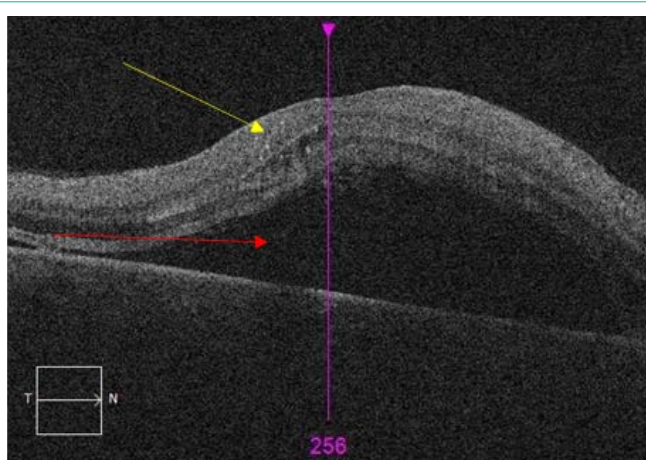
## Discussion

DM is a systemic inflammatory vasculopathy predominantly affecting the skin and muscles [1]. Ocular involvement has been reported as part of the clinical manifestations of the disease in both adults and children [1]. The most common ocular manifestation is heliotrope eyelid eruptions, which are postulated to be due to active underlying inflammatory vasculopathy [1]. Indeed, according to a study at Sick Children's Hospital, heliotrope eyelid lesions were noted in 83% of JDM cases at diagnosis [7].

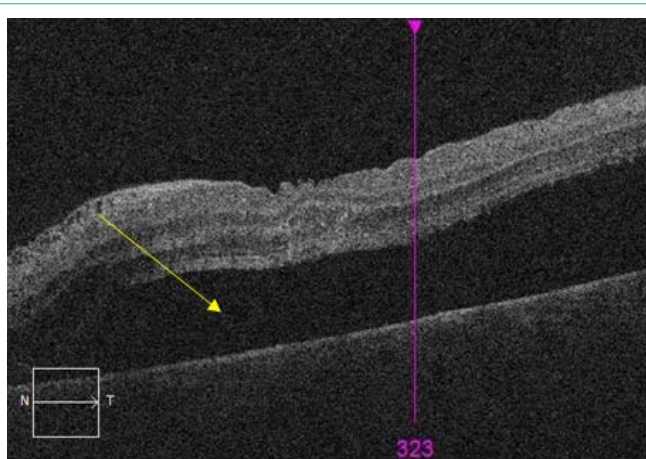
Aside from the classic heliotrope eyelid lesions, retinopathy is thought to be the second most common ocular finding [6]. Indeed, while retinopathy is considered a rare condition, experts believe



**Figure 1:** Figure indicating macular exudates, cotton wool spots and haemorrhages bilaterally on presentation.



**Figure 2:** Figure indicating intraretinal fluid and scattered hyper-reflective spots (yellow arrow) and neurosensory detachment with macular oedema (red arrow).



**Figure 3:** Figure indicating neurosensory detachment with macular oedema.

the incidence of retinopathy associated with dermatomyositis may be significantly underestimated possibly because patients with retinopathy may be entirely asymptomatic and therefore, do not receive a formal ophthalmic assessment early in their disease course prior to starting therapy [6].

Children are thought to be at higher risk of developing retinopathy due to the increased systemic vasculitis commonly noted in juvenile DM [2]. The characteristic retinal lesions are cotton wool spots thought to be induced by arteriolar obstruction and capillary damage resulting in axonal swelling, rupture and ultimately, nerve fibre layer infarction [3,4]. Visual loss may occur due to macular haemorrhages and macular oedema resulting in central scotomas [3,4]. Reassuringly, retinal haemorrhages and cotton wool spots often resolve entirely over few months and visual recovery is often complete [3,4]. Unusually, there may be choriocapillary infarction indicated clinically by areas of pigment clumping surrounded by a lighter halo (Elsching's spots) [3,4]. Rarely, there may be optic neuropathy as a result of retinal neuronal atrophy producing permanent visual loss [3,4]. Therefore, while the precise incidence of visual impairment remains unknown, and although visual loss is reversible in a large

majority of cases, there have been reports of persistent visual loss in spite of treatment with steroids and immunosuppressive agents [8].

There are various reasons that have been postulated for retinal vasculitis such as systemic and ocular inflammatory disease, infection, and malignancy [4]. The diagnosis is often made following history taking and systemic review [4]. Ocular examination will assist the clinician in further identifying the underlying clinical aetiology depending on the retinal vessels involved, the distribution and degree of ocular inflammation or retinal infiltrate [4]. Pathologically, DM is characterized by perivascular inflammation, vasculopathy and peri-fascicular atrophy [9]. Leukocytes play an important role in DM pathogenesis as their aggregates, which are induced by complement activation, are usually bigger than the diameter of the precapillary arterioles in the human retina [10]. Indeed, the retinal infarctive events bear remarkable similarity to the arteriolar endothelial damage and platelet thrombi commonly noted in muscle biopsy [4,11].

Interestingly, the case described in this report was visually symptomatic prompting an ophthalmic review. While he had none of the common ocular manifestations of DM such as heliotrope eyelid eruptions, he had many of the classic features of DM associated retinopathy. However, it is unclear whether the retinal manifestations in DM seen in this patient was related to his systemic flare up of symptoms as it has not been previously reported in literature. Prior reports suggests that while retinopathy has typically been clinically obvious, one report suggests that intravenous fluorescein angiography may allow for identification of more vascular involvement that what is clinically observed [4]. However, at the time of diagnosis in our patient, he was systemically unwell and unsuitable for FFA. Hence, we found that OCT was a very effective and safe method of diagnosing and monitoring retinal involvement in a systemically unwell patient rather than the relatively more invasive FFA test.

DM requires treatment with immunosuppression regardless of their ocular or retinal findings. Indeed, ocular complications occur due to poor systemic control of the underlying disease and since ocular complications leading to visual impairment is a possibility, a multidisciplinary approach is crucial for prompt diagnosis and early management to ensure optimal visual outcomes [12]. Visual prognosis depends on several factors such as disease control with immunosuppressants and biologics, the use of steroid sparing drugs to prevent complications such as glaucoma and cataracts and prompt referral to ophthalmologists for management of ocular complications [12]. Therefore, rheumatologists must be cognizant of symptomatic ocular disease but since ocular and especially retinal disease may be asymptomatic, clinicians must consider referral to ophthalmic specialists particularly among symptomatic or asymptomatic patients with high risk factors such as those patients on high dose of steroids for prolonged periods of time [12].

## Conclusion

Retinopathy in dermatomyositis is a rare entity and only few case reports are available in literature. Prompt diagnosis and management with a multidisciplinary approach results in full recovery. Some patients may however show progressive deterioration despite immunosuppression and there is the need for early recognition and prompt comprehensive ophthalmological examination for early

detection of ischaemic retinal changes that will require urgent change of management hence lowering the risk of losing sight [6]. While FFA may be able to detect vascular changes that are not otherwise clinically obvious, OCT is a very useful non-invasive tool in prompt diagnosis and detection of ischaemic changes resulting from vasculitis particularly among clinically unwell patients in whom FFA may be challenging or contraindicated.

## Informed Consent

Informed written consent for publication had been obtained from the patient.

## References

1. Akikusa JD, Tennankore DK, Levin AV, Feldman BM. Eye Findings in Patients with Juvenile Dermatomyositis. *The Journal of Rheumatology*. 2005; 32.
2. Foroozan R. Visual loss from optic neuropathy in dermatomyositis. *Rheumatology*. 2004; 43: 391-393.
3. Ophthalmic Complications of Dermatomyositis. In: *Dermatomyositis*. Berlin, Heidelberg: Springer Berlin Heidelberg. 2009: 93-95.
4. Backhouse O, Griffiths B, Henderson T, Emery P. Ophthalmic manifestations of dermatomyositis. *Annals of the Rheumatic Diseases*. 1998; 57: 447-449.
5. Bruce GM, York N. BRUCE: Retinitis in Dermatomyositis Retinitis In Dermatomyositis. *Berens: Tr. Am. Acad. Ophth. & Oto-Laryng*. 1926; 2.
6. Migliaresi S, ALTG. Eye involvement in dermatomyositis/polymyositis. *J Rheumatol*. 1996; 23: 2006-2007.
7. Ramanam AV, FB. Clinical features and outcomes of juvenile dermatomyositis and other childhood onset myositis syndromes. *Rheum Dis Clin North Am*. 2002; 28: 833-857.
8. Yeo LM, SDSR et al. Irreversible visual loss in dermatomyositis. *Br J Rheumatology*. 1995; 34: 1179-1181.
9. Robinson AB, Reed AM. Clinical features, pathogenesis and treatment of juvenile and adult dermatomyositis. *Nature Reviews Rheumatology*. 2011; 7: 664-675.
10. Agrawal A, McKibbin MA. Purtscher's and Purtscher-like Retinopathies: A Review. *Survey of Ophthalmology*. 2006; 51: 129-136.
11. Crowe W, BKL, JHP. Clinical and pathological implications of histopathology in childhood poly- dermatomyositis. *Arthritis Rheum*. 1982; 25: 126-139.
12. Ruiz-Lozano RE, Fabiola Velazquez-Valenzuela, Roman-Zamudio M, Andrade-Leal K, Rodriguez-Garcia A. Polymyositis and dermatomyositis: ocular manifestations and potential sight-threatening complications. *Rheumatology International*. 2021; 1: 3.