

Clinical Image

Idiopathic Macula Pucker in Young Patient

Karmoun S*, Abdellah E, Aboulanouar A and Berraho A

Service d'ophtalmologie B, Hôpital des spécialités de Rabat, Morocco

***Corresponding author:** Karmoun Souhaila, Service d'ophtalmologie B, Hôpital des spécialités de Rabat, Morocco

Received: June 28, 2020; **Accepted:** October 09, 2020; **Published:** October 16, 2020

Clinical Image

We report the case of twenty-seven-year old healthy man presented with blurring of vision associated with metamorphopsia of six month duration in the left eye. He had no ocular complains in his right eye, and also no significant systemic problems. The best visual acuity was 10/10 in the right eye and 5/10 in the left one. The examination of anterior segment was normal in both of eyes. Dilated fundus examination of the left eye showed a gray-flat fibrous lesion at the macula obscuring the fovea and the perifoveal region suggestive of a dense macular Epiretinal Membrane (ERM) (Figure 1). The examination of right eye was normal. The Optical Coherence Tomography (OCT) of left eye showed an ERM stretching across the surface of the macula with curled edges stretching into the vitreoretinal interface with marked retinal thickening (Figure 2).

Epiretinal membrane is avascular fibrous tissue, which is adhered to the internal layers of retina in the macular area. Patient may be asymptomatic or present with blurring of vision and metamorphopsia.

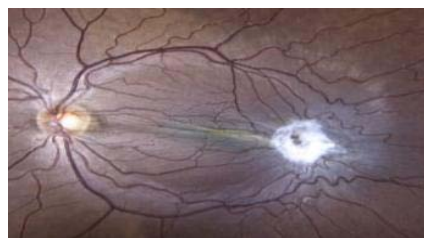

Figure 1: Fundus examination of the left eye showed a gray-flat fibrous lesion at the macula obscuring the fovea and the perifoveal region.

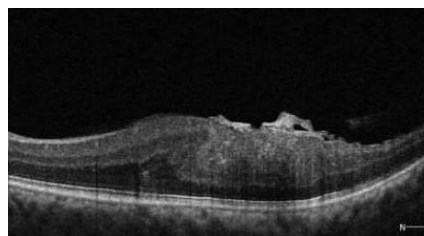


Figure 2: OCT of left eye showed an ERM stretching across the surface of the macula with curled edges stretching into the vitreoretinal interface with marked retinal thickening.

The idiopathic Epiretinal Membrane is more often seen in elderly but it could be present in young patients in association with other vitreoretinal diseases and following intraocular surgery. The idiopathic Epiretinal Membrane in young patients is rare.