

Research Article

Clinical Risk Estimation of Advanced Age-Related Macular Degeneration in Women with Breast Arterial Calcifications

Saa J^{1,2*}, Fernández-Guinea O^{2,3}, García-Pravia P³, Eiró N², Del Casar JM^{2,4}, Galindo J¹, Baamonde B⁵ and Vizoso FJ^{2,4}

¹Department of Ophthalmology, Fundación Hospital de Jove, Spain

²Research Unit, Fundación Hospital de Jove, Spain

³Department of Radiodiagnosis, Fundación Hospital de Jove, Spain

⁴Department of Surgery, Fundación Hospital de Jove, Spain

⁵Department of Ophthalmology, University of Oviedo, Spain

*Corresponding author: Saa J, Department of Ophthalmology, Jove Hospital Foundation, Eduardo Castro s/n, 33290 Gijón, Spain

Received: August 24, 2016; Accepted: November 23, 2016; Published: November 28, 2016

Abbreviations

AMD: Age-related Macular Degeneration; BAC: Breast Arterial Calcifications

Introduction

Age-related Macular Degeneration (AMD) is a common cause of vision loss in people over 65 years with a complex pathophysiology that includes risk factors such as age, genetic and cardiovascular factors [1]. On the other hand, in our midst a population screening in women aged 50 to 70 years for the detection of breast cancer including mammography is performed biennially [2]. The appearance of Breast Arterial Calcifications (BAC) on mammograms occurs in 8% of cases and have been associated with cardiovascular morbidity and mortality [3,4].

In a study conducted by our group on a hospital population has been associated, after multivariate analysis independently the presence of suggestive eye fund us changes of AMD with the presence of BAC, hypertension and overweight women between 50 and 70 years [5]. In the present study the data obtained in previous work assessing the likelihood of developing advanced AMD in women with BAC using a validated clinical risk calculator.

Subjects and Methods

They have been included in this study woman between 50 and 70 years of a population screening program for breast cancer at the Hospital Foundation Jove Gijon (Spain). 71 women with BAC and 50 women without BAC were included in the study. BAC mammographic diagnosis was made according to the recommendations of the American College of Radiology (Figure 1). The study was followed according to the Declaration of Helsinki.

Abstract

Objective/Method: The purpose of the study is to calculate the probability of risk of advanced Age-Related Macular Degeneration (AMD) using a validated risk calculator in women with breast arterial calcifications (BAC) from a screening breast cancer program.

Results/Conclusion: Average probability of advanced AMD in women with BAC were higher than controls. Thus, this could be a preliminary follow-up study to raise the detection of a possible risk group of AMD from a screening is performed and systematic in the normal practice.

Keywords: Age-related macular degeneration; Breast arterial calcifications; Mammograms; Risk calculator

A digital retinography was obtained in 45° color under bilateral pharmacological mydriasis and signs of AMD were assessed as has been previously published. Furthermore, the presence of two events considered: pigmentary changes and large drusen (≥ 125 micrometers) and a point is assigned for each event observed in each eye in each patient getting scores between 0 and 4 points [6].

With this score and other data required probability of risk for advanced AMD (geographic atrophy and neovascular) 3, 5 and 10 years for each patient was calculated, using a validated risk calculator free available online (<http://www.ohscasey.com/amdcator>) [7]. Ophthalmologic evaluation was performed without knowing the results of mammograms.

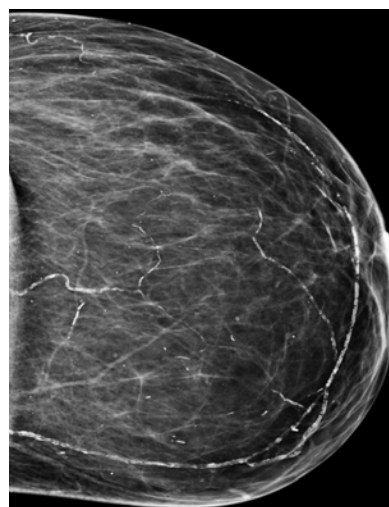
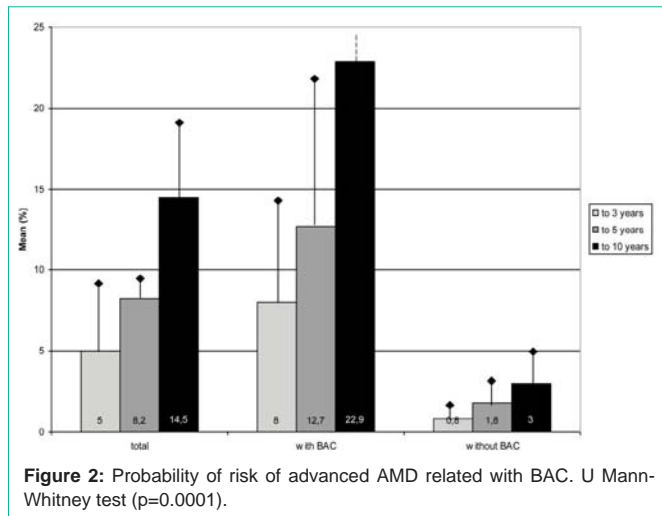


Figure 1: Mammogram picture showing Breast Arterial Calcifications (BAC).



Results

Of the 121 women included in this study, 71 (58.7%) presented BAC. the average percentages of probability of risk for advanced AMD (average between geographic atrophy and neovascular) in each patient by the risk calculator were obtained. The average in the group of patients with BAC was higher than average in the total sample, which in turn is also higher than average group of women without BAC, in calculating risk to 3, 5 and 10 years (Figure 2).

Figure 3 stockings probability of risk of advanced AMD in the combination group with AMD and BAC.

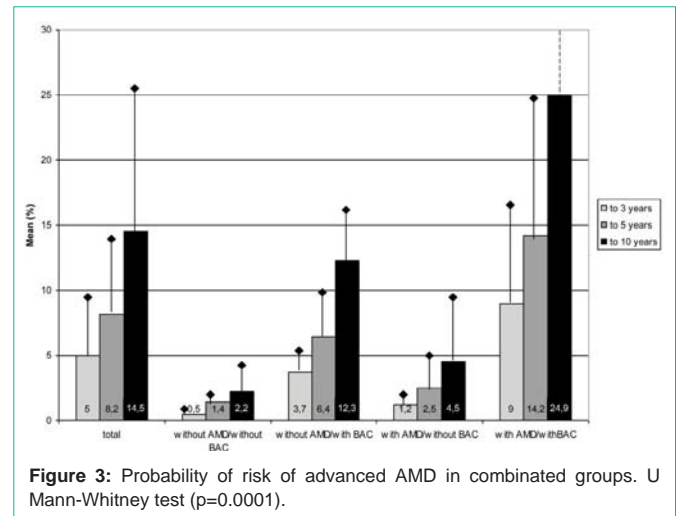
Discussion

In the present study it is part of a population screening mammography in women where sometimes local vascular pathologies that can translate the existence of systemic cardiovascular disease are detected as already previously published [3,4]. Data published by our group previously linking the highest proportion of lesions of AMD in women with BAC, hypertension and overweight [5], support the hypothesis that vascular pathologic changes systemic may accompany changes in the choroid-retinal vascularization in a context of increased cardiovascular risk factors.

In the algorithm used to calculate the risk for advanced AMD they have not been included CFH rs1061170-ARMS2 rs10490924 gene polymorphisms because the authors comment that the difference in the result without this variable is 0-6%, remaining statistical significance [7].

In all subgroups of women with stockings BAC risk probability advanced AMD obtained significantly higher in subgroups without BAC, both in the whole sample and stratification by age groups.

These results support the previous study that relates independently presence of BAC with AMD.



In short, the program of population screening for breast cancer is widespread in our environment and the presence of BAC on mammograms could alert us to the possible existence of macular degenerative disease, in addition to systemic cardiovascular disease.

One limitation of this study is the small sample so that future studies will be needed with larger numbers of patients to confirm these results and to establish a recommendation of ophthalmologic evaluation after the discovery of BAC on mammograms.

References

1. Van Leeuwen R, Ikram MK, Vingerling JR, Witternan JC, Hofman A, de Jong PT. Blood pressure, atherosclerosis, and the incidence of age-related maculopathy: the Rotterdam Study. *Invest Ophthalmol Vis Sci.* 2003; 44: 3771-3777.
2. Asuncion N, Salas D, Zubizarreta R, Almazán R, Ibañez J. Ederra; Network of Spanish Cancer Screening Programmes (Red de Programas Españoles de Cribado de Cáncer). Cancer screening in Spain. *Ann Oncol.* 2010; 21: 43-51.
3. Pidal D, Sánchez-Vidal MT, Rodríguez JC, Corte MD, Pravia P, Guinea O, et al. Relationship between arterial vascular calcifications seen on screening mammograms and biochemical markers of endothelial injury. *Eur J Radiol.* 2009; 69: 87-92.
4. Iribarren C, Go AS, Tolstykh I, Sidney S, Johnston SC, David B. Breast vascular calcification and risk of coronary heart disease, stroke, and heart failure. *J Womens Health (Larchmt).* 2004; 13: 381-389.
5. Saá J, Fernández-Guinea O, García-Pravia P, Fernández-García B, Eiró N, del Casar JM, et al. Relationship between breast arterial calcifications seen on screening mammograms and age-related macular degeneration. *Acta Ophthalmol.* 2014. 92: e582-e584.
6. Ferris FL, Davis MD, Clemons TE, Lee LY, Chew EY, Lindblad A, et al. Age-Related Eye Disease Study (AREDS) Research Group. A simplified severity scale for age-related macular degeneration: AREDS Report No. 18. *Arch Ophthalmol.* 2005; 123: 1570-1574.
7. Klein ML, Francis PJ, Ferris FL, Hamon SC, Clemons TE. Risk assessment model for development of advanced age-related macular degeneration. *Arch Ophthalmol.* 2011; 129: 1543-1550.