

Special Article - Clinical Cases and Images

Bilateral Cytomegalovirus Retinitis in the Absence of Viremia

Christopher T. Shah¹ and Ashvini K. Reddy^{1*}

¹Department of Ophthalmology, University of Virginia, USA

*Corresponding author: Ashvini K. Reddy, Department of Ophthalmology, University of Virginia, 1300 Jefferson Park Avenue, OMS 2860B, Charlottesville, VA 22908, USA

Received: March 17, 2015; Accepted: April 27, 2015;

Published: April 28, 2015

Abstract

Purpose: To report a case of Polymerase Chain Reaction (PCR) Confirmed Bilateral Cytomegalovirus (CMV) retinitis in a patient with mantle cell lymphoma with no detectable CMV viremia.

Methods: Case report.

Patients/Results: A 67 year-old female with mantle cell lymphoma requiring multiple chemotherapeutic regimens and history of previously treated ganciclovir-resistant CMV colitis and viremia presented with bilateral necrotizing retinitis and panuveitis 3 months after her foscarnet was discontinued for undetectable viral loads. Her aqueous was positive for CMV by PCR; however, blood samples for CMV viral loads were negative on presentation as well as 3 months prior by serum PCR. She was treated with intravitreal and intravenous foscarnet and topical steroids with improvement initially, but ultimately developed a retinal detachment OD and severe macular edema with nonperfusion OS as well as bilateral uveitic glaucoma.

Conclusion: CMV retinitis can occur in the absence of contemporaneous CMV viremia. This report demonstrates the utility of intraocular sampling for PCR in such cases and suggests that, especially in the chronically ill, physicians should maintain a high index of suspicion given the necessity for urgent intervention.

Keywords: Cytomegalovirus; Retinitis

Introduction

Cytomegalovirus (CMV) retinitis is typically only described in chronically ill, immunocompromised patients in association with systemic viremia or other organ involvement [1,2]. We report a rare case of bilateral CMV retinitis in the absence of contemporaneous CMV viremia or other active manifestations of CMV.

Case Presentation

An HIV-negative, 67 year-old female with Mantle Cell Lymphoma (MCL) developed treatment-related immunosuppression following a course of Bendamustine and Rituximab. She subsequently developed CMV viremia and colitis; however, dilated fundus exam at that time by our service was negative for CMV retinitis and uveitis. Past ocular history was unremarkable without history of periocular or intravitreal steroid injections and was only notable for a remote history of a horseshoe tear OS treated with cryotherapy 20 years prior.

Her course was marked by persistent CMV viremia despite adequate valganciclovir therapy and she was ultimately found to have a UL97 mutation conferring resistance to ganciclovir but susceptibility to foscarnet. She was treated with a three month course of foscarnet, with which her viremia and colitis resolved. CMV viral loads by serum PCR were undetectable during her 3 month treatment course.

One month after starting the foscarnet, she experienced an episode of metamorphopsia which prompted presentation to her primary ophthalmologist, who saw no retinal changes at that time.

One week following completion of Foscarnet therapy, she developed flashes and floaters OU with decreased vision OD and preserved vision OS. Viral loads around this time were undetectable. Her vision continued to decline, and she again sought the care of her primary ophthalmologist. Intraocular Pressures (IOP) were elevated

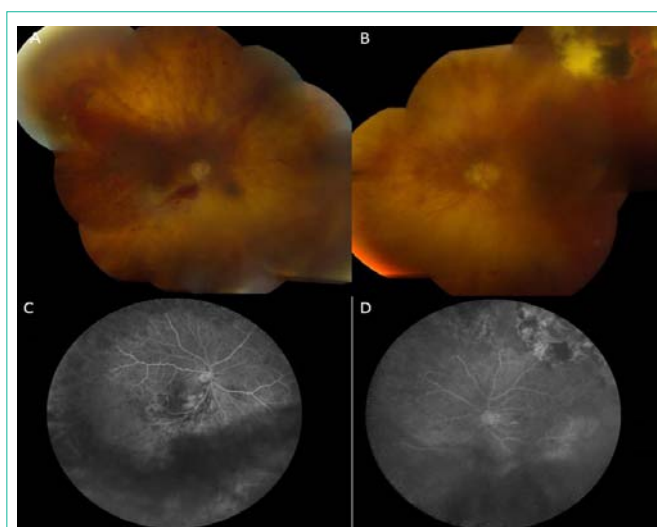


Figure 1: Infectious retinitis of the right and left eyes (A and B) with peripheral vascular occlusion on fluorescein angiography (C and D). Note cryotherapy scar superotemporally in the left eye from previously treated horse shoe tear (B).

bilaterally and she had suspicious retinal lesions precipitating referral to a retina specialist, who referred the patient to our center.

At this time, she had no oral lesions or symptoms of CMV colitis; however, there was severe retinitis. The patient was admitted and started on empiric treatment with intravenous foscarnet. Admission labs were notable for white blood cell count of 3.8 k/microL, an undetectable CMV viral load in the blood, and a CD4 count of 171 per microL. Examination was remarkable for BCVA of 20/60 OU, IOP of 31 OD and 28 OS, and an afferent pupillary defect OD. Slit lamp examination revealed moderate fine keratic precipitates, 2+ cell, 1+ flare, with iris rubeosis and iris hemorrhages OU. Fundus examination was remarkable for severe peripheral retinal vasculitis and circumferential retinal atrophy (Figure 1) consistent with CMV chronic retinal necrosis [2]. Fluorescein angiography confirmed 360-degree retinal vascular occlusion in both eyes (Figure 1). She underwent anterior chamber paracentesis for viral PCR and intravitreal injection of foscarnet OD and remained admitted for continued intravenous foscarnet and serial dilated exams. Anterior chamber PCR was positive for CMV and negative for herpes simplex virus, varicella zoster virus, and toxoplasmosis. She was eventually discharged with a prolonged course of intravenous foscarnet and monitored with monthly CMV viral loads. All viral loads have been undetectable as of 5 months follow-up.

With intravenous foscarnet, there was gradual arrest of the retinitis with increasing granularity of the affected retina. Serial Optical Coherence Tomography (OCT) and Fluorescein Angiography (FA) demonstrated extreme thinning of the peripheral retina OU and retinal vascular non-perfusion. Given her history of lymphoma and state of health, her medical physicians advised against any systemic steroids, so she was treated with topical prednisolone and difluprednate in eyes as well as topical brimonidine, dorzolamide, and timolol. A multidisciplinary team assessed the patient for intraocular lymphoma, which was ruled out given her clinical picture, CMV-positive PCR, and a good response to treatment with antivirals. Had the aqueous PCR been negative or the patient not responded to antivirals, additional testing would have been pursued. At five months of follow-up, the patient developed a macula-involving retinal detachment of the right eye (Figure 2), which was repaired with silicone oil. Her post-operative Snellen acuity was 20/200. She also required a glaucoma tube OD for elevated eye pressure. Her fellow eye has 20/400 vision with increased central macular thickness (Figure 2) and poor retinal perfusion on angiography. She continues to be followed with a guarded prognosis.

Discussion

CMV has a high seroprevalence in the United States and is latent in many healthy individuals. It can be reactivated when T-cell immunity is reduced in cases of chronic illness or Acquired Immunodeficiency Syndrome (AIDS) with CD4 counts below 50 per microL. With the advent of Highly Active Antiretroviral Therapy (HAART) therapy in the management of patients with AIDS and resulting decreased incidence of AIDS related CMV retinitis, CMV

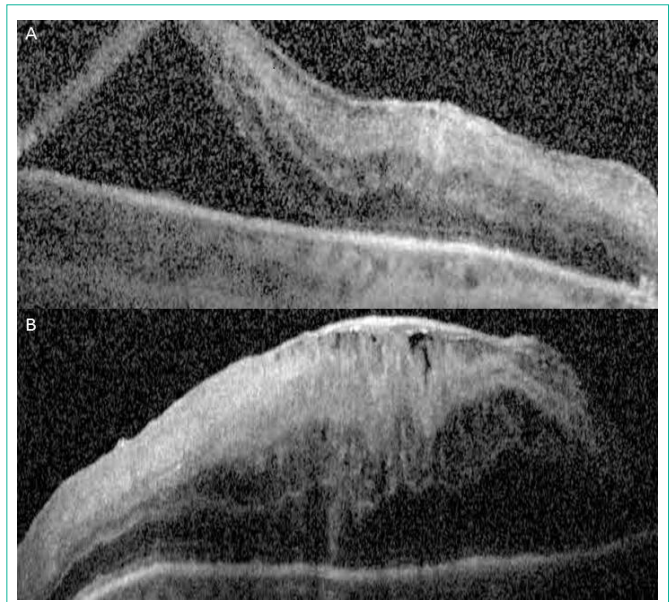


Figure 2: Optical coherence tomography demonstrating (A) macula-involving retinal detachment OD and (B) macular edema OS.

retinitis is now becoming increasingly recognized in non-HIV patients with limited immune dysfunction such as from age, diabetes, or systemic immunosuppressive therapy [3].

Patients with CMV retinitis are at increased risk of delay to diagnosis and appropriate therapy as many cases are initially presumed to be secondary to HSV or VZV in the absence of any history of HIV infection, severe leukopenia, or CMV viremia. CMV retinitis in the absence of viremia is rare [2,4], but has been associated with oral CMV lesions. Without prompt therapy with an effective anti-viral, irreversible blindness can ensue.

The case of this patient suggests that CMV may be sequestered in the eye causing severe retinitis without clinically affecting other organs or causing detectable viremia. For this reason, practitioners should maintain a high index of suspicion and consider confirmation of viral etiology by PCR of intraocular fluid samples, even when CMV viremia is absent, CD4 counts are above 50 per microliter, and no other systemic manifestations are present.

References

1. Joeon S, Lee WK, Lee Y, Lee DG, Lee JW. Risk Factors for Cytomegalovirus Retinitis in Patients with Cytomegalovirus Viremia after Hematopoietic Stem Cell Transplantation. *Ophthalmology*. 2012; 119: 1892-1898.
2. Cheung CYM, Wong IY, Yan K, Kwong YL. Cytomegalovirus oral lesions: harbinger of retinitis in the absence of viraemia. *Ann Hematol*. 2014; 93: 1613-1615.
3. Schnider EW, Elnor SG, Van Kuijk FJ, Goldberg N, Lieberman RM, Elliott D, et al. Chronic retinal necrosis: Cytomegalovirus Necrotizing Retinitis. *Retina*. 2013; 33: 1791-1799.
4. Gupta S, Vemulakonda GA, Suhler EB, Yeh S, Albini TA, Mandelcorn E, et al. Cytomegalovirus retinitis in the absence of AIDS. *Can J Ophthalmol*. 2013; 48: 126-129.