

## Special Article - Clinical Case Reports &amp; Images

# Recurrence of Neovascularization Status Post Intravitreal Bevacizumab in a Patient with Retinopathy of Prematurity: A Case Report and Review

Zhang R and Orge FH\*

Department of Ophthalmology and Visual sciences, Case Western Reserve University Hospitals Eye Institute and Rainbow Babies and Children's Hospital, USA

\*Corresponding author: Orge FH, Department of Ophthalmology and Visual sciences, Case Western Reserve University Hospitals Eye Institute and Rainbow Babies and Children's Hospital, Cleveland, USA

Received: December 01, 2014; Accepted: February 23, 2015; Published: February 26, 2015

## Abstract

Avastin is fast becoming a treatment used by many pediatric ophthalmologists for treatment of advanced ROP. In this case report we present an infant who was given avastin in both eyes at 36 weeks of age for advanced ROP which caused the neovascularization to resolve. However, upon examination 19 months after treatment neovascularization was again noted, which lead to laser photocoagulation for additional therapy. This case illustrates the importance of frequent monitoring of ROP patients after avastin administration, as much is still to be learned about its pharmacokinetics in the infant population, and that potential complications can arise many months or even years after therapy. We also conducted a review of current literature in the use of avastin in infants with ROP

**Keywords:** Retinopathy of prematurity; Avastin; Retinal neovascularization

## Introduction

Retinopathy of Prematurity (ROP) is one of the leading causes of childhood blindness, with risk factors including prematurity, low birth weight, and the presence of supplemental oxygen for an extended amount of time. Globally, ROP is emerging to be a major healthcare concern, especially in middle and lower income families, where there is greater variation in gestational age and birth weight [1]. In ROP, vasoproliferative retinopathy occurs as a result of immature vasculature and occurs in two phases. Phase I begins after birth where premature infants are exposed to a hyperoxic environment. This leads to cessation of vascularization, and lasts approximately until 32 weeks of gestational age [2]. Phase II subsequently follows where the abnormal blood vessels form, likely instigated by the hypoxic environment which leads to an increase in growth factors and cytokines such as vascular endothelial growth factor (VEGF) and Insulin Growth Factor (IGF). The neovascularization can lead to plus disease, a poor prognostic sign.

The mainstay treatment for advanced ROP has conventionally been cryotherapy or laser photocoagulation. As evidenced by the ETROP study [3], laser ablation of infants with high-risk pre-threshold ROP significantly reduced unfavorable outcomes compared with controls. However, with the advent of ophthalmic usage of anti-VEGF agents, Bevacizumab (Bevacizumab) has been utilized in the treatment of advanced ROP. The BEAT-ROP trial found that intravitreal Bevacizumab was beneficial compared with laser therapy in infants with zone I stage 3 plus ROP [4]. Although anti-VEGF agents hold promise in becoming a mainstay ROP treatment, the long term benefits of Bevacizumab have not yet been clearly delineated, and no standardized protocol for follow up after administration in neonates has been established. In this case we present a patient with ROP where neovascularization resolved after administration of bevacizumab, but returned months later, and persisted leading to further treatment

with laser photocoagulation 19 months after initial treatment. This case illustrates the importance of close monitoring despite regression of disease after treatment of anti-VEGF therapy, and the array of management modalities available should neovascularization return after anti-VEGF treatment.

## Case Report

The patient is a former 26 week premature female with a history of grade IV intraventricular hemorrhage, seizures, and respiratory failure who was diagnosed with Retinopathy of Prematurity (ROP) stage 0 zone 2 on eye examination at 30 weeks gestational age. The patient was closely monitored, and on subsequent eye examination at 36 weeks gestational age was diagnosed with aggressive ROP with plus disease in all four quadrants of both eyes (Figure 1). Intravitreal bevacizumab (0.025mL at dose of 0.2MG/0.1mL) was administered at that time to both eyes without complication.

On subsequent eye examinations, the neovascularization and plus disease resolved (Figure 2) and the patient was monitored weekly until 40 weeks gestational age, then followed every two months with examination under anesthesia and fluorescein angiography. On examination at 10 months of age, tufts of neovascularization were noted inferotemporally in the retina of both eyes (Figure 3). The

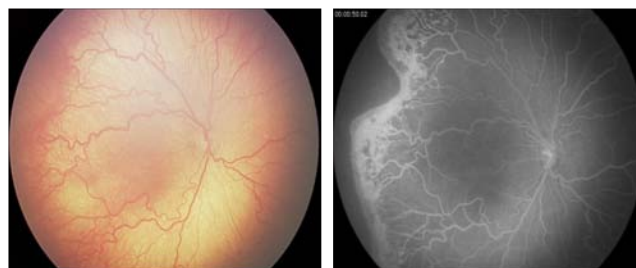

Figure 1: Plus Disease- OD.

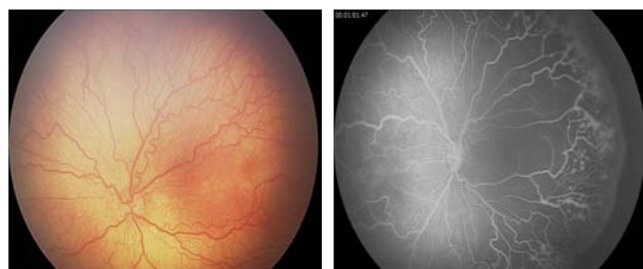


Figure 2: Plus Disease- OS.

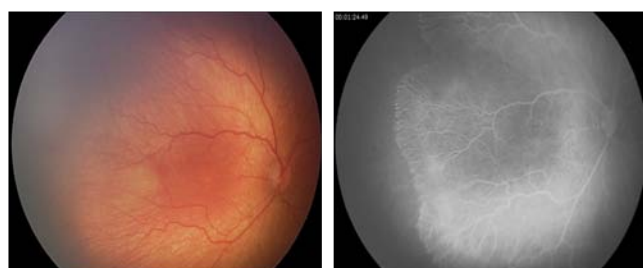


Figure 3: 1 month s/p avastin OD.

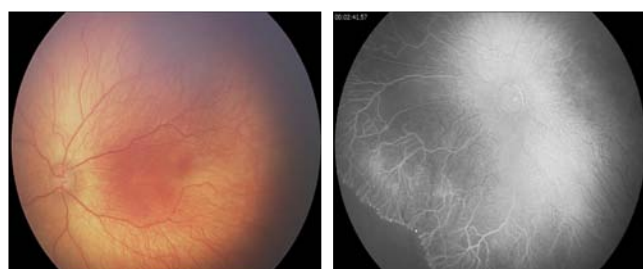


Figure 4: 1 month s/p avastin OS.

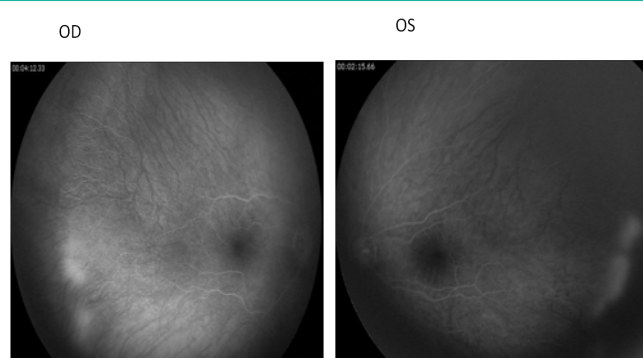


Figure 5: 19 months s/p avastin.

areas of neovascularization persisted on subsequent examinations, and indirect laser was applied to both eyes at 21 months of age without complication. At 2 months follow up at 23 months of age, the laser scars were noted to be intact, and on fundus photography no apparent neovascularization was noted (Figure 4). However, on fluorescein angiography persistent neovascularization was noted inferotemporally in both eyes (Figure 5), and further indirect laser was applied around the areas of neovascularization without complication. The patient was then set up for close follow up and future examination under anesthesia.

## Discussion

Anti-VEGF therapy is becoming an increasingly popular treatment option in ROP, as it is easily obtainable, financially inexpensive, and easily administered even in an outpatient clinical setting [5]. Given financial and resource limitations, many countries are adopting usage of bevacizumab as the sole treatment modality for treatment of ROP. However, long term data on use of bevacizumab in ROP is limited, and the timing, dosage and follow up status post bevacizumab therapy is high variable. Reports of return of neovascularization after anti-VEGF therapy have been reported [6], illustrating the importance of long term follow-up and close monitoring. We conducted a review of current literature on the use of bevacizumab in ROP, and found that various dosages and follow up schedules are employed for infants receiving bevacizumab for ROP, and various complications have been noted on subsequent exams which are discussed below.

In a recent study, Lepore et al studied 13 infants treated with 0.5mg bevacizumab for advanced ROP, and discovered that at 9 month follow-up using fluorescein angiography various vascular anomalies were found including abnormal shunting and branching, and absence of a foveal avascular zone in some eyes. The findings were not seen in lasered eyes [7]. Another study conducted in Mexico studied 47 eyes that received 0.75mg of intravitreal bevacizumab for stage 3 prethreshold disease, and found that in all eyes perivascular leakage decreased after treatment, and none of the eyes needed re-

treatment [8]. However, follow up was only extended to 6 months status post therapy. A study conducted in Chile by Bancalari et al used 0.625mg of bevacizumab as monotherapy for infants with stage 3 plus or stage 2 plus ROP in whom laser was contraindicated. Out of the 12 infants, bevacizumab was sufficient as monotherapy in 8 of the cases, with 4 requiring reintervention with laser [9]. Follow up was extended to 1 year following bevacizumab therapy. In a recent study conducted in Germany, 57 eyes were studied who received 0.375mg of intravitreal bevacizumab for ROP in Zone I and II with plus or extra retinal neovascularization. Mean follow up was 4.2 months with maximum of 45 months of follow-up, and reintervention was not needed except in one infant who was in a severely compromised state of health [10].

Interestingly, similar results were not found amongst all studies. A retrospective study conducted by Tahija et al studied 20 eyes who received intravitreal bevacizumab as monotherapy for zone I and zone II ROP. The study followed patients 5 years after therapy, and found that despite resolution of the disease, in 55% of the patients the peripheral retina remained incompletely vascularized [11]. In another study of 17 eyes which received a dose of 0.625-0.750mg of bevacizumab for ROP, all had recurrence of disease and necessitated additional treatment with mean age of recurrent found to be at 49 weeks with maximum of 69 weeks [12].

Intervention and follow up after anti-VEGF treatment in ROP patient remains to be standardized. Prior studies have shown perivascular leakage to be present on fluorescein angiogram after anti-VEGF treatment [13] in ROP patients. In addition, cases of reintervention with laser after anti-VEGF have also been documented [14]. In addition, even if neovascularization subsides after bevacizumab, close monitoring for an extended period of time is crucial, as perivascular leakage and neovascularization can return

months or years after therapy. Furthermore, bevacizumab has unknown systemic side effects and pharmacokinetics, especially when used in pre-mature and often immunocompromised infants [15].

Our case demonstrates the importance of long term monitoring of patients after anti-VEGF therapy, as evidenced by the existence of persistent avascular retina even 19 months after initial anti-VEGF therapy. In our patient, we chose to retreat with laser photocoagulation. However, both bevacizumab and laser have been used as treatment options for recurrence of neovascularization.

In the future, we hope to learn more about the pharmacokinetics of anti-VEGF therapy in ROP patients through large clinical trials and research populations. With increasing research and experience with anti-VEGF agents in ROP patients, we hope to be able to formulate the optimal timing, dosage, and follow up management for our patients.

## References

- Gilbert C. Retinopathy of prematurity: a global perspective of the epidemics, population of babies at risk and implications for control. *Early Hum Dev.* 2008; 84: 77-82.
- Mutlu FM, Sarici SU. Treatment of retinopathy of prematurity: a review of conventional and promising new therapeutic options. *Int J Ophthalmol.* 2013; 6: 228-236.
- Early Treatment For Retinopathy Of Prematurity Cooperative Group. Revised indications for the treatment of retinopathy of prematurity: results of the early treatment for retinopathy of prematurity randomized trial. *Arch Ophthalmol.* 2003; 121: 1684-1694.
- Mintz-Hittner HA, Kennedy KA, Chuang AZ; BEAT-ROP Cooperative Group. Efficacy of intravitreal bevacizumab for stage 3+ retinopathy of prematurity. *N Engl J Med.* 2011; 364: 603-615.
- Fleck BW. Management of retinopathy of prematurity. *Arch Dis Child Fetal Neonatal Ed.* 2013; 98: F454-456.
- Hu J, Blair MP, Shapiro MJ, Lichtenstein SJ, Galasso JM, Kapur R. Reactivation of retinopathy of prematurity after bevacizumab injection. *Arch Ophthalmol.* 2012; 130: 1000-1006.
- Lepore D, Quinn GE, Molle F, Baldascino A, Orazi L, Sammartino M, et al. Intravitreal Bevacizumab versus Laser Treatment in Type 1 Retinopathy of Prematurity: Report on Fluorescein Angiographic Findings. *Ophthalmology.* 2014; 121: 2212-2219.
- Henaine-Berra A, Garcia-Aguirre G, Quiroz-Mercado H, Martinez-Castellanos MA. Retinal fluorescein angiographic changes following intravitreal anti-VEGF therapy. *J AAPOS.* 2014; 18: 120-123.
- Bancalari MA, Schade YR, Peña ZR, Pavez PN. Intravitreal bevacizumab as single drug therapy for retinopathy of prematurity in 12 patients. *Arch Argent Pediatr.* 2014; 112: 160-163.
- Harder BC, von Baltz S, Jonas JB, Schlichtenbrede FC. Intravitreal low-dosage bevacizumab for retinopathy of prematurity. *Acta Ophthalmol.* 2014; 92: 577-581.
- Tahija SG, Hersetyati R, Lam GC, Kusaka S, McMenamin PG. Fluorescein angiographic observations of peripheral retinal vessel growth in infants after intravitreal injection of bevacizumab as sole therapy for zone I and posterior zone II retinopathy of prematurity. *Br J Ophthalmol.* 2014; 98: 507-512.
- Hu J, Blair MP, Shapiro MJ, Lichtenstein SJ, Galasso JM, Kapur R. Reactivation of retinopathy of prematurity after bevacizumab injection. *Arch Ophthalmol.* 2012; 130: 1000-1006.
- Henaine-Berra A, Garcia-Aguirre G, Quiroz-Mercado H, Martinez-Castellanos MA. Retinal fluorescein angiographic changes following intravitreal anti-VEGF therapy. *J AAPOS.* 2014; 18: 120-123.
- Bancalari MA, Schade YR, Peña ZR, Pavez PN. Intravitreal bevacizumab as single drug therapy for retinopathy of prematurity in 12 patients. *Arch Argent Pediatr.* 2014; 112: 160-163.
- Wallace DK, Wu KY. Current and future trends in treatment of severe retinopathy of prematurity. *Clin Perinatol.* 2013; 40: 297-310.