

Clinical Image

Bilateral Peripapillary Intrachoroidal Cavitation

Sadiki*, Brarou H; Achegri Y; Elkhoyaali A; Fiqhi A;
Mouzari Y; Oubaaz A

Department of Ophtalmology, Military Hospital
Mohamed V Rabat, Morocco

***Corresponding author: Sadiki**

Department of Ophtalmology, Military Hospital
Mohamed V Rabat, Morocco.
Email: sadi.samah@gmail.com

Received: March 18, 2024

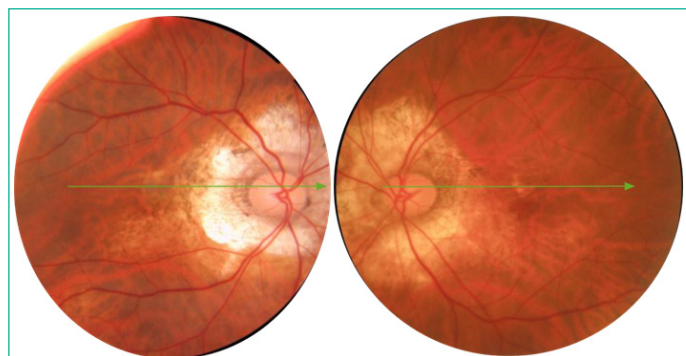
Accepted: April 19, 2024

Published: April 26, 2024

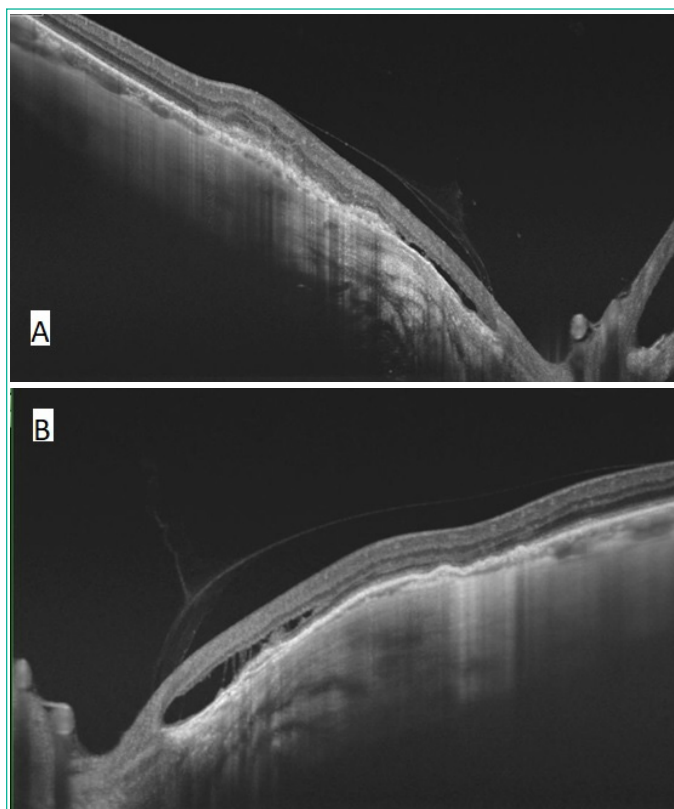
Clinical Image

Intrachoroidal cavitation is an abnormality of the choroid found most frequently in high myopic eyes. It was proposed that it's the result of a choroid retraction away from the optic disc margin during staphyloma progression in myopic eyes. Peripapillary intrachoroidal cavitation are considered benign non progressive myopic lesions.

We report the case of a 65 years old male, who presented to the ophtalmological with a gradual decline in vision in both eyes. The ophtalmological examination found a best-corrected visual acuity (BCVA) was 2/10 in both eyes with the following refraction: $-10,00$ ($-1,00 \times 85^\circ$) in the right eye (OD) and -8.50 ($-1,75 \times 100^\circ$) in the left eye (OS). Slit lamp examination found a clear cornea, normal anterior chamber depth, intraocular pressure of 16 mmHg. Fundus exam showed a bilateral well-defined yellow lesion located surrounding the border of the disc. Spectral-domain Optical coherence tomography was performed and showed intrachoroidal hypo-reflective space.



Colour fundus: Bilateral yellowish peripapillary lesion.



Colour fundus: Optical coherence tomography showing an hypo-reflective space below the RPE in the right (A) and left (B) eye.