

Short Communication

Slipknot: An Ameliorated Technique for Pterygium Conjunctival Autograft

Huiying Zhang; Ling Jiang; Qiong Li*

Department of Ophthalmology, Provincial Clinical Medical College of Fujian Medical University, Fujian Provincial Hospital, PR China

*Corresponding author: Qiong Li

Ophthalmology Department, Provincial Clinical Medical College of Fujian Medical University, Fujian Provincial Hospital, Fuzhou, 350001, PR China.

Tel: 0591-88217110; Fax: +86059187557768

Email: liqiong2000@hotmail.com

Received: September 08, 2023

Accepted: October 04, 2023

Published: October 11, 2023

Introduction

Pterygia are wing-shaped conjunctival encroachments onto the cornea [1]. Conjunctival autograft adhesion with fibrin glue has gained rapid popularity in pterygium excision surgery [2]. Suture technique is another major option to fix the graft. An absorbable suture with slipknot was used to fix the grafts of pterygium. A week after the surgery, most of the stitches had disintegrated and fallen out. This easy technique reduces the postoperative pain and the conjunctival reaction in the early postoperative period. It enables the surgeon to eliminate the need for postoperative suture removal, and relieve the patient's anxiety of removing stitches during the review.

Surgical Technique

Pterygium excision and conjunctival autograft can be performed as routinely [3]. 8-0 Coated VICRYL (Polyglactin 910, Ethicon LLC) sutures were used to fixate the graft on the scleral bed. Tie a knot on the receiving site (Figure 1a), and double knotting (Figure 1b). It was important to knot it tightly. After about a week, most of the conjunctival sutures were disintegrated and fallen out. The graft conjunctiva healed well (Figure 1c,d & e). The knot was delayed in shedding when the suture had attached the scleral tissue (Figure 1f). Bandage contact lenses were use and removed after a week. Follow-up examinations were routinely performed at 1 week and 1 month after surgery.

This method of ameliorated technique, to the knowledge of the authors, never been reported before. It makes surgery and post-operative review much easier.

Abstract

Conjunctival autograft was now the best method in pterygium operation. An absorbable suture with slipknot was used to fix the grafts of pterygium. A week after the surgery, most of the stitches had disintegrated and fallen out. This easy technique reduces the postoperative pain and the conjunctival reaction in the early postoperative period. It enables the surgeon to eliminate the need for postoperative suture removal, and relieve the patient's anxiety of removing stitches during the review.

Keywords: Pterygium surgery; Conjunctival graft; Slipknot; Sutures

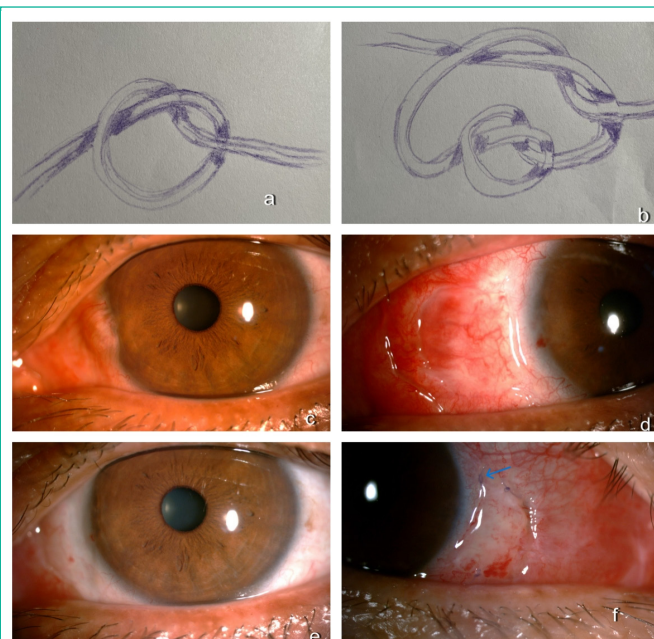


Figure 1: Tie a knot (a) and double knotting (b). Pre-operation (c). All of the conjunctival sutures were fallen out 12 days after surgery (d). Slight conjunctival reaction 4 weeks after surgery (e). The knot (blue arrow, 7days after surgery) was delayed in shedding, when the suture has attached the scleral tissue in another case (f).

Author Statements

Disclosure

The authors report no conflicts of interest in this work.

References

1. Koranyi G, Seregard S, Kopp ED. The cut-and-paste method for primary pterygium surgery: long-term follow-up. *Acta Ophthalmol Scand.* 2005; 83: 298-301.
2. Tappin MJ, Sanchez-Taberner S, Sabatino F. Glue and glide: a novel technique for pterygium conjunctival autograft. *Clin Ophthalmol.* 2018; 13: 25-6.
3. Yüksel B, Unsal SK, Onat S. Comparison of fibrin glue and suture technique in pterygium surgery performed with limbal autograft. *Int J Ophthalmol.* 2010; 3: 316-20.