

## Clinical Image

# When the Cataract Takes on an Unusual Appearance

Najoua El M\* and Hilali Z

Department of Ophthalmology, "A", Ibn Sina University Hospital, Mohammed V University, Rabat, Morocco

\*Corresponding author: Najoua El Moubarik

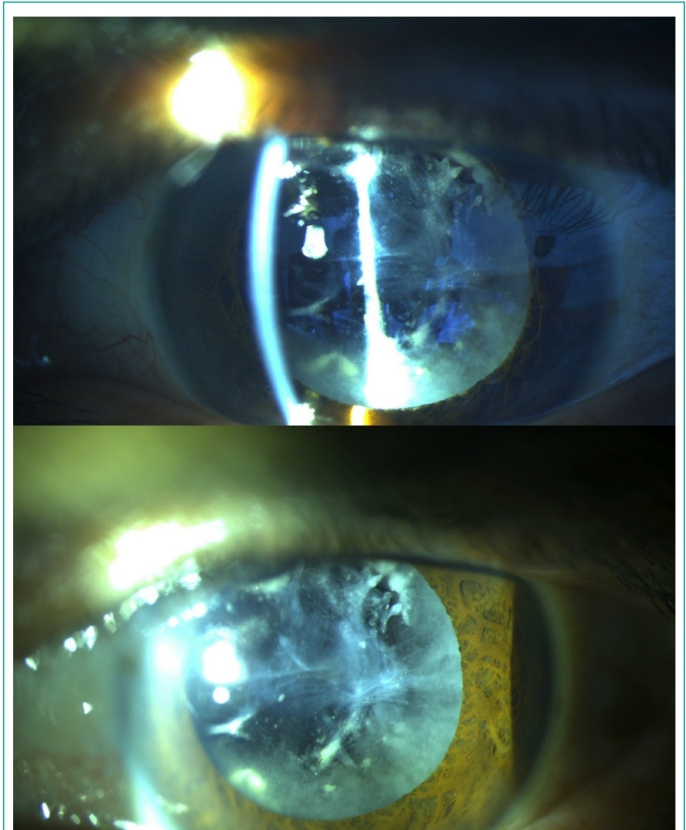
Department of ophthalmology "A", Ibn Sina University Hospital (Hôpital des Spécialités), Mohammed V University, Rabat, Morocco

Received: January 12, 2023; Accepted: March 07, 2023;

Published: March 14, 2023

## Description

We report the case of a 56 year -old patient, with the notion of a neglected ocular trauma of the right eye 6 years ago, with a progressive decrease in visual acuity for 4 years. The ophthalmological examination of the right eye showed a visual acuity with finger movement, an ocular tone of 15 mmhg with a regressive cataract in the anterior segment with a retracted aspect and an embossed anterior surface. Ocular ultrasound was performed and returned normal. The ophthalmological examination of the left eye did not reveal any abnormality. A phacoemulsification cataract surgery was performed with a good postoperative evolution.



**Figure 1:** biomicroscopic image of the right eye showing a regressive cataract.