

## Research Article

# Aflibercept – How does it compare with other Anti-VEGF Drugs?

Yog Raj Sharma\*, Koushik Tripathy, Pradeep Venkatesh and Varun Gogia

Department of Ophthalmology, All India Institute of Medical Sciences, India

\*Corresponding author: Yog Raj Sharma, Department of Ophthalmology, All India Institute of Medical Sciences, New Delhi, India

Received: February 14, 2014; Accepted: March 12, 2014; Published: March 21, 2014

## Abstract

Aflibercept is the newest approved anti-VEGF drug for intraocular use. This chimeric protein targets vascular endothelial growth factors: VEGF-A, VEGF-B and placental growth factor (PlGF). In this article, we review the available literature regarding this drug's ocular use in a clinician's perspective. Aflibercept has higher affinity, less frequent dosing, equivalent cost of therapy, non-inferiority to ranibizumab in efficacy and safety. It is effective in choroidal neovascular membrane, macular edema following venous occlusion, retinal pigment epithelial detachment or diabetic macular edema that is recurrent or resistant to ranibizumab. It penetrates all retinal layers and does not induce apoptosis. Thus it promises to be a useful addition to anti-VEGF therapies already available for managing an array of retinal disorders.

**Keywords:** Aflibercept; VEGF-trap Eye; Eylea; ARMD; Ranibizumab; Bevacizumab; VEGF; Anti-VEGF; Diabetic Macular Edema; Macular edema following venous occlusion.

## Introduction

For people older than 50 years, age related macular degeneration (AMD) causes approximately 46% of cases of severe visual loss (visual acuity 20/200 or worse) in United States [1]. Neovascular or wet AMD (wAMD) is responsible for almost 90% of severe vision loss due to AMD [2]. AMD causes 5% of Global blindness [3]. Pegaptanib (Macugen®, Eyetech Inc, Florida, USA) was the first anti-VEGF drug approved by food and drug administration (FDA, USA) for subfoveal choroidal neovascular membrane (CNVM) due to wAMD in 2004 [4]. Now, anti-VEGF drugs have become gold standard treatment for CNVM due to AMD. Currently there are 4 drugs in this category—aptamer (Pegaptanib), monoclonal antibodies (Ranibizumab or Lucentis®, Genentech Inc, San Francisco, USA and bevacizumab Avastin®, Genentech, USA, off label use) and chimeric protein (Aflibercept®, VEGF-trap eye, Eylea, Regeneron Pharmaceuticals, NY, USA).

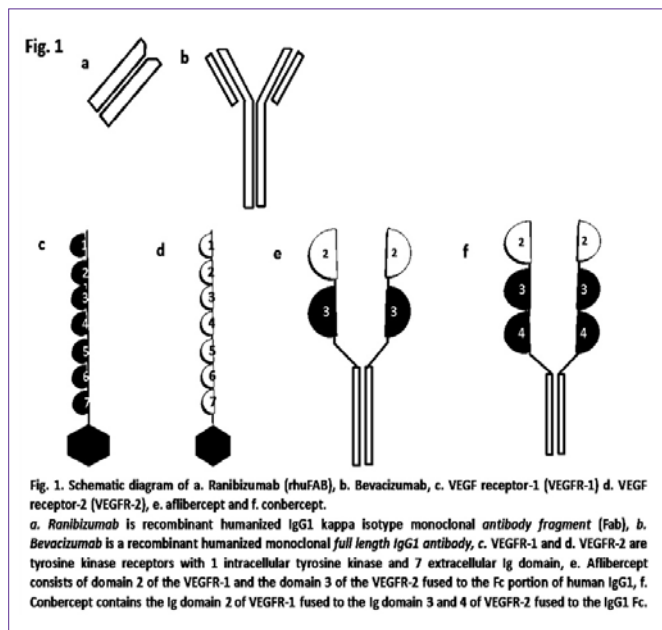
### The Vascular endothelial growth factor (VEGF): chronological perspective

In 1948, Isaac Michaelson was the first to postulate that a diffusible factor produced by the retina (“factor X”) was responsible for retinal and iris neovascularization associated with conditions such as proliferative diabetic

retinopathy and central retinal vein occlusion [5]. In 1983, Senger and Galli et al., [6]. Identified a protein that could induce vascular leakage in skin. They named this protein “tumor vascular permeability factor” or VPF. In 1989, Ferrara and Henzel [7] isolated a diffusible protein from bovine pituitary follicular cells that showed cell specific mitogenic activity for vascular endothelium. They named this protein vascular endothelial growth factor (VEGF). VPF and VEGF seemed to have the similar molecular structure. VEGF is produced by the retinal pigment epithelial cells (RPE), all types of neurons, glia, pericytes, macrophage, smooth muscle cells, T cells and endothelial cells of

the retina in response to hypoxia through hypoxia-inducible factor 1 (HIF-1), which is a basic helix-loop-helix transcription factor and inflammatory stimuli [8]. The VPF/VEGF [now called VEGF-A, to differentiate from other related genes: VEGF-B, VEGF-C, VEGF-D, and PlGF (placental growth factor)] gene is at chromosome 6p21.3. VEGF-A is a key regulator of blood vessel growth [9]. VEGF-B is a ‘survival factor’ for blood vessels and neurons [9]. VEGF-C and VEGF-D regulate lymphangiogenesis [9,11]. Alternative splicing of VEGF-A gives rise to at least 6 different protein isoforms -121, 145, 165, 183, 189, and 206 amino acids in length [12]. The larger isoforms (VEGF-189 and VEGF-206) bind heparin with high affinity and are sequestered in the extracellular matrix. The smaller isoform, VEGF-121, does not bind heparin and is freely diffusible. VEGF-165 has both bioavailability and biologic potency. VEGF-165 is the predominant isoform and the primary mediator of neovascularization in the eye [13]. All VEGF isoforms contain a plasmin cleavage site. Cleavage at this site creates a freely-diffusible, 110-kD, bioactive form of VEGF (VEGF-110). VEGF has 3 receptor tyrosine kinases: VEGFR-1, VEGFR-2 (Figure 1), and VEGFR-3. VEGFR-1 (Flt-1) the first discovered & highest affinity receptor of the three, functions to act during embryonic development as a “decoy” by sequestering VEGF, thereby preventing the activation of VEGFR-2 [13]. VEGFR-1 also plays a key role in pathological ocular neovascularization through mediating monocyte chemotaxis to VEGF. VEGFR-2 (Flk-1 or KDR) is the primary mediator of the pathologic effects of VEGF in the eye [12]. VEGFR-3 helps lymphangiogenesis [14]. All three receptors are necessary for proper mammalian development. Mice with null mutations for any of the receptors die in utero between days 8.5 and 9.5 [15]. VEGFR-2 knock-out models also suggest the possible role of VEGF in hematopoiesis [16]. VEGF is pro-angiogenic. It stimulates endothelial cell proliferation (mitogenic), invasion, migration, and enhancement of cell survival [9].

It also increases vascular permeability (50000 times more



potent than histamine in producing vascular leakage) [17] by both vasodilatation and an uncoupling of endothelial tight junctions. Vascular leakage is thought to facilitate angiogenesis because the leakage of plasma proteins and fibrin creates a gel-like environment conducive to endothelial cell growth and migration. Increased vascular permeability may be mediated via the nitrous oxide synthase (NOS) pathway [18], which may explain why hypertension has been observed in some patients treated with VEGF inhibitors.

### Earlier anti-VEGF drugs

*Pegaptanib sodium* is an aptamer. Chemically it is covalent conjugate of an oligonucleotide of twenty-eight nucleotides in length that terminates in a pentylamino linker, to which two 20-kilodalton monomethoxy polyethylene glycol (PEG) units are covalently attached via the two amino groups on a lysine residue. In order to prolong activity at the site of action, the sugar backbone of pegaptanib was modified to prevent degradation by endogenous endonucleases and exonucleases. The polyethyleneglycol moieties were added to increase the half-life of the drug in the vitreous humor [19,20]. Its molecular weight is 50 kilodalton. Pegaptanib adopts a three-dimensional conformation that enables it to bind to extracellular VEGF. Pegaptanib binds to the major pathological VEGF isoform, extracellular VEGF165. It has no known immunogenicity unlike other anti-VEGF drugs which are proteins. The recommended dose is 0.3mg as intravitreal injection (IVT) once every 6weeks. In humans, after a 3 mg monocular dose (10 times the recommended dose), the average apparent plasma half-life of pegaptanib is 10 days [21]. After IVT injection in monkey, half-life in vitreous is 3.8days, and serum half-life is 3.6-4.3 day [19]. It penetrates all retinal layers [22]. It is FDA approved for wet AMD.

*Ranibizumab* is a recombinant humanized IgG1 kappa isotype monoclonal antibody fragment (Figure 1a). Ranibizumab binds to all isoforms of VEGF-A including the biologically active, cleaved form of this molecule, VEGF110. It has a molecular weight of approximately 48 kilodaltons as it lacks an Fc region unlike Bevacizumab (Figure

1b). Ranibizumab has 17-fold higher binding capacity as compared with Bevacizumab [23]. On a molar basis, ranibizumab was 5 to 20 fold more potent than full-length Bevacizumab [24]. It is produced by an *E. coli* expression system in a nutrient medium containing tetracycline. Tetracycline is not detectable in the final product. It is slightly immunogenic. In animal studies, following intravitreal injection, ranibizumab was cleared from the vitreous with a half-life of 2.9 days [25]. Based on the disappearance of ranibizumab from serum, the estimated average elimination half-life following intravitreal injection was approximately 9 days in human [26]. It penetrates all retinal layers including retinal pigment epithelium (RPE) and choroid [22]. It is approved by FDA for Neovascular (Wet) AMD and Macular Edema following Retinal Vein Occlusion (RVO) at a dose of 0.5 mg intravitreally every month (approximately 28 days). It is also approved for Diabetic Macular Edema (DME), the dose being 0.3mg intravitreally once a month (approximately 28 days). The clinical superiority of ranibizumab over both observation and photodynamic therapy in wAMD was shown in both the MARINA [27] and ANCHOR [28]. The most common ocular side effect is conjunctival hemorrhage in up to 74% cases and most common extra-ocular side effect is nasopharyngitis in up to 16% cases [26]. Currently it is the gold standard treatment for wet AMD and any new drug is compared with it for efficacy and safety.

*Bevacizumab* is a recombinant humanized monoclonal IgG1 antibody (Figure 1b-d) that binds to and inhibits the biologic activity of all isoforms of human VEGF-A. Bevacizumab contains human framework regions and the complementarity-determining regions of a murine antibody that binds to VEGF. Bevacizumab has an approximate molecular weight of 149 kilodaltons. Bevacizumab is produced in a mammalian cell (Chinese Hamster Ovary) expression system in a nutrient medium containing the antibiotic gentamicin. Gentamicin is not detectable in the final product. It is approved for Metastatic Colorectal Cancer (mCRC), Non-Squamous Non-Small Cell Lung Cancer (NSCLC), Glioblastoma and Metastatic Renal Cell Carcinoma (mRCC) as intravenous (IV) infusion. The intravitreal use is not approved by FDA (off label use), though it is widely used for wet AMD in view of low cost and similar safety and efficacy like ranibizumab (CATT [29] and IVAN trial [30]). It is used as 1.25mg intravitreal injection. It was first tried intravenously for wet AMD (SANA trial) [31,32]. Serum half-life after IV administration is 20 days for male and 18 days for female [33]. After intravitreal administration half-life in vitreous is 5-10days [34,35]. The bevacizumab molecule can penetrate the retina and is also transported into the retinal pigment epithelium, the

Choroid and in particular, into photoreceptor outer segments after intravitreal injection [36]. Fab of Ranibizumab and Bevacizumab is different in 6 amino acids; 5 at heavy chain and 1 at light chain.

### The VEGF-trap Eye or Aflibercept

**Chemistry:** Aflibercept is a recombinant fusion protein (Figure 1e) consisting of second binding domain of the VEGFR-1 receptor and the third domain of the VEGFR-2 receptor fused to the Fc portion of human IgG [37]. It has very high VEGF binding affinity ( $K \approx 1$  pM) [38,39]. It has at least a 200 fold higher affinity for VEGF than ranibizumab [40]. Aflibercept is a dimeric glycoprotein with a protein molecular weight of 97 kilodaltons and contains glycosylation,

constituting an additional 15% of the total molecular mass, resulting in a total molecular weight of 115 kilodalton. Aflibercept is produced in recombinant Chinese hamster ovary (CHO) cells. The terminal elimination half-life ( $t_{1/2}$ ) of free aflibercept in plasma was approximately 5 to 6 days after I.V. administration of doses of 2 to 4 mg/kg aflibercept [41]. Initially intravenous aflibercept was tried for AMD [42]. It is approved in combination with 5-fluorouracil, leucovorin, and irinotecan (FOLFIRI) for the treatment of patients with metastatic colorectal cancer [43]. It is being investigated for advanced solid tumors, glioblastoma [44], pediatric solid tumors [45], recurrent ovarian, primary peritoneal, or fallopian tube cancer [46], recurrent or metastatic gynecologic carcinomas and uterine leiomyosarcoma [47] and non-small cell lung cancer (NSCLC).

**Mechanism of action:** Aflibercept acts as a soluble decoy receptor that binds VEGF-A, VEGF-B and PlGF [40]. VEGF-A binds to both VEGFR-1 and VEGFR-2 but PlGF binds to only VEGFR-1. Aflibercept thus inhibits the binding and activation of these cognate VEGF receptors.

**Indication and dosage:** It is FDA approved for Neovascular (Wet) AMD [48]. The recommended dose is 2 mg intravitreally every 4 weeks (monthly) for the first 12 weeks (3 months), followed by 2 mg (0.05 ml) via intravitreal injection once every 8 weeks (2 months). Although it may be dosed as frequently as 2 mg every 4 weeks (monthly), additional efficacy was not demonstrated compared to every 8 weeks dose.

It is also approved for Macular Edema following Central Retinal Vein Occlusion (CRVO) [49] in a dose of 2 mg (0.05 ml) administered by intravitreal injection once every 4 weeks (monthly).

The intravitreal injection should be given with proper aseptic technique with 30G needle. It is available as 2mg/0.05ml single use vial.

### The clinical experience with aflibercept

**Wet AMD:** Two randomized, double-masked, multi-center, active-controlled, phase III studies in patients with wet AMD compared aflibercept with ranibizumab monthly intravitreal injections. 2419 patients with active, subfoveal, choroidal neovascularization (CNV) lesions (or juxtafoveal lesions with leakage affecting the fovea) secondary to AMD were evaluated (VIEW 1 and VIEW 2) [50]. In each study, patients were randomly assigned in a 1:1:1:1 ratio to 1 of 4 dosing regimens: intravitreal aflibercept 0.5 mg monthly (0.5q4), 2 mg monthly (2q4), 2 mg every 2 months after 3 initial monthly doses (2q8), or ranibizumab 0.5 mg monthly (Rq4). The VIEW 1 (VEGF Trap-Eye: Investigation of Efficacy and Safety in Wet AMD) study was conducted in the United States and Canada. The VIEW 2 study was conducted in Europe, Asia Pacific, Japan, and Latin America.

The primary end point was non inferiority (margin of 10%) of the aflibercept regimens to ranibizumab in the proportion of patients maintaining vision at week 52 (losing <15 letters on Early Treatment Diabetic Retinopathy Study [ETDRS] chart). With aflibercept 2 monthly injections 95-96% patients maintained visual acuity at 1 year (lost less than 15 letters in ETDRS chart) compared with 94-95% patients taking monthly ranibizumab injection.

Mean change in best corrected visual acuity gain at 1 year with aflibercept 2 monthly was 7.9 and 8.9 letters v/s 8.1 and 9.4 letters respectively with ranibizumab monthly injections in VIEW 1 and View 2.

31% patients gained at least 15 letters at 1 year with aflibercept 2 monthly injections compared with 31-34% patients with monthly ranibizumab.

The results with aflibercept are comparable with studies done on ranibizumab (MARINA [27] and ANCHOR [28]) previously with 2 year results. With monthly ranibizumab injection 90-93% patient maintained vision, 30-37% gained at least 15 letters and visual acuity gain was 5.5 to 10.9 letters.

CLEAR-IT2 (Clinical Evaluation of Anti-angiogenesis in the Retina Intravitreal Trial [51]) was the phase II study which showed significant benefit with intravitreal aflibercept in wet AMD. As needed (PRN- pro re nata) dosing with aflibercept at weeks 16-52 maintained the significant anatomic and vision improvements established during the 12-week fixed-dosing phase with a low frequency of reinjection's.

### Macular edema following central retinal vein occlusion (CRVO)

Two randomized, multi-center, double-masked, sham-controlled studies (COPERNICUS and GALILEO) [52,53] were undertaken in patients with macular edema following CRVO. A total of 358 patients were treated and evaluated for efficacy (217 with aflibercept) in the two studies. In both studies, patients were randomly assigned in a 3:2 ratio to either 2 mg aflibercept administered every 4 weeks (2Q4) or sham injections (control group) administered every 4 weeks for a total of 6 injections. At 52 weeks 56-60% patients achieved primary endpoint (gained at least 15 letters in ETDRS chart) compared with 12-22% with sham. Mean letter gain at 52 weeks was 17.3- 18 with monthly aflibercept compared with 4 letter loss to 3.3 letter gain with sham.

The effect of ranibizumab in macular edema in retinal venous occlusion was studied in BRAVO [54] (for branch retinal venous occlusion) and CRUISE [55] (for central retinal venous occlusion) with 6 months follow up. With 0.5mg ranibizumab monthly injections there was 18.3 to 14.9 letter gain and 48-61% patients gained at least 15 letters. Macular laser was needed in only 20% patients in ranibizumab group compared with 54% in sham group in BRAVO study.

**Myopic CNVM:** VEGF Trap-Eye in Choroidal Neovascularization Secondary to Pathologic Myopia (mCNV) (Phase III Myrror trial) [56,57] has shown encouraging results. MYRROR is a Phase 3, multicentre, randomized, double-masked, sham-controlled study in myopic CNV. The patients received 1 injection of intravitreal aflibercept 2 mg or sham injection at baseline, followed by monthly assessments until Week 24. At Week 24, patients in the sham arm were switched to intravitreal aflibercept 2 mg arm. Additional injections were given in case of persistence or recurrence of CNV. Total 122 patients had enrolled for the study. At Week 24, patients gained 12.1 letters with aflibercept and lost 2.0 letters with sham. By Week 48, patients gained 13.5 and 3.9 letters in the aflibercept and 'sham switched to aflibercept' groups, respectively. The incidence of ocular events was similar (37.4% and 38.7) between groups. Various



studies are undergoing to further evaluate role of aflibercept in myopic CNVM.

The role of ranibizumab in the same condition has been evaluated in more detail. In REPAIR study [58] patients received 0.5 mg ranibizumab administered intravitreally to the study eye, followed by monthly injections given as needed (based on a predefined algorithm) for up to 11 months. At 6 months, mean BCVA improved from baseline by 12.2 letters. Central macular thickness improved from baseline by 108 µm in the 48 study eyes of 48 patients. In other studies the BCVA improvement with ranibizumab has been shown as 7 letters in 4 years [59], 8 letters at 3 years [60], 12 letters after mean follow-up for 15.9 months [61]. RADIANCE [62] was a phase III randomized study to compare ranibizumab 0.5mg and verteporfin photodynamic therapy (vPDT). It showed that, ranibizumab provided superior BCVA gains versus vPDT up to month 3. Ranibizumab treatment guided by disease activity criteria was non inferior to visual acuity stabilization criteria up to month 6.

The efficacy of aflibercept in myopic CNVM needs further evaluation, though the available results are encouraging.

**Diabetic macular edema (DME):** In the Vinci study [63] DME patients were assigned randomly to 1 of 5 treatment regimens: VEGF Trap-Eye 0.5 mg every 4 weeks (0.5q4); 2 mg every 4 weeks (2q4); 2 mg every 8 weeks after 3 initial monthly doses (2q8); or 2 mg dosing as needed after 3 initial monthly doses (2PRN), or macular laser photocoagulation. Mean improvements in BCVA in the VEGF Trap-Eye groups at week 52 were 11.0, 13.1, 9.7, and 12.0 letters for 0.5q4, 2q4, 2q8, and 2PRN regimens, respectively, versus -1.3 letters for the laser group. Proportions of eyes with gains in BCVA of 15 or more ETDRS letters at week 52 in the VEGF Trap-Eye groups were 40.9%, 45.5%, 23.8%, and 42.2% versus 11.4% for laser. Mean reductions in Central Retinal Thickness (CRT) in the VEGF Trap-Eye groups at

week 52 were -165.4 µm, -227.4 µm, -187.8 µm, and -180.3 µm versus -58.4 µm for laser.

2 year results of RISE and RIDE [64] trials for ranibizumab in DME showed that 98% patients maintained vision (lost less than 15 letters) with 0.3mg monthly injections, 34-45% patients gained at least 15 letters; mean visual acuity gain was 10.9 to 12.5 letters. Only 45-49% patients needed macular laser compared with 91-94% in control group. No additional benefit was seen with 0.5mg monthly versus 0.3mg ranibizumab monthly.

**The aflibercept advantage**

High affinity, less frequent dosing, equivalent cost-effectiveness [52], non-inferiority to ranibizumab in efficacy and safety and effectiveness in CNVM, PED (retinal pigment epithelial detachment) or DME recurrent or resistant to ranibizumab makes aflibercept a very promising drug for future. Aflibercept was found to be effective for patients with Polypoidal Choroidal Vasculopathy who develop tachyphylaxis to ranibizumab (complete lack of response after initial treatment response to ranibizumab) [65]. It promises potential to reduce the risk of monthly intravitreal injections and the burden of monthly monitoring [66]. Deissler and Deissler et al., [67] showed that migration but not proliferation of immortalized bovine retinal endothelial (REC) cells is suppressed by ranibizumab. VEGF-mediated signaling through VEGFR-2 seems to control REC migration dominantly in the presence of other growth factors. This may indicate a potential advantage of aflibercept at cellular level. It has been shown that intraocular PlGF production induces vascular and retinal changes similar to those observed in the early stages of diabetic retinopathy [68]. Of all available anti- VEGF drugs only aflibercept acts against PlGF. Aflibercept is thought to penetrate all layers of the retina.

Lutty and McLeod et al., [69] showed that aflibercept not only

**Table 1:** Ongoing trials on intravitreal aflibercept.

Name of the ongoing trials on aflibercept	ClinicalTrials.gov identifiers	Clinical condition
ATLAS	NCT01773954	Age related macular degeneration (AMD)
ROLL	NCT01670162	Persistent Pigment epithelial Detachments in AMD
EVEN	NCT01722656	Submacular Vascularized Pigment Epithelial Detachment
NVAMD*	NCT01712035	AMD
NEWTON	NCT01870427	Previously Treated Macular Edema Associated With Central Retinal Vein Occlusions
ARChiMEDES	NCT01857544	Recalcitrant Central Retinal Vein Occlusion Associated Macular Edema Despite Prior Anti-VEGF Therapy.
VIVID EAST	NCT01783886	Diabetic Macular Edema (DME) With Central Involvement
VIVID DME	NCT01331681	DME
VISTA DME	NCT01363440	DME
Protocol T†	NCT01627249	DME
ACT	NCT01813773	Proliferative Diabetic Retinopathy
HANDLE	NCT01790893	Presumed ocular histoplasmosis
ANDROID‡	NCT01724554	Capillary Non-Perfusion
EPIC	NCT01871376	Polypoidal Choroidal Vasculopathy With Hemorrhage or Exudation

\*OCT Evaluation of Treated and Untreated Choroidal Neovascular Membranes in Age-Related Macular Degeneration

†Comparative Effectiveness Study of Intravitreal Aflibercept, Bevacizumab, and Ranibizumab for DME

‡To determine mean change in the presence and amount of capillary non-perfusion as measured by wide-angle angiography using Optos 200Tx system in subjects with proliferative retinopathy and/or macular edema secondary to proliferative diabetic retinopathy and central retinal venous occlusive disease.

**Table 2:** Comparison between clinical results of Aflibercept and Ranibizumab.

Year	Aflibercept	Ranibizumab
<b>Wet Age Related Macular Degeneration</b>		
Patients maintaining visual acuity(losing less than 15 letters in ETDRS chart)	95-96% at 1 year(VIEW1 & VIEW2 [50] )	94-95% at 1 year [50] 90-93% at 2 year ( MARINA [27] and ANCHOR [28] )
Mean change in best corrected visual acuity	+7.9 & +8.9 [50] at 1 year	+8.1 and 9.4 at 1 year [50] +5.5 [27] & +10.9 [28] at 2 years
Patients gaining at least 15 letters	31% [50] at 1 year	30-37% [27,28] at 2 years 31-34% [50] at 1 year
<b>Diabetic macular edema</b>		
<b>Macular Edema Following Central Retinal Vein Occlusion</b>		
Patients gaining at least 15 letters	56-60% (COPERNICUS and GALILEO) [52,53] at 52 weeks	48% (CRUISE [55]) at 6 months
Mean change in best corrected visual acuity	+17.3 to +18 at 52 weeks [52,53]	+14.9 at 6 months [55]
Patients gaining at least 15 letters	23.8%-45.5% at 52 weeks ( da Vinci study [57] )	34-45% (RISE and RIDE [58])
Mean change in best corrected visual acuity	+9.7 to +13.1 at week 52	+10.9 to +12.5 at 2 years [58]

stops the growth and induce regression of experimental CNV, but also inhibits the associated inflammation and fibrotic responses.

Schnichels and Hagemann et al., showed that aflibercept does not cause changes in cell morphology, induce apoptosis or cause permanent decrease in cell viability, cell density or proliferation in any cell line or concentration investigated. In general, aflibercept had fewer effects (up regulation or down regulation) compared with controls than bevacizumab or ranibizumab in their study [70].

Seventy-nine days after a single VEGF Trap (1.15 mg) injection, the intravitreal VEGF-binding activity would be comparable to ranibizumab at 30 days according to a mathematical model [71].

In cell-based bioassays, VEGF Trap inhibited the activation of VEGFR1 and VEGFR2, as well as VEGF-A induced calcium mobilization and migration in human endothelial cells more potently than ranibizumab or bevacizumab [72]. The benefits of this new drug may be potentially extended for corneal neovascularization [73], retinopathy of prematurity [69] and other vascular disorders.

### Safety of the anti-VEGF drugs

With all intravitreal injections there is risk of endophthalmitis, retinal detachment (RD), cataract and intra-ocular pressure (IOP) rise. The most common adverse reactions ( $\geq 5\%$ ) reported in patients receiving aflibercept or ranibizumab were conjunctival hemorrhage, eye pain, cataract, vitreous detachment, vitreous floaters, and increased intraocular pressure. Retinal pigment epithelium tear may occur after intravitreal aflibercept injection [74].

Mansour and Shahin et al., [75] showed that overall risk of ocular vascular events (vascular occlusions) following a VEGF antagonist injection was 0.108% in the general population and 2.61% in the diabetic population. Mean retinal arterial constriction after intravitreal bevacizumab was 21% and mean retinal venous constriction was 8%. Ocular vascular occlusions may lead to severe visual loss (even no perception of light) and may be caused by the vasoconstrictor effect of the drug, a post-injection rise of intraocular

pressure, patient stress as a result of the procedure and the patient's natural history of underlying ocular (eg. glaucoma) or systemic diseases. Intravitreal VEGF antagonists may cause enlargement of the foveal a vascular zone which may indicate an increase in retinal ischemia [76]. Data indicating geographic atrophy as a possible result of repeated pan-VEGF blocking is emerging [29].

Non-ocular adverse events ( $\geq 5\%$ ) with ranibizumab are nasopharyngitis, anemia, nausea, cough, constipation, seasonal allergy, hypercholesterolemia, influenza, renal failure, upper respiratory tract infection, gastro esophageal reflux disease, headache, peripheral edema, chronic renal failure, peripheral neuropathy, sinusitis, bronchitis, atrial fibrillation, arthralgia, chronic obstructive pulmonary disease, wound healing complications.

Common systemic adverse events with aflibercept include hypertension, nausea, and congestive heart failure [63].

There is a potential risk of arterial thromboembolic events (ATEs) following intravitreal use of VEGF inhibitors. ATEs are defined as nonfatal stroke, nonfatal myocardial infarction, or vascular death (including deaths of unknown cause). The incidence in the VIEW1 and VIEW2 wet AMD studies during the first year was 1.8% (32 out of 1824) in the combined group of patients treated with aflibercept. The incidence in the COPERNICUS and GALILEO studies during the first 6 months was 0% (0/218) in patients treated with aflibercept 2 mg every 4 weeks compared with 1.4% (2/142) in patients receiving sham treatment. In the controlled neovascular AMD studies (MARINA, ANCHOR) at second year, the ATE rate was 2.6% (19 of 721) in the combined group of ranibizumab treated patients compared with 2.9% (10 of 344) in patients from the control arms. In a pooled analysis of DME Studies (RIDE, RISE) at 3 years, the ATE rate was 10.4% (26 of 249) with 0.5 mg ranibizumab and 10.8% (27 of 250) with 0.3 mg ranibizumab; the stroke rate was 4.8% (12 of 249) with 0.5 mg ranibizumab and 2.0% (5 of 250) with 0.3 mg ranibizumab. Over 3 years in patients with DME, fatalities occurred in 6.4% (16 of 249) of patients treated with 0.5 mg ranibizumab and in 4.4% (11 of 250) of

patients treated with 0.3 mg ranibizumab. A potential relationship between these events and intravitreal use of VEGF inhibitors cannot be excluded.

### Future directions

Aflibercept is being tried for various indications (Table 1). A novel VEGF Decoy Receptor Fusion Protein Conbercept (Figure 1f) contains the immunoglobulin (Ig) domain 2 of VEGF receptor-1 fused to the Ig domain 3 and 4 of VEGF receptor-2 fused to the IgG1 Fc [77]. Like aflibercept it binds to all VEGF-A isoforms, VEGF-B and PlGF. It is a promising agent for treating wAMD, DME and macular edema following venous occlusion.

### Summary

Comparable results are coming with aflibercept in AMD, DME and macular edema from CRVO versus ranibizumab (Table 2). The dosage schedule is less frequent (i.e., 2monthly in Wet AMD) than ranibizumab. The single-dose cost of aflibercept (\$1850) is comparable to ranibizumab (\$1950), but still it is much more than bevacizumab (approximately \$50) [39]. Thus the cost with aflibercept may be half of ranibizumab courtesy its dosage schedule. Still both the therapies are much more costly than Bevacizumab. With accumulating long term safety and efficacy data, aflibercept seems to have the potential to compete with ranibizumab as first line anti-VEGF therapy of choice amongst the FDA approved group of drugs.

### References

- Congdon N, O'Colmain B, Klaver CC, Klein R, Muñoz B, Friedman DS, et al., Eye Diseases Prevalence Research Group. Causes and prevalence of visual impairment among adults in the United States. *Arch. Ophthalmol* 2004; 122: 477–485.
- Ferris FL 3rd, Fine SL, Hyman L. Age-related macular degeneration and blindness due to neovascular maculopathy. *Arch. Ophthalmol* 1984; 102: 1640–1642.
- Global data on visual impairments 2010 by WHO.
- FDA Approves New Drug Treatment for Age-Related Macular Degeneration. 2004
- Patz A. Retinal neovascularisation: early contributions of Professor Michaelson and recent observations. *Br. J. Ophthalmol* 1984; 68: 42–46.
- Senger DR, Galli SJ, Dvorak AM, Perruzzi CA, Harvey VS, Dvorak HF, et al., Tumor cells secrete a vascular permeability factor that promotes accumulation of ascites fluid. *Science*. 1983; 219: 983–985.
- Ferrara N, Henzel WJ. Pituitary follicular cells secrete a novel heparin-binding growth factor specific for vascular endothelial cells. *Biochem Biophys Res Commun*. 1989; 161: 851–858.
- Qazi Y, Maddula S, Ambati BK. Mediators of ocular angiogenesis. *J Genet*. 2009; 88: 495–515.
- Ferrara N, Gerber HP, LeCouter J. The biology of VEGF and its receptors. *Nat Med*. 2003; 9: 669–676.
- Xuri Li, Chunsik Lee, Zhongshu Tang, Fan Zhang, Pachiappan Arjunan, Yang Li, et al., VEGF-B. *Cell Adhes Migr*. 2009; 3: 322–327.
- Karkkainen MJ, Mäkinen T, Alitalo K. Lymphatic endothelium: a new frontier of metastasis research. *Nat Cell Biol*. 2002; 4: E2–5.
- Robinson CJ, Stringer SE. The splice variants of vascular endothelial growth factor (VEGF) and their receptors. *J Cell Sci*. 2001; 114: 853–865.
- Ferrara N. Vascular endothelial growth factor: basic science and clinical progress. *Endocr Rev*. 2004; 25: 581–611.
- Kaipainen A, Korhonen J, Mustonen T, van Hinsbergh VW, Fang GH, Dumont D, et al., Expression of the fms-like tyrosine kinase 4 gene becomes restricted to lymphatic endothelium during development. *Proc Natl Acad Sci U S A*. 1995; 92: 3566–3570.
- Dumont DJ, Jussila L, Taipale J, Lymboussaki A, Mustonen T, Pajusola K, et al., Cardiovascular failure in mouse embryos deficient in VEGF receptor-3. *Science*. 1998; 282: 946–949.
- Shalaby F, Rossant J, Yamaguchi TP, Gertsenstein M, Wu XF, Breitman ML, et al., Failure of blood-island formation and vasculogenesis in Flk-1-deficient mice. *Nature*. 1995; 376: 62–66.
- Senger DR, Connolly DT, Van de Water L, Feder J, Dvorak HF, et al., Purification and NH2-terminal amino acid sequence of guinea pig tumor-secreted vascular permeability factor. *Cancer Res*. 1990; 50: 1774–1778.
- Weis SM, Cheresh DA. Pathophysiological consequences of VEGF-induced vascular permeability. *Nature*. 2005; 437: 497–504.
- Ruckman J1, Green LS, Beeson J, Waugh S, Gillette WL, Henninger DD, et al., 2'-Fluoropyrimidine RNA-based aptamers to the 165-amino acid form of vascular endothelial growth factor (VEGF165). Inhibition of receptor binding and VEGF-induced vascular permeability through interactions requiring the exon 7-encoded domain. *J Biol Chem*. 1998; 273: 20556–20567.
- Drolet DW, Nelson J, Tucker CE, Zack PM, Nixon K, Bolin R, et al., Pharmacokinetics and safety of an anti-vascular endothelial growth factor aptamer (NX1838) following injection into the vitreous humor of rhesus monkeys. *Pharm Res*. 2000; 17: 1503–1510.
- Macugen AMD Study Group, Apte RS, Modi M, Masonson H, Patel M, Whitfield L, et al., Pegaptanib 1-year systemic safety results from a safety-pharmacokinetic trial in patients with neovascular age-related macular degeneration. *Ophthalmology*. 2007;114: 1702–1712.
- Comparing Anti-VEGF Therapies in Neovascular Age-Related Macular Degeneration.
- Klettner A, Roeder J. Comparison of Bevacizumab, Ranibizumab, and Pegaptanib In Vitro: Efficiency and Possible Additional Pathways. *Invest Ophthalmol Vis Sci*. 2008; 49: 4523–4527.
- Ferrara N, Damico L, Shams N, Lowman H, Kim R. Development of ranibizumab, an anti-vascular endothelial growth factor antigen binding fragment, as therapy for neovascular age-related macular degeneration. *Retina Phila Pa*. 2006; 26: 859–870.
- Gaudreault J, Fei D, Beyer JC, Ryan A, Rangell L, Shiu V, et al., Pharmacokinetics and retinal distribution of ranibizumab, a humanized antibody fragment directed against vegf-A, following intravitreal administration in rabbits: *Retina*. 2007; 27: 1260–1266.
- LUCENTIS® Ranibizumab Inject Inc Brief Book.
- Rosenfeld PJ, Brown DM, Heier JS, Boyer DS, Kaiser PK, Chung CY, et al., Ranibizumab for neovascular age-related macular degeneration. *N Engl J Med*. 2006; 355: 1419–1431.
- Brown DM, Kaiser PK, Michels M, Soubrane G, Heier JS, Kim RY, et al., Ranibizumab versus verteporfin for neovascular age-related macular degeneration. *N Engl J Med*. 2006; 355: 1432–1444.
- Comparison of Age-related Macular Degeneration Treatments Trials (CATT) Research Group, Martin DF, Maguire MG, Fine SL, Ying GS, Jaffe GJ, et al., Ranibizumab and bevacizumab for treatment of neovascular age-related macular degeneration: two-year results. *Ophthalmology*. 2012; 119: 1388–1398.
- Chakravarthy U, Harding SP, Rogers CA, Susan M Downes, Andrew J Lotery, Lucy A Culliford, et al., Alternative treatments to inhibit VEGF in age-related choroidal neovascularisation: 2-year findings of the IVAN randomised controlled trial. *Lancet*. 2013; 382: 1258–1267
- Michels S, Rosenfeld PJ, Puliafito CA, Marcus EN, Venkatraman AS. Systemic bevacizumab (Avastin) therapy for neovascular age-related macular degeneration twelve-week results of an uncontrolled open-label clinical study. *Ophthalmology*. 2005; 112: 1035–1047.
- Rosenfeld PJ, Puliafito CA, Michels S, Moshfeghi AA, Fung AE, Rosenberg KD, et al., Systemic Bevacizumab (Avastin(R)) Therapy for Neovascular

- Age-Related Macular Degeneration (SANA) Study: Visual Acuity Outcomes. *ARVO Meet Abstr.* 2005; 46: 2310.
33. Avastin (bevacizumab) Data Sheet (DS)
  34. Bakri SJ, Snyder MR, Reid JM, Pulido JS, Singh RJ. Pharmacokinetics of intravitreal bevacizumab (Avastin). *Ophthalmology.* 2007; 114: 855–859.
  35. Krohne TU, Eter N, Holz FG, Meyer CH. Intraocular pharmacokinetics of bevacizumab after a single intravitreal injection in humans. *Am J Ophthalmol.* 2008; 146: 508-512.
  36. Peter Heiduschka, Heike Fietz, Sabine Hofmeister, Sigrid Schultheiss, Mack F. Andreas, Swaantje Peters, et al., Penetration of bevacizumab through the retina after intravitreal injection in the monkey. *Invest Ophthalmol Vis Sci.* 2007; 48: 2814-2823.
  37. Jocelyn Holash, Sam Davis, Nick Papadopoulos, Susan D. Croll, Lillian Ho, Michelle Russell, et al., VEGF-Trap: a VEGF blocker with potent antitumor effects. *Proc Natl Acad Sci U S A.* 2002;99: 11393-11398.
  38. Yoshitsugu Saishin, Yumiko Saishin, Kyoichi Takahashi, Raquel Lima e Silva, Donna Hylton, John S. Rudge, et al., VEGF-TRAP(R1R2) suppresses choroidal neovascularization and VEGF-induced breakdown of the blood-retinal barrier. *J Cell Physiol.* 2003; 195: 241-248.
  39. Stewart MW. Aflibercept (VEGF Trap-eye): the newest anti-VEGF drug. *Br J Ophthalmol.* 2012; 96: 1157-1158.
  40. Chappelow AV, Kaiser PK. Neovascular age-related macular degeneration: potential therapies. *Drugs.* 2008; 68: 1029-1036.
  41. Assessment report of Aflibercept: European Medicines Agency
  42. Nork TM, Dubielzig RR, Christian BJ, Miller PE, Miller JM, Cao J, et al., Prevention of experimental choroidal neovascularization and resolution of active lesions by VEGF trap in nonhuman primates. *Arch Ophthalmol.* 2011; 129: 1042-1052.
  43. Ciombor KK, Berlin J, Chan E. Aflibercept. *Clin Cancer Res Off J Am Assoc Cancer Res.* 2013; 19: 1920-1925.
  44. De Groot JF, Lamborn KR, Chang SM, Gilbert MR, Cloughesy TF, Aldape K, et al., Phase II study of aflibercept in recurrent malignant glioma: a North American Brain Tumor Consortium study. *J Clin Oncol Off J Am Soc Clin Oncol.* 2011; 29: 2689-2695.
  45. Chau CH, Figg WD. Aflibercept in pediatric solid tumors: moving beyond the trap. *Clin Cancer Res Off J Am Assoc Cancer Res.* 2012; 18: 4868-4871.
  46. Coleman RL, Duska LR, Ramirez PT, Heymach JV, Kamat AA, Modesitt SC, et al., Phase 1-2 study of docetaxel plus aflibercept in patients with recurrent ovarian, primary peritoneal, or fallopian tube cancer. *Lancet Oncol.* 2011; 12: 1109-1117.
  47. Mackay HJ, Buckanovich RJ, Hirte H, Correa R, Hoskins P, Biagi J, et al., A phase II study single agent of aflibercept (VEGF Trap) in patients with recurrent or metastatic gynecologic carcinomas and uterine leiomyosarcoma. A trial of the Princess Margaret Hospital, Chicago and California Cancer Phase II Consortia. *Gynecol Oncol.* 2012; 125: 136-140.
  48. FDA approves Eylea for eye disorder in older people.
  49. Regeneron Announces FDA Approval of EYLEA® (aflibercept) Injection For Macular Edema Following Central Retinal Vein Occlusion.
  50. Heier JS, Brown DM, Chong V, Korobelnik JF, Kaiser PK, Nguyen QD, et al., Intravitreal aflibercept (VEGF trap-eye) in wet age-related macular degeneration. *Ophthalmology.* 2012; 119: 2537-2548.
  51. Heier JS, Boyer D, Nguyen QD, Marcus D, Roth DB, Yancopoulos G, et al., The 1-year results of CLEAR-IT 2, a phase 2 study of vascular endothelial growth factor trap-eye dosed as-needed after 12-week fixed dosing. *Ophthalmology.* 2011; 118: 1098-1106.
  52. Creuzot C. Intravitreal aflibercept (IVT-AFL) for macular edema secondary to CRVO: Results of COPERNICUS and GALILEO studies. *Acta Ophthalmol (Copenh).* 2013; 91: 0–0.
  53. Evoy KE, Abel SR. Aflibercept: newly approved for the treatment of macular edema following central retinal vein occlusion. *Ann Pharmacother.* 2013; 47: 819-827.
  54. Campochiaro PA, Heier JS, Feiner L, Gray S, Saroj N, Rundle AC, et al., Ranibizumab for macular edema following branch retinal vein occlusion: six-month primary end point results of a phase III study. *Ophthalmology.* 2010; 117: 1102-1112.e1.
  55. Brown DM, Campochiaro PA, Singh RP, Li Z, Gray S, Saroj N, et al., Ranibizumab for macular edema following central retinal vein occlusion: six-month primary end point results of a phase III study. *Ophthalmology.* 2010; 117: 1124-1133. e1.
  56. Regeneron and Bayer Report Positive Phase 3 Results for EYLEA® (aflibercept) Injection in Myopic Choroidal Neovascularization (mCNV).
  57. R. Silva on behalf of the MYRROR Steering Committee. Intravitreal aflibercept in patients with choroidal neovascularisation secondary to pathological myopia (myopic CNV): 48-week findings from the MYRROR study. In: *The 5 th World Congress on Controversies in Ophthalmology (COPHy).* Lisbon, Portugal. 2014.
  58. Tufail A, Patel PJ, Sivaprasad S, Amoaku W, Browning AC, Cole M, et al., Ranibizumab for the treatment of choroidal neovascularisation secondary to pathological myopia: interim analysis of the REPAIR study. *Eye Lond Engl.* 2013; 27: 709-715.
  59. Ruiz-Moreno JM, Arias L, Montero JA, Carneiro A, Silva R. Intravitreal anti-VEGF therapy for choroidal neovascularisation secondary to pathological myopia: 4-year outcome. *Br J Ophthalmol.* 2013; 97: 1447-1450.
  60. Franqueira N, Cachulo ML, Pires I, Fonseca P, Marques I, Figueira J, et al., Long-term follow-up of myopic choroidal neovascularization treated with ranibizumab. *Ophthalmol J Int Ophthalmol Int J Ophthalmol Z Für Augenheilkd.* 2012; 227: 39-44.
  61. Calvo-Gonzalez C, Reche-Frutos J, Donate J, Fernandez-Perez C, Garcia-Feijoo J. Intravitreal ranibizumab for myopic choroidal neovascularization: factors predictive of visual outcome and need for retreatment. *Am J Ophthalmol.* 2011; 151: 529-534.
  62. Wolf S, Balciuniene VJ, Laganovska G, Menchini U, Ohno-Matsui K, Sharma T, et al. RADIANCE: A Randomized Controlled Study of Ranibizumab in Patients with Choroidal Neovascularization Secondary to Pathologic Myopia. *Ophthalmology.* 2014; 121: 682-692.e2.
  63. Do DV, Nguyen QD, Boyer D, Schmidt-Erfurth U, Brown DM, Vittori R, et al., One-year outcomes of the DA VINCI Study of VEGF Trap-Eye in eyes with diabetic macular edema. *Ophthalmology.* 2012; 119: 1658-1665.
  64. Nguyen QD, Brown DM, Marcus DM, Boyer DS, Patel S, Feiner L, et al., Ranibizumab for diabetic macular edema: results from 2 phase III randomized trials: RISE and RIDE. *Ophthalmology.* 2012; 119: 789-801.
  65. Miura M, Iwasaki T, Goto H. Intravitreal aflibercept for polypoidal choroidal vasculopathy after developing ranibizumab tachyphylaxis. *Clin Ophthalmol Auckl NZ.* 2013; 7: 1591-1595.
  66. Semeraro F, Morescalchi F, Duse S, Parmeggiani F, Gambicorti E, Costagliola C. Aflibercept in wet AMD: specific role and optimal use. *Drug Des Devel Ther.* 2013; 7: 711-722.
  67. Deissler HL, Deissler H, Lang GK, Lang GE. Ranibizumab efficiently blocks migration but not proliferation induced by growth factor combinations including VEGF in retinal endothelial cells. *Graefes Arch Clin Exp Ophthalmol Albrecht Von Graefes Arch Für Klin Exp Ophthalmol.* 2013; 251: 2345-2353.
  68. Laura Kowalczyk, Elodie Touchard, Samy Omri, Laurent Jonet, Christophe Klein, Fatemeh Valamanes, et al., Placental growth factor contributes to micro-vascular abnormalization and blood-retinal barrier breakdown in diabetic retinopathy. *PLoS One.* 2011; 6: e17462.
  69. Luttj GA, McLeod DS, Bhutto I, Wiegand SJ. Effect of VEGF trap on normal retinal vascular development and oxygen-induced retinopathy in the dog. *Invest Ophthalmol Vis Sci.* 2011; 52: 4039-4047.
  70. Sven Schnichels, Ulrike Hagemann, Kai Januschowski, Johanna Hofmann, Karl-Ulrich Bartz-Schmidt, Peter Szurman, et al., Comparative toxicity and proliferation testing of aflibercept, bevacizumab and ranibizumab on different ocular cells. *Br J Ophthalmol.* 2013; 97: 917-923.



71. Stewart MW, Rosenfeld PJ. Predicted biological activity of intravitreal VEGF Trap. *Br J Ophthalmol*. 2008;92(5):667-668.
72. Papadopoulos N, Martin J, Ruan Q, Rafique A, Rosconi MP, Shi E, et al., Binding and neutralization of vascular endothelial growth factor (VEGF) and related ligands by VEGF Trap, ranibizumab and bevacizumab. *Angiogenesis*. 2012; 15: 171-185.
73. Chang J H, Garg NK, Lunde E, Han K-Y, Jain S, Azar DT. Corneal neovascularization: an anti-VEGF therapy review. *Surv Ophthalmol*. 2012; 57: 415-429.
74. Saito M, Kano M, Itagaki K, Oguchi Y, Sekiryu T. Retinal pigment epithelium tear after intravitreal aflibercept injection. *Clin Ophthalmol Auckl NZ*. 2013; 7: 1287-1289.
75. Mansour AM, Shahin M, Kofoed PK, Parodi MB, Shami M, Schwartz SG, et al., Insight into 144 patients with ocular vascular events during VEGF antagonist injections. *Clin Ophthalmol Auckl NZ*. 2012; 6: 343-363.
76. Feucht N, Schönbach EM, Lanzl I, Kotliar K, Lohmann CP, Maier M, et al., Changes in the foveal microstructure after intravitreal bevacizumab application in patients with retinal vascular disease. *Clin Ophthalmol Auckl NZ*. 2013; 7: 173-178.
77. Qin Wang, Tao Li, Zhigang Wu, Quan Wu, Xiao Ke, Delun Luo, et al. Novel VEGF Decoy Receptor Fusion Protein Conbercept Targeting Multiple VEGF Isoforms Provide Remarkable Anti-Angiogenesis Effect In Vivo. *PLoS ONE*. 2013; 8.