

Research Article

Transthoracic Echocardiographic Changes in Cryptogenic Perforating Artery Infarction Patients with Patent Foramen Ovale

Tang H^{1,2*}, Zhang H¹, Dong Y¹, Wu F¹, Yu C³, Dong Q^{1,4,5} and Cao W^{1,4,5}

¹Department of Neurology, Fudan University, China

²Department of Neurology and Institute of Neurology, Shanghai University of Traditional Chinese Medicine, China

³Department of Critical Care, Fudan University, China

⁴State Key Laboratory of Medical Neurobiology, Fudan University, China

⁵National Clinical Research Center for Aging and Medicine, Fudan University, China

*Corresponding author: Haiyan Tang, Department of Neurology, Huashan Hospital, Fudan University, No.12 Wulumuqi Zhong Rd. Shanghai, 200040, China

Received: May 02, 2020; Accepted: May 27, 2020;

Published: June 03, 2020

Abstract

Background: Patent Foramen Ovale (PFO) can also lead to Cryptogenic Perforating Artery Infarction (CPAI).

Purpose: To evaluate the association between transthoracic echocardiographic changes and PFO in patients with CPAI.

Material and Methods: From Jan 2015 to Jun 2018, patients diagnosed with cryptogenic PAI were retrospectively included in our study. All patients received Transthoracic Echocardiography (TTE) and Transcranial Doppler (TCD). PFO was diagnosed by the bubble test of TCD. Clinical characteristics and TTE findings between PFO group and non-PFO group were compared.

Results: Sixty-four patients were finally included. PFO was detected in 29.6% (19/64) of the patients. Higher percent of Vertebrobasilar Circulation Infarction (VCI) (47.4%) was seen in PFO than in non-PFO (17.8%) ($p=0.014$). In TTE findings, lower median Left Ventricular End-Diastolic diameter (LVEDd) (46mm, $p=0.016$) and lower median early diastolic peak velocity of the mitral annulus (Em) (57cm/s, $p=0.034$) were detected in PFO than non-PFO (50mm and 72cm/s, respectively). Thresholds of LVEDd and Em in predicting PFO were 47mm and 67cm/s (analyzed with ROC curve and Youden index). In multivariate analysis, $LVEDd < 47mm$, $Em < 67cm/s$ and VCI independently predicted PFO. Patients who had ≥ 1 of those three factors were associated with PFO with a sensitivity of 0.94 (95% CI 0.73~0.99) and a specificity of 0.4 (95% CI 0.25~0.55), ≥ 2 with a sensitivity of 0.52 (95% CI 0.28~0.75) and a specificity of 0.88 (95% CI 0.75~0.96).

Conclusion: Decreased LVEDd and Em are two independent TTE predictors associated with PFO in CPAI.

Keywords: Cryptogenic perforating artery infarction; Patent foramen ovale; Transthoracic echocardiographic

Introduction

Early evaluation of an ischemic stroke subtype is important because it affects treatment decisions and influences the short-term and long-term prognosis of stroke [1]. Cryptogenic stroke, which accounts for approximately 25% of cases, is an important group that deserves further research [2]. Patent Foramen Ovale (PFO) is considered to be one of the major causes of cryptogenic stroke. The precise mechanism of these PFO-related strokes remains uncertain, and paradoxical embolism is the leading hypothesis [3,4].

PFO-associated stroke is more frequently observed as a single cortical infarction or multiple small ischemic lesions in the vertebrobasilar circulation [5]. However, PFO can also lead to Cryptogenic Perforating Artery Infarction (CPAI). Subcortical single lesions larger than 15mm had previously been reported to be associated with cryptogenic stroke [6]. In our study, we aimed to evaluate the characteristics of PFO related CPAI, including the clinical, neuroimaging and Transthoracic Echocardiography (TTE) results.

Materials and Methods

Patients

We retrospectively reviewed patients who were suspected with acute CPAI by clinicians and underwent both bubble test of Transcranial Doppler (TCD) and TTE in our hospital from Jan 2015 to Jun 2018. Perforating Artery Infarctions (PAI) involved infarctions of lenticulostriate arteries, pontine perforators and thalamic perforators [7]. Patients suspected with CPAI must meet four criteria: 1. Had no evidence of large-artery atherosclerosis; 2. Had no evidence of cardioembolic origin; 3. Isolated acute infarction in the territories of perforating artery; 4. Had no other determined etiology of stroke. This study has been approved by the ethics committee of our institution.

Clinical and imaging data

Demographic characteristics, vascular risk factors (diabetes, hypertension, hyperlipidemia, smoking) and previous stroke history were documented. Ten-point Risk of Paradoxical Embolism (RoPE) score was calculated [8]. All patients underwent brain MRI, including the Diffusion-Weighted Image (DWI), and Apparent Diffusion-

Table 1: Clinical characteristics and TTE parameters of patients with or without PFO.

Variable	Total n=64	PFO n=19	Non-PFO n=45	P Value
Clinical characteristics				
Age (years)	46.5 (33,57)	47 (35,56)	46 (32,57)	0.854
Sex (male)	49 (76.6)	19 (84.9)	33 (73.3)	0.376
Height (cm)	170 (164.75,173)	168 (162,173)	170 (165, 173)	0.571
Weight (kg)	66.45 (60,73)	64 (60,72)	66.5 (60, 73)	0.945
Diabetes	7 (10.9)	2 (10.5)	5 (11.1)	1
Hypertension	25 (39.1)	9 (47.4)	16 (35.6)	0.376
Hyperlipidemia	7 (10.9)	2 (10.5)	5 (11.1)	1
Smoking	28 (43.8)	9 (47.4)	19 (42.2)	0.705
Previous stroke	11 (17.2)	4 (21.1)	7 (15.6)	0.719
RoPE score	5 (4,8)	6 (4,7)	5 (4,8)	0.858
VCI	17 (26.6)	9 (47.4)	8 (17.8)	0.014
TTE parameters				
ARd (mm)	32 (30,35)	32 (30,33)	32 (30,35)	0.712
LAAPd (mm)	35 (32,37)	35 (31,38)	35 (32,37)	0.929
LVEDd (mm)	49 (46,52)	46 (42,50)	50 (47,52)	0.016
LVESd (mm)	30 (27.25,32)	29 (25,32)	30 (28,32)	0.084
LVEF (%)	68.5 (64,72)	70 (63,73)	68 (64.5,71.5)	0.439
Em (cm/s)	68.5 (53,79)	57 (52,72)	72 (60,82)	0.439
Am (cm/s)	67.5 (52.25,77.75)	67 (52,79)	65 (50,77)	0.941

Values are presented as the number (percentage, %) or median (interquartile range) unless otherwise specified. TTE, Transthoracic Echocardiography; PFO, Patent Foramen Ovale; RoPE, Risk of Paradoxical Embolism; VCI, Vertebrobasilar Circulation Infarction; ARd, Aortic Root Diameter; LAAPd, Left Atrial Anteroposterior diameter; LVEDd, Left Ventricular End-Diastolic diameter; LVESd, Left Ventricular End-Systolic diameter; LVEF, Left Ventricular Ejection Fraction; Em, early diastolic peak velocity of the mitral annulus; Am, late diastolic peak velocity of the mitral annulus.

weighted image (ADC). MRI were retrospectively reviewed by using standard PACS software and assessed by a consultant neurologist and a senior stroke neurologist. PAI on DWI were classified as anterior circulation and posterior/Vertebrobasilar Circulation Infarctions (VCI). We excluded cortical infarctions or multiple infarctions and all patients included were with pure PAI.

Bubble test and TTE

PFO was diagnosed by the bubble test of TCD [9,10]. 9mL isotonic saline solution, 1mL of air, and 1 drop of the patient's blood were mixed through two 10mL syringes connected by a three-way stopcock. The mixture was rapidly injected into the forearm vein during normal respiration and during the maintenance stage of Valsalva maneuver. Right-to-Left Shunt (RLS) was quantified by counting the number of Microbubbles (MBs) within the first 3 cardiac cycles. According to the number of MBs, patients were divided into two groups: PFO group, 1 or more MBs; Non-PFO group, no MBs [11]. TTE were carried out for all the patients to record the echocardiography parameters. It

was also helping to exclude other reasons of RLS and other source of cardioembolism.

Statistical analysis

Statistical analyses were performed using SPSS, version 22 (SPSS Inc, Chicago, IL). P value less than 0.05 was considered to indicate statistical significance. Continuous variables were compared by Mann-Whitney U test and categorical variables were compared by Chi-square or Fisher's exact test between PFO and no-PFO groups. Multivariate regression (including variables with $p < 0.05$) was used to assess the association of variables with PFO. Receiver Operating Characteristic (ROC) analysis was performed to determine the optimal threshold of independent continuous variables in predicting PFO. Base on the previous results, a 3-point score, including 3 independent criteria, was tested by ROC for predicting PFO.

Results

A total of 64 patients were finally included. PFO was detected in 29.6% (19/64) of the patients. Between PFO-group and non-PFO group, no significant difference was found in baseline characteristics (age, sex, height and weight), risk factors for stroke and RoPE score between the two groups. All patients exhibited perforating artery ischemic lesions on DWI, and 26.6% were displayed in the posterior circulation. VCI were more common in PFO group (47.4%) than in non-PFO group (17.8%) ($p = 0.014$) (Table 1).

In comparison of TTE parameters, Aortic Root Diameter (ARd), Left Atrial Anteroposterior Diameter (LAAPd), Left Ventricular End-Systolic diameter (LVESd), Left Ventricular Ejection Fraction (LVEF) and late diastolic peak velocity of the mitral annulus (Am) showed no significant difference between the PFO group and the non-PFO group. However, PFO group was detected with a lower median Left Ventricular End-Diastolic diameter (LVEDd) (46mm, $p = 0.028$) and lower median early diastolic peak velocity of the mitral annulus (Em) (57cm/s, $p = 0.034$) than non-PFO group (50mm and 72cm/s, respectively) (Table 1).

In ROC analysis, lower LVEDd and Em predicted PFO with Area Under Curve (AUC) of 0.69 ($p = 0.017$) and 0.68 ($p = 0.022$) (Figure 1). Thresholds of LVEDd and Em in predicting PFO were 47mm and 67cm/s, tested by Youden index. In logistic regression analysis, LVEDd < 47 mm, Em < 67 cm/s and VCI independently associated with PFO (Table 2).

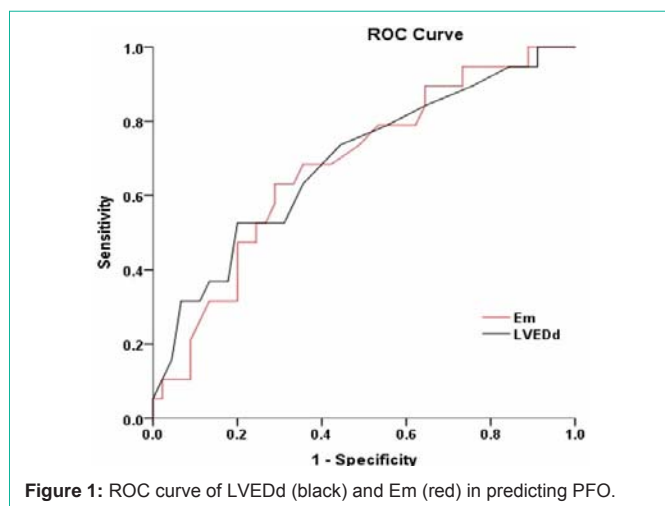
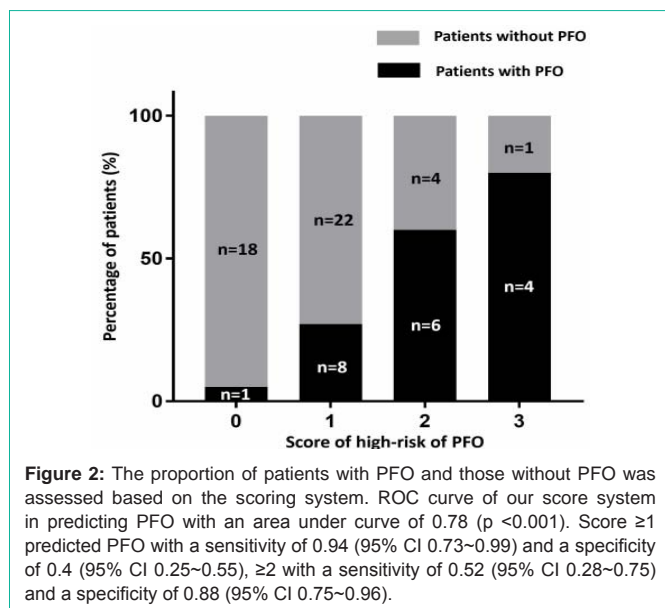
A scale derived to assess 3 independent criteria, including LVEDd < 47 mm, Em < 67 cm/s and VCI was used to score all the subjects (Table 3). Increased score predicted PFO with an AUC of 0.78 ($p < 0.001$). Score ≥ 1 predicted PFO with a sensitivity of 0.94 (95% CI 0.73~0.99) and a specificity of 0.4 (95% CI 0.25~0.55), ≥ 2 with a sensitivity of 0.52 (95% CI 0.28~0.75) and a specificity of 0.88 (95% CI 0.75~0.96) (Figure 2).

Table 2: Univariate and multivariate analysis of the predictors of PFO.

	Univariate		Multivariate	
	Odds ratio (95% CI)	P Value	Odds ratio (95% CI)	P Value
VCI	4.16 (1.27~13.56)	0.014	4.34 (1.12~16.79)	0.033
LVEDd < 47 mm	4.44 (1.39~14.17)	0.009	3.79 (1.08~13.35)	0.038
Em < 67 cm/s	3.92 (1.25~12.32)	0.016	4.62 (1.24~17.1)	0.022

Table 3: The 3-point score predicting system of PFO.

	Yes	No
VCI	1	0
LVEDd <47mm	1	0
Em <67cm/s	1	0
Total		

**Figure 1:** ROC curve of LVEDd (black) and Em (red) in predicting PFO.**Figure 2:** The proportion of patients with PFO and those without PFO was assessed based on the scoring system. ROC curve of our score system in predicting PFO with an area under curve of 0.78 ($p < 0.001$). Score ≥ 1 predicted PFO with a sensitivity of 0.94 (95% CI 0.73–0.99) and a specificity of 0.4 (95% CI 0.25–0.55), ≥ 2 with a sensitivity of 0.52 (95% CI 0.28–0.75) and a specificity of 0.88 (95% CI 0.75–0.96).

Discussion

PFO is an important cause of cryptogenic stroke, especially in the young patients. Generally, we used RoPE score for PFO screen in ischemic stroke patients, which was more suitable for the cortical ischemic strokes. However, in our clinical practice, we found a great part of PFO-stroke patients had only the subcortical perforating artery infarctions. For this type of patients, we would not always considered the screening approach to PFO diagnosis, such as the bubble test with high sensitivity, or the TEE been regarded as the gold standard for identifying a PFO [12]. While the brain MRI and non-contrast TTE

had been adopted as the routine examinations in the ischemic stroke patients. We expected to find some special clinical, neuroimaging or TTE characteristics in the PFO related perforating artery infarction.

In our study, the clinical characteristics showed no significant difference between the PFO group and the non-PFO group. The RoPE score of the two groups are also similar, indicating its inability to distinguish the real PFO positive patients from the perforating strokes. However, the neuroimaging presented some difference between the two groups. The ischemic lesions of PFO group preferred to distribute in the vertebrobasilar circulation. This was in accordance with the results of Kim workshop [10]. The exact mechanism of specific involvement of VB was still controversial. One hypothesis was postulated as the excess flow to the vertebrobasilar circulation after the Valsalva maneuver in patients with PFO. The more blood flow to the vertebrobasilar circulation, the more chances paradoxical embolism run into the pertinent territory. PFO is considered as a channel for the smaller embolus to travel from the venous system to cranial circulation [13]. The perforating artery infarctions in PFO patients can be explained by the embolization of smaller embolus.

From the echocardiography, lower LVEDd and lower Em were detected in the PFO group when compared with the non-PFO group, which were two parameters reflecting left ventricular diastolic function. Left ventricular diastolic dysfunction has been recognized as an important primary cause of heart failure [14]. The relationship between ventricular diastolic function and PFO remains unknown. A Germany team used E/e' ratio to divide normal LVED Pressure (LVEDP) or elevated LVEDP, and they found elevated LVEDP was negatively associated with PFO [15]. In our study, we found decreased LVEDd and Em, with thresholds of LVEDd <47mm and Em <67cm/s, independently predicted PFO. Thus, we develop a 3-point score system, including LVEDd <47mm, Em <67cm/s and VCI, which perform an excellent sensitivity (0.94) of score ≥ 1 and an excellent specificity (0.88) of score ≥ 2 in the prediction of PFO. We believe this score system is a simple and useful tool to screen PFO in CPAI patients before they receive further diagnostic examinations.

Our study limited by the retrospective nature of analysis and small number of patients from a single center. Some strong stroke-related risk factors, such as hypertension and smoking, were not rarely seen in our patients and our results could be impacted with selective bias. Secondly, PFO was only diagnosed by the bubble test of TCD, not TEE. Although TEE was considered to be the standard technique for identifying a PFO, some patients were intolerant of this method. Recently, a meta-analysis showed TCD to be more sensitive than TTE compared with TEE to detect PFO (96% vs 45%). TCD also possessed the advantages of noninvasive, inexpensive and easily repeatable [16]. We therefore preferred to choose the bubble test of TCD as our PFO diagnostic examinations.

In conclusion, decreased LVEDd and Em are TTE marks and VCI is the imaging mark, independently associated with PFO in CPAI. A simple score system including LVEDd <47mm, Em <67cm/s and VCI is useful to screen PFO in CPAI patients before they receive further diagnostic examinations.

References

- Meissner I, Whisnant JP, Khandheria BK, Spittell PC, O'Fallon WM and Pascoe RD, et al. Prevalence of Potential Risk Factors for Stroke Assessed

- by Transesophageal Echocardiography and Carotid Ultrasonography: The Sparc Study. *Stroke prevention: Assessment of risk in a community.* *Mayo Clin Proc.* 1999; 74: 862-869.
2. Hart RG, Diener HC, Coutts SB, Easton JD, Granger CB and O'Donnell MJ, et al. Embolic Strokes of Undetermined Source: The Case for a New Clinical Construct. *Lancet Neurol.* 2014; 13: 429-438.
 3. Overall JR, Bone I, Lees KR. Interatrial Septal Abnormalities and Stroke: A Meta-Analysis of Case-Control Studies. *Neurology.* 2000; 55: 1172-1179.
 4. Yasaka M, Otsubo R, O H and Minematsu K. Is stroke a Paradoxical Embolism in Patients with Patent Foramen Ovale? *Intern Med.* 2005; 44: 434-438.
 5. Kim BJ, Sohn H, Sun BJ, Song JK, Kang DW and Kim JS, et al. Imaging characteristics of ischemic strokes related to patent foramen ovale. *Stroke.* 2013; 44: 3350-3356.
 6. Altieri M, Metz RJ, Muller C, Maeder P, Meuli R and Bogousslavsky. Multiple brain infarcts: Clinical and neuroimaging patterns using diffusion-weighted magnetic resonance. *Eur Neurol.* 1999; 42: 76-82.
 7. Yang L, Cao W, Wu F, Ling Y, Cheng X and Dong Q. Predictors of clinical outcome in patients with acute perforating artery infarction. *J Neurol Sci.* 2016; 365: 108-113.
 8. Kent DM, Ruthazer R, Weimar C, Mas JL, Serena J and Homma Shunichi, et al. An index to identify stroke-related vs incidental patent foramen ovale in cryptogenic stroke. *Neurology.* 2013; 81: 619-625.
 9. Consoli D, Paciaroni M, Galati F, Aguggia M, Melis Maurizio and Malferrari G, et al. Prevalence of patent foramen ovale in ischaemic stroke in italy: Results of sisifo study. *Cerebrovasc Dis.* 2015; 39: 162-169.
 10. Komar M, Olszowska M, Przewlocki T, Podolec J, Stepniewski J and Sobieri B, et al. Transcranial doppler ultrasonography should it be the first choice for persistent foramen ovale screening? *Cardiovasc Ultrasound.* 2014; 12: 16.
 11. Blersch WK, Draganski BM, Holmer SR, Koch HJ, Schlachetzki F and Bogdahn U, et al. Transcranial duplex sonography in the detection of patent foramen ovale. *Radiology.* 2002; 225: 693-639.
 12. Mahmoud AN, Elgendy IY, Agarwal N, Tobis JM, Mojadidi MK. Identification and quantification of patent foramen ovale-mediated shunts: Echocardiography and transcranial doppler. *Interv Cardiol Clin.* 2017; 6: 495-504.
 13. Kim JW, Kim SJ, Yoon CW, Park CH, Kang KW and Kim SK, et al. Association between the amount of right-to-left shunt and infarct patterns in patients with cryptogenic embolic stroke: A transcranial doppler study. *Int J Stroke.* 2013; 8: 657-662.
 14. Kessler KM. Heart failure with normal systolic function. Update of prevalence, differential diagnosis, prognosis, and therapy. *Arch Intern Med.* 1988; 148: 2109-2111.
 15. Landeta F, Bussche Evd, Ritter M, Boentert K, Waltenberger J and Stypmann J. Elevated left ventricular end-diastolic pressure favours closure of foramen ovale. *Acta Cardiol.* 2012; 67: 701-706.
 16. Tsvigoulis G, Alexandrov AV and Sloan MA. Advances in transcranial doppler ultrasonography. *Curr Neurol Neurosci Rep.* 2009; 9: 46-54.