

Case Report

Ischemic Vascular Events as Clinical Manifestation of Protein C Deficiency

Honghong Li^{1,*}, Shuwei Qiu^{1,*}, Ying Peng¹¹Department of Neurology, Sun Yat-Sen Memorial Hospital, Sun Yat-Sen University, Guangzhou 510120, China

*H. Li and S. Qiu contributed equally to this work

***Corresponding author:** Ying Peng, M.D., Ph.D., Professor, Department of Neurology, Sun Yat-Sen Memorial Hospital, Sun Yat-Sen University, No. 107 West Yanjiang Road, Guangzhou, China, Tel: +86 20 8133 2620; Fax: +86 20 8133 2833; E-mail: 2353352460@qq.com**Received:** March 02, 2015; **Accepted:** March 31, 2015;**Published:** April 06, 2015**Abstract**

We report three patients who suffered from ischemic vascular events due to protein C deficiency to highlight the importance of evaluating protein C activity in young patients of recurrent vascular events without major risk factors. Protein C deficiency presenting with cerebral ischemic and cerebral venous sinus thrombosis has been only rarely observed. Anticoagulation therapy and/or fresh frozen plasma in the acute phase received good curative effect. These three cases indicate that the determination of protein C levels is valuable in the evaluation of patients with recurrent vascular events. Early diagnosis and treatment can prevent severe consequences.

Keywords: Protein C deficiency; Cerebral ischemia; Venous thrombosis; Anticoagulation; Fresh frozen plasma**Introduction**

Protein C (PC) is a vitamin K-dependent plasma glycoprotein that exerts a critical role in the regulation of coagulation [1-3]. PC is produced in hepatocytes and circulates in a very low concentration. It can be activated on the endothelial cells by thrombin binding to the membrane protein thrombomodulin. Once activated, PC acts as an anticoagulant via inactivating the procoagulation factors, factors V (FV) and VIII (FVIII). Protein S, which is also a vitamin K-dependent plasma protein, augments the activity of PC during the anticoagulation.

PC deficiency is inherited as an autosomal dominant disorder with a morbidity of 0.02-0.5% [4], and is identified when the PC concentration or activity is below 60-70% of the overall mean concentration or activity [5]. Patients with mild PC deficiency have an increased risk of venous thrombosis because of the imbalance between procoagulant and anticoagulant pathways. Severe PC deficiency is associated with neonatal purpura fulminans [6]. PC deficiency in the young patients usually manifest as venous thrombotic complications, including superficial thrombophlebitis, deep venous thrombosis, and pulmonary embolism. There have been few reports of PC deficiency presenting with ischemic stroke.

We report three cases who suffered from recurrent vascular ischemic events due to PC deficiency to highlight the importance of evaluating PC activity in young patients and to stress the importance of early diagnosis and timely treatment of this condition to prevent severe complications.

Case Presentation**Patient 1**

A man was admitted to our department with a sudden onset of left-sided hemiparesis. There were recurrent epileptic seizures of his left side limbs before admission. In 2006, the patient experienced deep vein thrombosis in his lower limbs. He developed a mesenteric venous thrombosis, and portal venous thrombosis. He had been

healthy until when he developed deep vein thrombosis. The patient had neither hypertension nor diabetes, and there were no obvious precipitants of thrombosis. He also denied the habits of smoking or drinking. The family history about vascular events of the patient was unremarkable.

The results of the general physical examination were normal. Neurological examination showed slightly hypoesthesia of the left limbs and trunk. He had Medical Research Council grade 4/5 muscle power over the left limbs. Laboratory tests including routine blood parameters, blood biochemistry, hyperhomocysteinemia, platelet count, platelet aggregation, prothrombin and partial thromboplastin times, factor VIII, antithrombin III activity, and protein S were all within normal limits. Fibrinogen and antithrombin III concentrations were slightly lower than the normal value. Other possible causes of stroke in the young including: serum electrolytes, renal and liver function, erythrocyte sedimentation rate were normal. The patient was negative for syphilis and hepatitis. However, the protein C functional activity of the patient's plasma was only 23.1% (normal, 70-140%). The cerebrospinal fluid (CSF) opening pressure was 190 mm H₂O without any other abnormality. Cardiologic investigations including electrocardiography, Holter electrocardiographic monitoring, and two-dimensional echocardiography did not suggest any abnormality. Double carotid chromatic ultrasonic (DCCU) did not show arteriosclerotic lesions in bilateral carotid. Brain magnetic resonance imaging (MRI) showed a prominent subacute cerebral infarction of the right side of the frontal lobes (Figure 1).

According to laboratory and imageological findings and the lack of other precipitating factors, the diagnosis of the patient was ischemic stroke due to PC deficiency. We treated the patient with long-term anticoagulation with 3mg/day warfarin following initial anticoagulation with 25,000 units /day low molecular weight heparin. When anticoagulation was achieved with warfarin, as show by PT, the low molecular weight heparin was discontinued. There was no complication, particularly no coumarin necrosis. The patient's hemiparesis was gradually improved during the following months. He

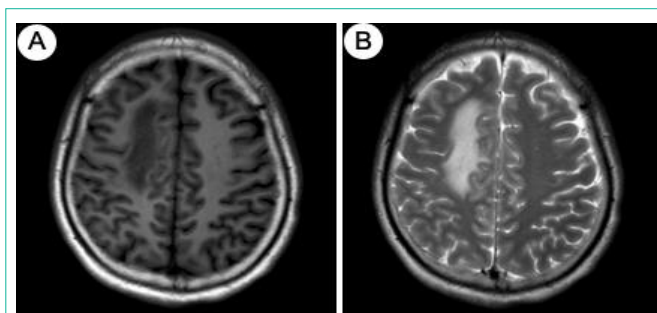


Figure 1: Picture A is T1-weight images and picture B is T2-weight images, which showing the cerebral infarction on the right side of the frontal lobes at the time of onset.

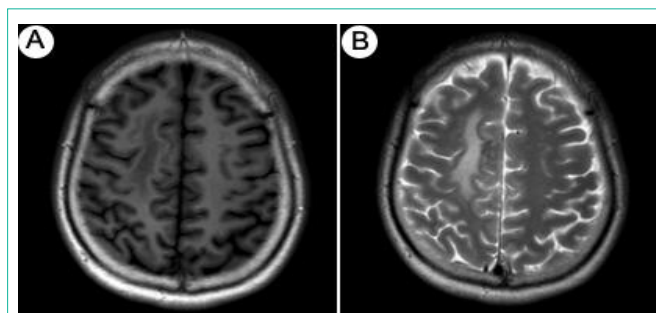


Figure 2: Picture A is T1-weight images and picture B is T2-weight Images. The second evaluation of MRI showing the volume of cerebral infarction narrowed after therapy one month later.

has been in good condition since the warfarin treatment and followed up with weekly reports of PT, APTT and INR. After one month, he remained asymptomatic with improved brain MRI (Figure 2).

Patient 2

A man was admitted to our department with repeated painful swelling of his lower limbs for 10 years. He had neither hypertension nor diabetes, and there were no obvious precipitants of thrombosis. He also denied the habits of smoking or drinking. The family history about vascular events of the patient was unremarkable. Laboratory tests including routine blood parameters, blood biochemistry, hyperhomocysteinemia, platelet count, platelet aggregation, prothrombin and partial thromboplastin times, factor VIII, antithrombin III activity, fibrinogen and antithrombin III concentrations, and protein S were all within normal limits. The patient was negative for syphilis and hepatitis. However, the protein C functional activity of the patient's plasma was only 8.2%. Vascular Ultrasound showed deep venous thrombosis in low limbs. After the diagnosis of protein C deficiency, he received anticoagulation treatment with warfarin. But the clinical manifestation didn't relieved. So we treated the patient with 2 u/day fresh frozen plasma for two days. Then the painful swelling of his lower limbs received great alleviation. He has been followed up with weekly reports of PT, APTT and INR. He has been in good condition during the following months.

Patient 3

This case was a 33-year-old woman with repeated weakness of her right lower limb for 7 years since her first pregnancy. No evident risk factors were present. Brain magnetic resonance venography (MRV) showed thrombogenesis in left transverse sinus and sigmoid sinus. Laboratory tests including routine blood parameters, blood biochemistry, hyperhomocysteinemia, platelet count, platelet aggregation, prothrombin and partial thromboplastin times, factor VIII, antithrombin III activity, fibrinogen and antithrombin III concentrations, and protein S were all within normal limits. However, the PC functional activity of the patient's plasma was only 12.2%. After the diagnosis of PC deficiency, low-molecular-weight heparin of 25,000 units/day for 7 days and then warfarin of 3mg/day was administered to the patient. She has been in good condition during the following months.

Discussion

The PC system is a natural profibrinolytic system consisting of

PC, protein S and thrombomodulin (which is a surface protein of endothelial cells) [7]. PC exhibits its anticoagulant effect through regulating the activities of FVIIIa and FVa. PC deficiency has two subtypes, type I and type II [8,9]. Type I is more common than type II, in which both the concentration and functional activity of PC are equally reduced. Type II deficiency with low PC activity but normal PC concentration. PC deficient patients have a decreased capacity to down-regulate the procoagulation of thrombin generated by FVa and FVIIIa, which may lead to recurrent attacks of thromboembolisms. The prevention of recurrent thrombosis is critical. Medical treatment of this condition includes administration of heparin, warfarin, fresh frozen plasma, and PC replacement.

Although there are many important diagnostic laboratory and imaging technologies, the cause and risk factors for young adult stroke are often rare or undetermined [10].

Most stroke cases do not require evaluation of coagulation, but hypercoagulability is a significant reason of unexplained strokes. A study of young Indians revealed that PC deficiency alone or in combination with PS deficiency is significantly associated with ischemic stroke in young adults [11,12]. However, the impact of PC deficiency on recurrence risk is less well defined and needs to be further investigated [13].

Our first patient experienced deep vein thrombosis of low limbs, mesenteric venous thrombosis, and portal venous thrombosis before the acute ischemic stroke. The possible etiology is hypercoagulable state. Treatment with heparin and long-term warfarin was gratifying. Because of our ignorance of PC deficiency in the first vascular events, the patient suffered from recurrent thrombosis. The second patient has been misdiagnosed for 10 years, and anticoagulation didn't receive perfect ending. In addition, during the acute phase, the clinical manifestation significantly alleviated after we treated the patient with fresh frozen plasma. The third patient suffered from cerebral venous sinus thrombosis for 7 years, and anticoagulation received good effect.

Conclusion

It is important to detect PC deficiency with previous VTE, because such patients have 8 to 10 fold increased risk of next incident of VTE [14]. This case documents that PC deficiency is a cause of vascular ischemic events, and early diagnosis and targeted therapeutic management are gratifying. Although PC deficiency is uncommon, any patient presenting with stroke or recurrent venous thrombosis

in young age should be suspected of PC deficiency and evaluated further. Systematic investigation of such causes of cerebral ischemia will lead to gratifying treatment in these undetermined strokes and recurrent vascular events. In conclusion, it is important to recognize PC deficiency as a significant risk factor in young patients with vascular ischemic events who have no major risk factors.

Acknowledgment

This work was supported by the sub-program of “12-5” National Science & Technique Support Program of China (2011BAI08B11 to YP) and NSFC (No. 81272197 to YP).

References

1. Dahlback B, Villoutreix BO. Regulation of blood coagulation by the protein C anticoagulant pathway: novel insights into structure-function relationships and molecular recognition. *Arterioscler Thromb Vasc Biol* 2005; 25: 1311-1320.
2. Esmon CT. The protein C pathway. *Chest*. 2003; 124: 26S-32S.
3. Esmon C. The protein C pathway. *Crit Care Med*. 2000; 28: S44-48.
4. Dahlbäck B. The protein C anticoagulant system: inherited defects as basis for venous thrombosis. *Thromb Res*. 1995; 77: 1-43.
5. Goldenberg NA, Manco-Johnson MJ. Protein C deficiency. *Haemophilia*. 2008; 14: 1214-1221.
6. Mosnier LO, Zlokovic BV, Griffin JH. The cytoprotective protein C pathway. *Blood*. 2007; 109: 3161-3172.
7. Briffa NP, Wilson I, Clarke DB. Surgical treatment of pulmonary hypertension in protein C deficiency. *Br Heart J*. 1991; 66: 460-462.
8. Bertina RM. Protein C deficiency and venous thrombosis--the search for the second genetic defect. *Thromb Haemost*. 2000; 83: 360-361.
9. Strickland DK, Kessler CM. Biochemical and functional properties of protein C and protein S. *Clin Chim Acta*. 1987; 170: 1-23.
10. Sultan S, Elkind MS. The growing problem of stroke among young adults. *Curr Cardiol Rep*. 2013; 15: 421.
11. Chatterjee T, Gupta N, Choudhry VP, Behari M, Saxena R, Ashraf MZ. Prediction of ischemic stroke in young Indians: is thrombophilia profiling a way out? *Blood Coagul Fibrinolysis*. 2013; 24: 449-453.
12. Folsom AR, Ohira T, Yamagishi K, Cushman M. Low protein C and incidence of ischemic stroke and coronary heart disease: the Atherosclerosis Risk in Communities (ARIC) Study. *J Thromb Haemost*. 2009; 7: 1774-1778.
13. Kenet G, Lütkehoff LK, Albisetti M, Bernard T, Bonduel M, Brandao L, et al. Impact of thrombophilia on risk of arterial ischemic stroke or cerebral sinovenous thrombosis in neonates and children: a systematic review and meta-analysis of observational studies. *Circulation*. 2010; 121: 1838-1847.
14. Barczyk A, Pierzchała W. [Risk factors of venous thromboembolism]. *Wiad Lek*. 2001; 54: 311-324.