

## Clinical Image

# B Aortic Dissection with Aberrant Right Subclavian Artery

Lu X<sup>1</sup>, Liu Y<sup>1</sup>, Cao D<sup>1</sup> and Sun Y<sup>2\*</sup><sup>1</sup>Department of Radiology, The First Hospital of Jilin University, Chang Chun, China<sup>2</sup>Pharmaceutical Department, China-Japan Union Hospital of Jilin University, Changchun, China**\*Corresponding author:** Yutian Sun, Pharmaceutical Department, China-Japan Union Hospital of Jilin University, Changchun 130033, China**Received:** July 03, 2018; **Accepted:** July 12, 2018;**Published:** July 19, 2018

## Keywords

AD: Aortic Dissection; Aberrant Right Subclavian Artery; Hybrid Procedure

## Clinical Image

CT angiography a 61-year-old woman with a 20-year history of hypertension was admitted to our hospital with sudden-onset chest pain and back pain. Physical examination revealed a blood pressure of 220/130mmHg in both arms. CT angiography confirmed typical B Aortic Dissection (AD) with the entry site suited at the origin of aberrant right Subclavian Artery (SA) (Figure 1a-b). After failure of systemic medication, AD was treated by transluminal implantation of endovascular stent covering the entry site of the dissection at the aberrant right SA orifice and chimney graft preserving the blood flow

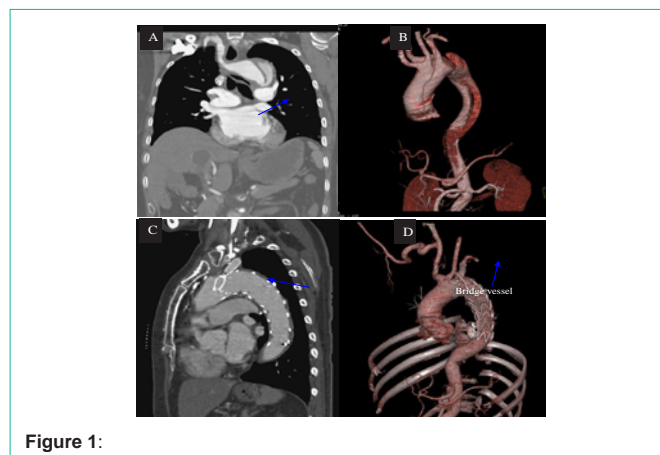


Figure 1:

to left SA. Prior to the endovascular procedure, a transposition of the aberrant SA to the right carotid artery was performed through a supraclavicular approach. The patient remains asymptomatic on the postoperative follow-up of 1 year (Figure 1c-d). Hybrid repair of B AD with lusorian artery appears to be a feasible, safe, and less invasive alternative to conventional surgery.