

Case Report

Squamous Cell Carcinoma of the Colon: A Case Report and Literature Review

Lannaz S*, Elomrani F, ouziane I, Mrabti H and Errihani H

Department of Medical Oncology, National Institute of Oncology, Morocco

*Corresponding author: Lannaz S, Department of Medical Oncology, National Institute of Oncology, Morocco

Received: June 06, 2015; Accepted: July 08, 2015;

Published: July 11, 2015

Abstract

The majority of colorectal cancers are adenocarcinoma. Primary squamous cell carcinoma of the colon is a rare tumour, only 53 cases have been published in literature. In this paper, we report a case of a 55-year-old man with squamous cell carcinoma of the colon treated by surgery and adjuvant chemotherapy with a good evolution.

We discuss the aetiopathogenic and the therapeutic management of this rare entity.

Keywords: Squamous Cell Carcinoma; Caecum; Capsule Endoscopy; Surgery; Chemotherapy

Introduction

The Squamous Cell Carcinoma (SCC) of the colon is a very rare tumour its histogenesis and its evolutionary potential still raise questions. We don't have enough information about the risk factors, prognosis and treatment of this cancer. Here, we report a case of SCC of the colon treated successfully with surgical resection and adjuvant chemotherapy.

Observation

A 55 years old man presented in May 2013 with rectal bleeding, weight loss and an anemic syndrome. The patient had no prior cancer history or a family history of colonic malignancy. Physical examination was unremarkable. Capsule endoscopy showed a tumour in the caecum with ulceration and stenosis (Figure 1). The biopsy of this mass revealed differentiated SCC (CK5/6+++ and CK20+). The MRI enterography showed a significant circumferential thickening of the cecal wall extended to the last ileal loop with a lymph node. CT scan of the chest, abdomen and pelvis were negative for distant metastasis. After multidisciplinary discussion, the patient underwent a right hemicolectomy; the postoperative histopathological findings were in accordance with the diagnosis of well differentiated SCC (Figure 2). The margins of the excised tissue were cancer-free with two metastatic lymph nodes. It was classified, according to the TNM classification, as pT3N1. The patient received eight cycles of adjuvant chemotherapy with capecitabine 1000 mg/m² orally twice daily for 14 days and oxaliplatin 130 mg/m² with a good evolution. Currently the patient is under regular control and he is in a good health, with 12 months of follow up.

Discussion

Colorectal SCC is extremely rare, representing less than 0.05% of all colorectal tumours, with an estimated incidence of 0.1 % [1,2]. The first case of SCC of the colon was reported in 1919 by Schmidtmann [3], and our case represents the 55 in the literature summarizes some of the reported cases. SCC occurs on average around the fifth decade with a male predominance (sex ratio: 2) [1,4,5]. The most common site of the tumour is the caecum and the right colon [4-6], much more

rarely at the left colon. The aetiopathogenicity of SCC of the colon is still unclear. Several hypotheses have been proposed; a multipotent stem cell [8] or chronic irritation (radiation exposure) can cause squamous metaplasia and subsequent tumour development [7]. In favor to the chronic irritation is the frequent association between SCC Colorectal and chronic inflammatory colitis, especially ulcerative colitis. The incidence of this association is 1.7% while it is only 0.25 to 0.5 % in the general population [2]. Parasitic colitis such as amoebiasis or schistosomiasis and chronic fistulas could be the cause of squamous metaplasia [1,4,9]. There is no ethnic predilection for this tumour. The association seen between SCC of the rectum and human papilloma virus has not been established [10]. The symptoms of the patients with SCC of the colon are similar to those with adenocarcinoma [11], with a diagnostic delay between six weeks and 12 months [1]. SCC of the colon can be revealed by distant metastasis; they can be liver, lung or bone metastasis [6,11,12]. Williams et al. have proposed reasonable criteria to diagnosis a colorectal SCC [13] absence of extension of the tumour from the anal squamous epithelium; absence of evidence of squamous cell carcinoma of any other primary site; absence of squamous-lined fistula tract to the affected bowel; confirmation of SCC by histological examination (without glandular differentiation). Colonoscopy and CT-scan and MRI provide essential information on

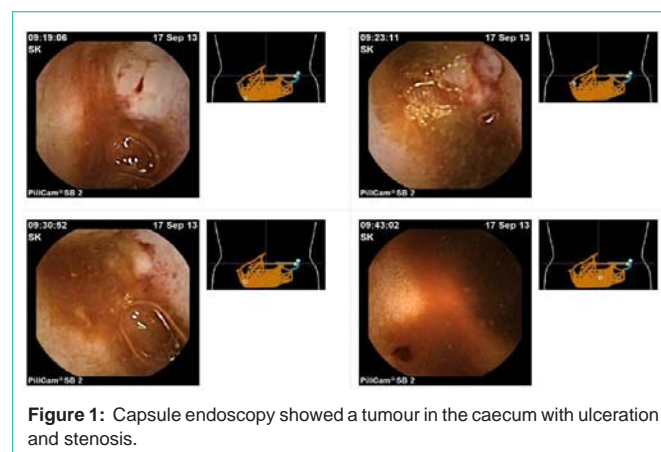


Figure 1: Capsule endoscopy showed a tumour in the caecum with ulceration and stenosis.

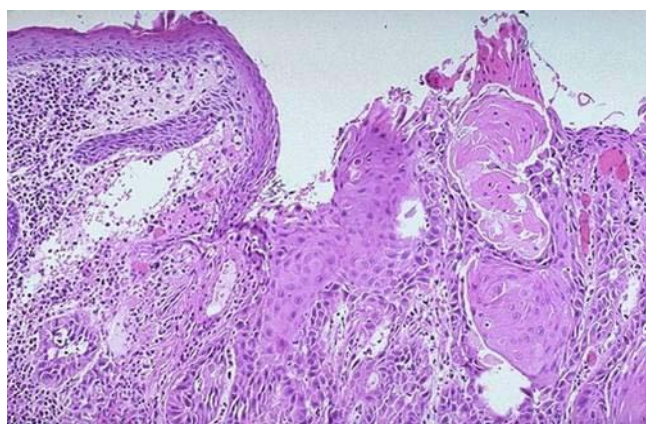


Figure 2: the postoperative histopathological findings were in accordance with the diagnosis of well differentiated SCC.

therapeutic approach. Surgery is the gold standard to treat colorectal SCC, respecting the principles of colic cancer surgery. We have no standard for adjuvant treatment. The effectiveness of chemotherapy is unknown given the rarity of this kind of tumour. We decide to treat our patient such as an adenocarcinoma, he received a combination of capecitabine and oxaliplatin for eight cycles. The prognosis of colic SCC is worse than the one for adenocarcinoma. According to the literature review conducted by Comer et al., Of the 44 cases reported between 1927 and 1987, the five-year survival is 32% [14] with a death before the first year in 52% of cases. The main factors of poor prognosis are the right location of the tumour, the character ulcerated lymph node involvement and TNM stage 4 [6].

Conclusion

The primitive colorectal SCC is an exceptional tumour, with unclear pathogenesis. The prognosis is more reserved than adenocarcinoma. Surgery is the gold standard to treat colorectal SCC, there is no standard for adjuvant treatment.

References

1. Michael P. Vezeridis, Lemuel O. Herrera, Gloria E. Lopez, Elihu J. Ledesma, Arnold Mittleman. Squamous-cell carcinoma of the colon and rectum. *Dis Colon Rectum*. 1983; 26:188-191.
2. Michelassi F, Montag AG, Block GE. Adenosquamouscell carcinoma in ulcerative colitis. Report of a case. *Dis Colon Rectum*. 1988; 31: 323-326.
3. Schmidtman M. Zur Kenntnis seltener Krebsformen. *Virchows Arch*. 1919; 226: 100-118.
4. Michelassi F, Mishlove LA, Stipa F, Block GE. Squamouscell carcinoma of the colon. Experience at the University of Chicago, review of the literature, report of two cases. *Dis Colon Rectum*. 1988; 31: 228-235.
5. Chulia F, Camps C, Rodriguez A, Rodriguez A, Medina E, Tuset Jet. Epidermoid carcinoma of the colon. Description of a lesion located in the hepatic flexure. *Dis Colon Rectum*. 1986; 29: 665-667.
6. Pittella JE, Torres AV. Primary squamous-cell carcinoma of the cecum and ascending colon: report of a case and review of the literature. *Dis Colon Rectum*. 1982; 25: 483-487.
7. Ouban A, Nawab RA, Coppola D. Diagnostic and pathogenetic implications of colorectal carcinomas with multidirectional differentiation: a report of 4 cases. *Clin Colorectal Cancer*. 2002; 1: 243-248.
8. Palvio DH, Sørensen FB, Mogensen KM. Stem cell carcinoma of the colon and rectum. Report of two cases and review of the literature. *Dis Colon Rectum*. 1985; 28: 440-445.
9. Lyttle JA. Primary squamous carcinoma of the proximal large bowel. Report of a case and review of the literature. *Dis Colon Rectum*. 1983; 26: 279-282.
10. Audeau A, Han HW, Johnston MJ, Whitehead MW, Frizelle FA. Does human papilloma virus have a role in squamous cell carcinoma of the colon and upper rectum? *Eur J Surg Oncol*. 2002; 28: 657-660.
11. Frizelle FA, Hobday KS, Batts KP, Nelson H. Adenosquamous and squamous carcinoma of the colon and upper rectum: a clinical and histopathologic study. *Dis Colon Rectum*. 2001; 44: 341-346.
12. Petrelli NJ, Valle AA, Weber TK, Rodriguez-Bigas M. Adenosquamous carcinoma of the colon and rectum. *Dis Colon Rectum*. 1996; 39: 1265-1268.
13. Williams GT, Blackshaw AJ, Morson BC. Squamous carcinoma of the colorectum and its genesis. *J Pathol*. 1979; 129: 139-147.
14. Dyson T, Draganov PV. Squamous cell cancer of the rectum. *World J Gastroenterol*. 2009; 15: 4380-4386.