

Case Report

Acute Coronary Syndrome Combined with Aortic Dissection Type A

Simoglou C^{1*} and Bertus I²¹Cardiothoracic Department Hippocratio General Hospital Athens, Greece²Department of Cardiothoracic Surgery, University of Bristol, School of Medicine, UK***Corresponding author:** Christos Simoglou, Cardiothoracic Department Hippocratio General Hospital Athens, Greece**Received:** September 05, 2022; **Accepted:** October 06, 2022; **Published:** October 13, 2022**Abstract**

We are presenting a case of Stanford Type a aortic dissection in a 58 year old male patient with history hypertension. He arrived at Emergency Department (ED) with diagnosis acute coronary syndrome a few hours after he developed sudden, severe worsening of his epigastric pain. Interesting case where the separation starts from the orifice of the right coronary artery, occupies the aortic valve.

Keywords: Stanford A; Aneurysm; Cardiothoracic diseases; Marfan's syndrome; De Bakey classification

Introduction

Aortic dissection is one of the acute aortic syndromes and a type of arterial dissection. It occurs when blood enters the medial layer of the aortic wall through a tear or penetrating ulcer in the intima and tracks along the media, forming a second blood-filled channel within the wall [1]. Thoracic dissection is commonly divided according to the Stanford classification into type A (involving the descending thoracic aorta only) and type B (involving the descending thoracic aorta only). The main cause of dissection are hypertension, atherosclerosis, Marfan's syndrome, Ehlers-Danlos syndrome, vasculitis, pregnancy and iatrogenic (aortic catheterization). The separation of the layers of the aortic wall produces a false channel, which spirals throughout a portion or commonly, the entire length of the aorta. In the United States, the prevalence of aortic dissection ranges from 0.2 to 0.8 per 100,000 per year or roughly 2,000 to 3,000 new cases per year [2].

Complications

Complications of aortic dissection include dissection and occlusion of branch vessels, distal thromboembolism, aneurismal dilatation and aortic rupture. Type A dissection may also result in coronary artery occlusion, aortic regurgitation and pericardial tamponade and therefore management of this type of dissection is usually emergency surgical repair. Type B dissections are usually managed with aggressive blood pressure control unless there are complications. An acute aortic dissection usually causes a severe sharp, tearing pain in the chest and upper back. In certain patients, the pain may develop or concentrate in the abdomen. In a very small number of patients, they may have little to no symptoms or flu-like symptoms (Figure 1). The weakening of the aortic wall can lead to aortic rupture within minutes or hours of the acute event [3]. The presence of the false channel in the ascending aorta can result in regurgitation of the aortic valve and myocardial infarction (heart attack). If the disturbance of aortic valve is significant this can lead to sudden symptoms of heart failure secondary to severe aortic valve regurgitation [4].

Case Presentation

The patient is a 58 year old male with a past medical history

of hypertension. He arrived at Emergency Department (ED) with diagnosis acute coronary syndrome a few hours after he developed sudden, severe worsening of his epigastric pain. The pain was stabbing, radiating to the back and was associated with nausea and profuse sweating. Shortly after to the (ED), he complained of pain extending to his chest [5]. On physical examination his blood pressure was 160/80 MmHg and pulse 98 beats per minute. He had tenderness to, especially in the epigastrium with associated guarding. The chest, lung, and cardiac exams were reported as normal, the remainder of the physical examination was unremarkable. Lab results were all within normal limits. Electrocardiogram showed sinus tachycardia with acute ischemic changes [6]. A chest CT verified the origin of the dissection at the aortic root. Image aortic dissection, Type A which extends from the origin of the aortic root, separating the right-hand valsava mouth of bay and the threefold aortic valve, where the separation at this stage reaches the abdominal aorta (at the level below about 2cm of neurite renal arteries). Expands the origin of the right artery anonymous and origin of the left subclavian artery. Possible extension of the separation in the left medial arteria carotids (Figure 2,3).

Also marked aneurismal dilatation of the aortic root and mild dilatation of the aortic arch. The patient was started on intravenous Esmolol and nitroprusside. Immediately after the patient was transferred to Aortography. The cardiothoracic surgery team was consulted and the patient was taken to the operating room emergently.

The diagnosis of a Type A aortic dissection is primarily based on clinical symptoms and radiographic imaging studies. The chest x-ray may provide the first suggestion of thoracic aortic pathology. The x-ray may show a pronounced heart shadow or silhouette indicating possible aortic aneurysm or aortic rupture. Obviously, the chest x-ray may tell the physician that another medical condition is causing the symptoms. An excellent study to diagnose an aortic dissection and is accessible in most emergency departments is a CT scan (or CT angiogram) MRI/A is also an excellent radiographic study, however, it is less accessible, more time consuming, and less patient-friendly. A Transesophageal Echocardiogram (TEE) is a very good study to diagnosis an aortic dissection, but it requires local and iv anesthesia AND is also less accessible and patient-friendly [7].

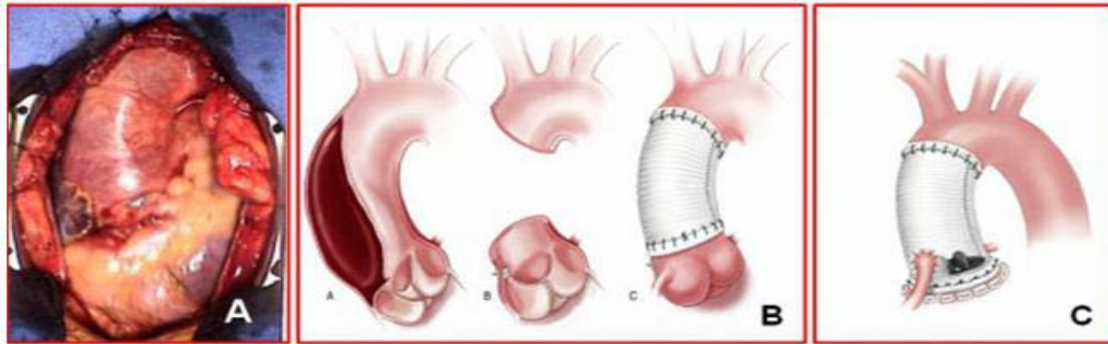


Figure 1: A) Type A aortic dissection B) Illustration of ascending aortic replacement and aortic valve repair (re-suspension) C) Bentall procedure-ascending and aortic root replacement and aortic valve replacement.

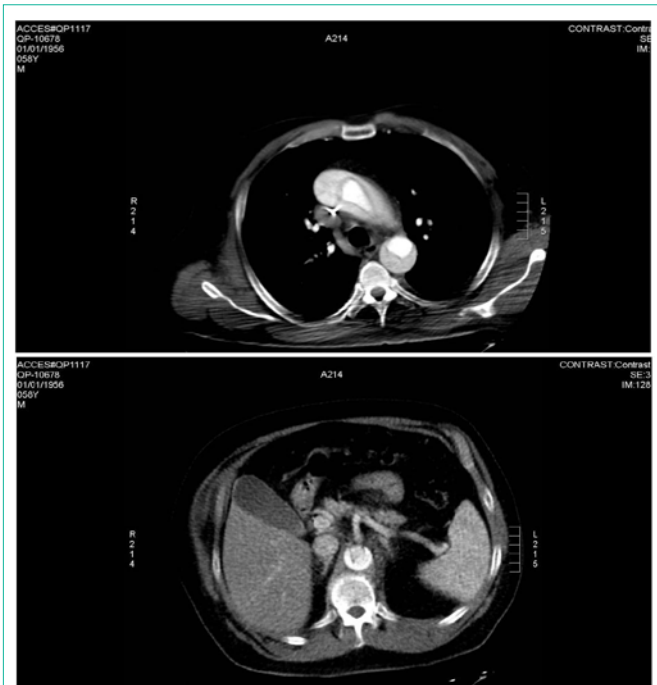


Figure 2: CT scans done on admission day. Notice the aortic intimal flap in ascending aorta, descending thoracic aorta.

A blood test that may increase the suspicion of an acute aortic dissection is D-dimer. However, D-dimer is elevated in other medical conditions. Some studies have suggested that if the D-dimer is above a certain level the likelihood of an aortic dissection is greater than 90% especially if the test is performed within 6 hours of onset of symptoms. As the time interval increases to 24 hours the sensitive and specificity diminishes significantly. At this point, D-dimer can be used to stratify patients with symptoms suggestive of acute dissection to further imaging studies or continued observation [8].

Discussion

Once the acute dissection occurs, the mortality increases 1% per hour until patient has aortic repair. Most patients that develop a Type A aortic dissection have a history of elevated blood pressure, an ascending aortic aneurysm, connective tissue disorder, bicuspid aortic valve, or have endured a stressful/emotional life event. Based

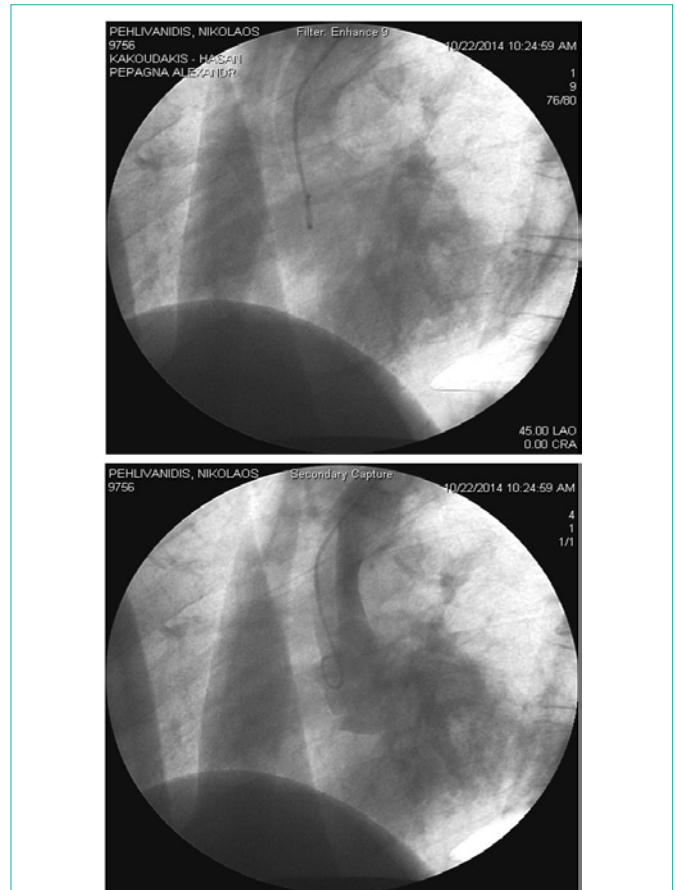


Figure 3: Aortography done on admission day revealing intimal flap in ascending aorta.

on the results of this study, TEE may play an increasingly important role in patients with acute Type A aortic dissection as cardiologists and cardiac surgeons work together to determine the optimal management of any consequent AR (Table 1).

Aortography was previously considered the gold standard test for diagnosis. Aortography identifies the false and true lumens, assesses involvement of the arch vessels, and detects aortic valve insufficiency. However, Aortography is also an invasive, time-consuming technique that requires the use of potentially nephroxic contrast. The European

Table 1:

Stanford Classification
Type Characteristic
Type A Dissection involving the ascending aorta, regardless of the site of the primary tear
Type B Dissection of the descending aorta

Table 2:

De Bakey Classification
Type Characteristic
Type 1 Dissection of the ascending and descending thoracic aorta
Type 2 Dissection of the ascending aorta
Type 3 Dissection of the descending aorta

cooperative study demonstrated that the diagnostic accuracy of Aortography is not as high as originally thought, with sensitivity of 88% and specificity of 94%. Under diagnosis of aortic dissection with Aortography can be due to thrombosis of the false lumen or the simultaneous operation of both the false and true lumens. Noninvasive imaging modalities, such as spiral CT multiplaner Transesophageal Echocardiogram (TEE), and magnetic resonance imaging (MRI) are replacing Aortography for purpose of evaluating for aortic dissection (Table 2).

References

1. Knaut AL, Cleveland JC. Aortic emergencies. *Emergency medicine clinics of North America*. 2003; 21: 817-845.
2. Rushid J, Eisenberg MJ, Topol EJ: Cocaine-induced aortic dissection. *Am Heart J*. 1996; 132:1301-1304.
3. Nienaber CA, von Kodolitsch Y, Nikolas V. The diagnosis of thoracic aortic dissection by noninvasive imaging procedures. *N Engl J Med*. 1993, 328:1-9.
4. Vasile N, Mathieu D, Keita K, Lellouche D, Bloch G, Cachera JP. Computed tomography of thoracic aortic dissection: accuracy and pitfalls. *Journal of computer assisted tomography*. 1986; 10: 211-215.
5. Kawahito K, Adachi H, Yamaguchi A, Ino T. Preoperative risk factors for hospital mortality in acute type A aortic dissection. *The Annals of thoracic surgery*. 2001; 71: 1239-1243.
6. Fleming C, Whitlock E, Beil T, Lederle F. Screening for Abdominal Aortic Aneurysm: A Best-Evidence Systematic Review for the U.S. Preventive Services Task Force. *Annals of Internal Medicine*. 2005; 142: 203.
7. Liao MF, Jing ZP, Bao JM. Role of nitric oxide and inducible nitric oxide synthase in human abdominal aortic aneurysms: A preliminary study. *Chin Med J*. 2006; 119: 312
8. Tsai TT, Nienaber CA, Eagle KA. Acute Aortic Syndromes. *Circulation*. 2005; 112: 3802-3813.