

Case Report

A Case of Toxic Megacolon and Acute Appendicitis in HIV/AIDS

Weledji EP*, Takere MM and Fon P

Department of Surgery, University of Buea, Regional Hospital Limbe, Cameroon

***Corresponding author:** Weledji EP, Department of Surgery, Faculty of Health Sciences, University of Buea, Regional Hospital Limbe, PO Box126, Limbe, S.W. Region, Cameroon**Received:** July 26, 2022; **Accepted:** August 24, 2022;**Published:** August 31, 2022**Abstract**

A 33-year-old African man with HIV/AIDS presented with an acute abdomen associated with rectal bleeding. Colonic decompression, appendicectomy and post operative antiviral therapy for a diagnosed CMV colitis/ megacolon and appendicitis complicating AIDS was effective and avoided the morbidity and high mortality from an emergency subtotal colectomy and ileostomy.

Keywords: Immunodeficiency; Toxic colitis; Cytomegalovirus; Appendicitis; Decompression

Key Clinical Message

Colonic decompression, appendicectomy and post operative antiviral therapy for CMV colitis/megacolon and appendicitis complicating AIDS is effective and avoids the morbidity and high mortality from an emergency subtotal colectomy and ileostomy.

Introduction

Abdominal pain is common in HIV/AIDS and is caused by gastrointestinal malignancies and opportunistic infections. Cytomegalovirus infection (CMV) is the commonest cause resulting in a wide range of conditions including oesophagitis, acalculous cholecystitis, sclerosing cholangitis, small bowel perforation, toxic megacolon, colonic perforation and haemorrhage from mucosal ulcerations (Figure 1), and spontaneous rupture of the spleen [1-3]. In the tropics such as Africa, India and the Far East, most infection takes place in infancy or early childhood by reactivated virus in its mother's genital tract during delivery, or from her milk. These have not been associated with severe symptoms and the infants have the opportunity of developing immunity. Disease caused by CMV was first brought to notice by the congenitally infected infants of more likely women in western temperate climates than those in tropical climates [4] Soon afterward its importance was recognized in immunodeficiency diseases or on immunosuppressive drugs. Similar to other herpes viruses (*herpes simplex viruses 1 and 2*, *Epstein-barr virus*, *varicellar zoster virus*) CMV lies latent after an acute infection and may reactivate at time of stress or immunosuppression to become a more serious infection. Lymphocytosis and lymphadenopathy are less frequent than in the Epstein- Barr virus (EBV) glandular fever. The determination of different classes of antibody may give an indication of the likely time of CMV infection in a particular case [4]. Although virus isolation is difficult and cannot be a rapid method of diagnosis as the growth of the virus is slow, CMV has been isolated from appendix specimens. This raises the possibility that CMV may be causative or a co-factor [5,6]. Toxic megacolon is a severe attack of colitis with total or segmental dilatation of the colon with the diameter of the transverse colon usually greater than 5 -6 cm. A possible pathophysiological mechanism is the destruction of the myenteric plexus and muscle propria of the colon by inflammatory mediators [6-8]. Appendicectomy and colectomy are thus, the commonest

abdominal operations in HIV/AIDS patients. As a presenting AIDS diagnosis and the general health status indicated by the American Society of Anaesthesia (ASA) score to withstand major surgery especially in the face of major abdominal sepsis are the two factors most associated with surgical outcome, careful patient selection for emergency laparotomy is necessary to achieve worthwhile palliation [9].

Case History/Examination

A 33-year- old African man was admitted as an emergency with a history of a gradual onset generalised colicky abdominal pain of two days duration. This was associated with abdominal distension, two episodes of postprandial vomiting and fever. He had no altered bowel habit but the abdominal pain had become constant and more severe with no exacerbating nor relieving factors. He was an HIV-infected patient but not compliant with Highly Active Anti-Retroviral Treatment (HAART). On physical examination, he was alert but lethargic, ill-looking, and clinically dehydrated. The vital signs revealed tachycardia (119 beats/min), tachypnoea (20 breaths/min) and pyrexia (38.3°C) and a normal blood pressure (130/88 mmHg). There was no lymphadenopathy and the chest and cardiovascular examination were unremarkable. He had gross abdominal distension with board-like rigidity, guarding and rebound tenderness in the right iliac fossa overlying McBurney's point. The percussion note was tympanic and bowel sounds were hypoactive. Rectal examination was normal. A plain abdominal x-ray (Figure 2) showed dilated large bowel and an erect chest x-ray showed no pneumoperitoneum. Apart for a thrombocytopenia of $104 \times 10^3 / \text{ml}$ (n: $150-400 \times 10^3 / \text{ml}$, the full blood count and serum biochemistry were within normal limits. The differential diagnosis included a localized perforation of the appendix with associated ileus. Following resuscitation with intravenous fluids and broad spectrum antibiotics he underwent a laparotomy. Intraoperatively, there was no free fluid in the peritoneal cavity but a grossly dilated colon (5 cm d) extending to the rectum with no signs of imminent perforation. The appendix appeared abnormally long, oedematous and inflamed (Figure 2). Decompression of the colon per anum with a sigmoidoscope revealed copious purulent necrotic, mucus fluid. These findings were consistent with a toxic megacolon and acute appendicitis complicating an infective (CMV) colitis. As the base of the appendix and caecum were healthy an appendicectomy

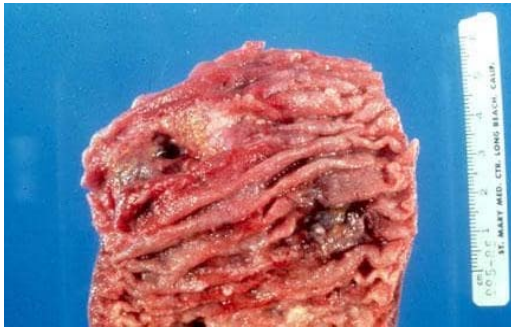

Figure 1: Macroscopic view of CMV Colitis showing mucosal ulceration (with permission-Cho et al. [11]).

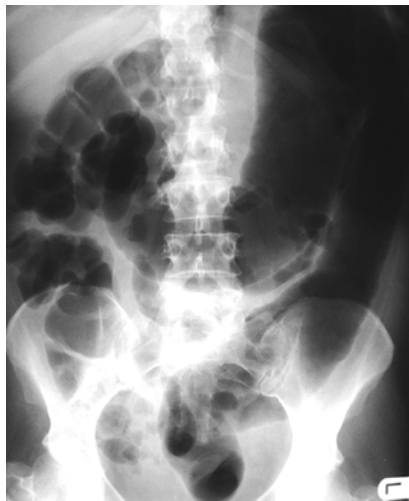


Figure 2: Plain Abdominal X-ray of toxic megacolon.

was safely done (Figure 3) and a modified Foley catheter tube per anum left in-situ to allow continuous drainage. Due to limited resources a histopathology report on the appendix specimen could not be sought. He was commenced on the anti-viral acyclovir 200mg tds on the 1st post-operative day and, following an episode of massive rectal bleeding on the 2nd postoperative day the symptoms and signs of the toxic megacolon rapidly improved. He was recommenced on HAART and discharged on the 10th postoperative day with no wound complications. He was clinically well at 6 weeks follow-up.

Discussion

Pathology occurring in HIV/AIDS patients may be classified into (a) diseases with a definitive association with HIV and (b) coincidental diseases seen in the general population especially as HIV/AIDS patients on HAART are living longer. The commonest presentation in AIDS requiring laparotomy is toxic megacolon, small bowel obstruction and localized peritonitis [1,9]. The commonest disease processes, CMV colitis, B-cell lymphoma, acute appendicitis with CMV infection and atypical *Mycobacterium Avium Intracellulare* (MAI) infection are quite different from that seen in the non- HIV population [1,9,10]. The case demonstrates a good clinical outcome following early intervention on an HIV/AIDS patient with most probable toxic CMV colitis and appendicitis.

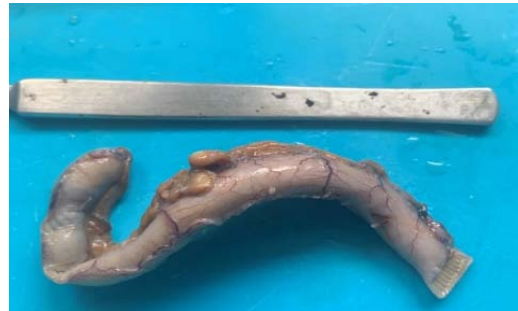

Figure 3: CMV appendicitis specimen.

The patient benefited from an appendectomy and sigmoidoscopic decompression of the toxic megacolon. The presumptive diagnosis of a CMV colitis complicating AIDS was corroborated by its response to post-operative anti- viral (acyclovir) treatment [11]. The morbidity and reported high 30 day mortality (71%) from an emergency subtotal colectomy and an ileostomy in these patients were avoided [12]. It is important to note that although abdominal pain is common in patients with AIDS, less than 1% of patients will need an emergency laparotomy [10]. Lymphadenopathy from MAI or lymphoma can result in appendicitis or jaundice by obstructing the appendiceal ostium or porta hepatis, respectively. These patients are often difficult to manage as it is often unclear if they need an immediate laparotomy. Patients may also present with less severe abdominal pain from cryptosporidial infection of the gut and a few with CMV, that does not amount to an emergency, and up to a third of patients in whom no associated infections are uncovered [13]. It is important to have close liaison with the AIDS physician to exclude pre-terminal cases and keep down negative laparotomies to acceptable rate [13,14]. Because negative laparotomy is not too infrequent for a patient with undiagnosed abdominal pain, there is increased indication for diagnostic laparoscopy. Care should, however, be taken during laparoscopy by using disposable ports with a vestibular flange to prevent splash back, and by deflating the abdomen prior to port withdrawal because any aerosol emanating from the port entry wound will harbor HIV [1,13,14]. Perioperative deaths commonly occur in HIV/AIDS patients with generalized peritonitis especially as general anaesthesia results in depression of cell-mediated immunity and AIDS progression [1,10]. The current lower operative mortality for emergency surgery on AIDS patients (11% in one series) may be due to early intervention before colonic perforation ensues and active treatment at every level [10]. Also this case demonstrates that a colonic decompression and an appendectomy plus post operative viral CMV treatment may suffice in treating CMV toxic colitis with megacolon [11,15]. Although gastrointestinal involvement with CMV infection is uncommon in immunocompetent patients, similar case reports on immunocompetent patients using a similar treatment approach except for appendectomy yielded similar outcome [11,15-17]. The adjuvant treatment with HAART would improve the general resistance to infection and nutritional status to withstand surgery [18]. Later deaths are due to the progression of AIDS [10]. Surgery confers least benefit in patients with acute abdominal pain from MAI infection or lymphoma because of the higher degree of immunosuppression (<200 CD4 cells/ul) [3,10,19]. As HIV/AIDS patients are not homogeneous, surgical intervention

in selected patients for life-threatening surgical correctable disease as appendicitis, refractory toxic megacolon or intussusception is justifiable [1,9]. However, the pathophysiological consequences of advanced disease (immunosuppression, malnutrition, infections and neoplasms) requires the scaling down of the magnitude of surgery to an acceptable and safe level.

Conclusions

Early suspicion and diagnosis of CMV colitis in HIV/AIDS is essential as early conservative anti-viral treatment may prevent the potentially fatal complication of toxic megacolon or massive haemorrhage. Otherwise, colonic decompression of the toxic megacolon and an appendectomy for the usually associated CMV appendicitis should have minimal morbidity and mortality.

Conflict of Interests

The authors declare no competing interests.

Author Contributions

EPW was the surgeon and main author, MMT and PF contributed to the per-operative care and literature search.

Consent

Written informed consent from the patient was granted to write and publish the paper.

Data Availability Statement

The data that support the findings of this study are available on request from the corresponding author. The data are not publicly available due to privacy or ethical restriction.

ORCID

Elroy Patrick Weledji, <https://orcid.org/0000-0002-0473-4883>.

References

- Weledji EP, Nsagha D, Chichom A, Enowrock G. Gastrointestinal surgery and the acquired immune deficiency syndrome. *Annals of Medicine and Surgery*. 2015; 4: 36-40.
- Wilson SE, RobinsoG, Williams RA, et al. Acquired immune deficiency syndrome (AIDS): Indications for abdominal surgery. *Ann Surg*. 1989; 210: 428-34.
- Kaplan LD. AIDS-associated lymphomas. *Infect Dis Clin North Am*. 1988; 525-553.
- MacDonald H, Tobin JO. Congenital Cytomegalovirus Infection: a Collaborative Study on Epidemiological, Clinical and Laboratory Findings. *Developmental Medicine & Child Neurology*. 1978; 20: 471-482.
- Whitley R, Jacobson MA, Freidberg DN. Guidelines for the treatment of cytomegalovirus diseases in patients with AIDS in the era of potent antiretroviral therapy: recommendations of an international panel. *Arch Int Med*. 1998; 158: 957-69.
- Chetty R, Roskell DE. Cytomegalovirus infection in the gastrointestinal tract. *Journal of Clinical Pathology*. 1994; 47: 968-972.
- Orloff JJ, Saito R, Lasky S, Dave H. Toxic megacolon in cytomegalovirus colitis. *Am J Gastroenterol*. 1989; 84: 794-797.
- Beaugerie L, Ngô Y, Goujard F, Gharakhanian S, Carbonnel F, Luboinski J, et al. Etiology and management of toxic megacolon in patients with human immunodeficiency virus infection. *Gastroenterology*. 1994; 107: 858-863.
- Smit S. Guidelines for surgery in the HIV patients. *Continuous Medical Education (CME)* 2010; 28: 8.
- Miles AJC, Wastell C. AIDS and the general surgeon. *Recent Adv Surg*. 1991; 14: 85-98.
- Cho JH, Choi JH. Cytomegalovirus ileo-pancolitis presenting as toxic megacolon in an immunocompetent patient: A case report. *World journal of clinical cases*. 2020; 8: 552-559.
- Wexner SD. CMV ileocolitis and Kaposi's sarcoma in AIDS pp217-22. In: Fazio VW, editor. *Current therapy in colon and rectal surgery*. Toronto: BC Decker: 1990.
- Dua RS, Wajed SA, Winsler MC. Impact of HIV and AIDS on surgical practice. *Ann R Coll Surg Engl* 2007; 89: 354-8.
- Cochrane JPS, Wastell C. In Cochrane JPS, Wastell C, editors. *The impact of HIV on surgical practice*. *Studies in Surgery (1)* Royal College of Surgeons of England: 1992.
- Khan A, Al Mussallam B, Al Shakweer W, Al Badri R. Cytomegalovirus associated toxic megacolon in an immunocompetent host. A case report. *Eur Surg*. 2010; 42: 53-57.
- Sakamoto I, Shirai T, Kamide T, Igarashi M, Koike J, Ito A, et al. Cytomegalovirus enterocolitis in an immunocompetent individual. *Journal of clinical gastroenterology*. 2002; 34: 243-246.
- Buckner FS, Pomeroy C. Cytomegalovirus disease of the gastrointestinal tract in patients without AIDS. *Clinical infectious diseases : an official publication of the Infectious Diseases Society of America*. 1993; 17: 644-656.
- Horberg AM, Hurley LB, Klein DB. Surgical outcome in HIV-infected patients in the era of highly active antiretroviral therapy. *Arch Surg*. 2006; 141:1238-45.
- Steinberg JJ, Bridges N, Feiner HD, Valensi Q. Small intestinal lymphoma in three patients with acquired immune deficiency syndrome. *The American journal of gastroenterology*. 1985; 80: 21-6.