

Case Report

One of Jehovah's Witnesses with Gangrenous Foot and Severe Anemia: A Case Report

Ciubara R^{1*}; Severin G²; Darciuc R³; Gotonoaga E³; Savan V⁴

¹Anesthesia and Intensive Care Department, Medpark International Hospital, Chisinau, Republic of Moldova

²Anesthesia and Intensive Care Department, Municipal Clinical Hospital Nr.1 Gheorghe Paladi, Chisinau, Republic of Moldova

³Cardiology Department, Medpark International Hospital, Chisinau, Republic of Moldova

⁴Cardiovascular and Thoracic Anesthesia and Intensive Care, University Hospital Center Grenoble Alpes, Grenoble, France

***Corresponding author: Ciubara R**

Anesthesia and Intensive Care Department, Medpark International Hospital, 24 Andrei Doga Street, Chisinau, MD-2024, Republic of Moldova.

Tel: +373 79084040

Email: rciubara2@gmail.com

Received: April 24, 2023

Accepted: May 29, 2023

Published: June 05, 2023

Introduction

Jehovah's Witnesses are well known in the medical world for their refusal of accepting blood transfusions. The refusal is based on their understanding of Bible verses like Genesis 9:3-4, Leviticus 17:10-11 and Acts 15:29. They do not accept transfusion of allogenic whole blood, red blood cells, thrombocytes, leukocytes and plasma, do not accept preoperative autologous blood collection and storage for later reinfusion. Accepting some minor components is a matter of a personal decision [1]. In some clinical scenarios the care for a patient who is one of Jehovah's Witnesses could be challenging.

We present a case of a patient with gangrenous foot and severe anemia who underwent leg amputation without any transfusion of blood products. Consent from the patient was obtained to publish the report.

Case Description

A 66-year-old woman who is one of the Jehovah's Witnesses, was admitted in November 2015 to Medpark International

Abstract

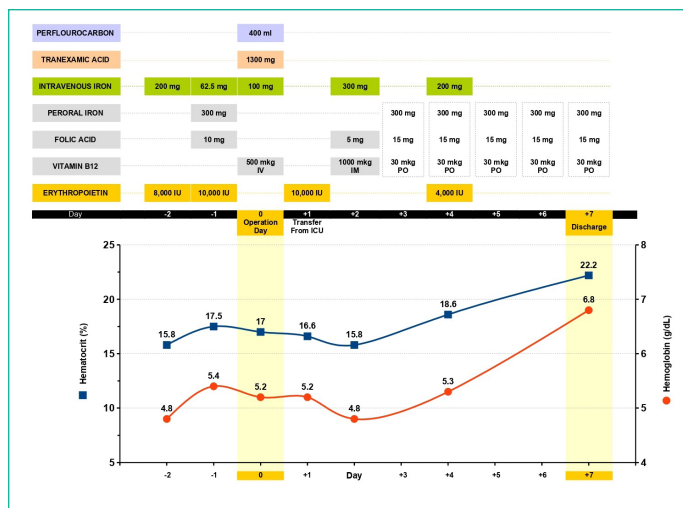
There are an increasing number of patients who are refusing blood transfusions for several reasons, the most widespread among them being Jehovah's Witnesses.

We present a case of a 66-year-old woman admitted to the hospital with gangrene as a complication of the diabetic foot. The hemoglobin level was 4.8g/dl, hematocrit was 15.8% and mean corpuscular volume was 77.1 fL. She needed urgent surgery to amputate her foot. Being one of Jehovah's Witnesses, she refused blood transfusions. A multimodal blood management approach was applied, and the patient underwent leg amputation without transfusion of any blood product. The treatment strategy is discussed.

Keywords: Amputation; Anemia; Gangrene; Jehovah's witnesses; Perfluorocarbon; Case report

Hospital, Chisinau, Republic of Moldova, with a gangrenous foot requiring urgent surgery. She also had poorly controlled type 2 diabetes mellitus under insulin therapy (HbA1C - 9%). The patient was transferred from other hospital because of management problems involving extremely severe anemia (hemoglobin – 4.8g·dL⁻¹) and her refusal of blood products transfusion. Prior to the transfer 200mg intravenous iron sucrose and 8,000 IU of recombinant human erythropoietin (rHuEPO) alfa were administered.

At admission, the patient had signs of well compensated severe anemia (hemoglobin – 5.4g·dL⁻¹, erythrocytes – 2.27x10¹²·L⁻¹, hematocrit – 17.5%, mean corpuscular volume – 77.1fL, serum iron – 5.8mmol·L⁻¹) with normal lactate level and without tachycardia or ischemic changes on ECG. In addition, the laboratory findings showed leukocytosis - 14.2x10⁹·L⁻¹, increased C reactive protein – 48 g·L⁻¹ and a moderately decreased kidney function (estimated glomerular filtration rate (eGFR) – 52ml·min⁻¹). She received oxygen support, intravenous iron sucrose, folic acid, rHuEPO and vitamin B12 (Figure 1).



The amputation of the right leg in the lower third of the thigh was performed under spinal anesthesia. We used perfluorocarbon solution (Perftoran®, Perftoran NPO OAO, Russian Federation) as an oxygen-carrying agent, 200ml before and 200ml after the intervention. Intravenous tranexamic acid ($15\text{mg}\cdot\text{kg}^{-1}$) was given prior to incision and $1.5\text{mg}\cdot\text{kg}^{-1}\cdot\text{h}^{-1}$ during the surgery (total dose – 1300mg). Meticulous hemostasis was applied with only 30ml blood loss. The next day the patient was discharged from intensive care unit to continue the treatment in the surgical department (Figure 1). One week later the hemoglobin level increased to $6.8\text{g}\cdot\text{dL}^{-1}$ (hematocrit - 22.2%, mean corpuscular volume - 88.4fl) and she was discharged home.

Discussion

There are an increasing number of patients who are refusing blood transfusion for several reasons, the most widespread among them is belonging to the Jehovah's Witnesses. In some cases, they can present with severe or critical anemia. The refusal to receive a blood transfusion, even in a critical situation, can be a potentially fatal decision. This is where Jehovah's Witnesses differ as patients.

Lower hemoglobin level is associated with an increased mortality risk [2,3], but there are multiple strategies developed to provide care for the patients who refuse blood transfusions. One of them is to combine interventions in a comprehensive, multidisciplinary and multimodal blood management program. The program includes treatments to enhance endogenous erythropoiesis, reduce blood loss, increase oxygen delivery, reduce oxygen consumption and avoid iatrogenic anemia [4]. The approach improves outcomes without violating patient's beliefs and values.

In our opinion the severe anemia in our patient was caused by iron deficiency (serum iron – $5.8\text{mmol}\cdot\text{L}^{-1}$), chronic infection and moderately decreased kidney function (eGFR - $52\text{ml}\cdot\text{min}^{-1}$).

We started oxygen therapy at the admission to enhance tissue oxygenation. Also, we administered rHuEPO, iron, folate and vitamin B12 to assure endogenous erythropoiesis.

The majority of the authors recommend at least 40,000 IU of erythropoietin per week (or $300\text{--}600\text{ IU}\cdot\text{kg}^{-1}\cdot\text{day}^{-1}$) [5], some recommend up to $40,000\text{ IU}\cdot\text{day}^{-1}$ [4]. We administered 32,000 IU week⁻¹ due to limited supplies of rHuEPO in the hospital at that moment.

Intravenous regimen with iron sucrose varies from 100mg daily to high-dose regimen with 500mg [4,6] or with iron carboxymaltose $20\text{mg}\cdot\text{kg}^{-1}$ daily (maximum 1000mg) [7]. During

the hospital stay a total dose of 862.5mg intravenous iron sucrose was administered to the patient, following our institutional protocol of 100mg intravenous iron sucrose every day or 200mg every second day (Figure 1).

Vitamin B12 and folic acid were administered empirically to provide substrate for erythropoiesis.

In the preoperative period the patient had well compensated severe anemia. Nevertheless, there was a need for surgical intervention and the survival of the patient was questioned due to the possible perioperative blood loss and the development of the fatal anemia. At that time, we had access to the oxygen-carrying agents as hemoglobin solution and perfluorocarbon. So, we considered the use of the bridge therapy with an oxygen-carrying agent to improve the outcome. The strategy was discussed with the patient. She refused the use of the hemoglobin solution (Hemopure®, OPK Biotech, Cambridge, MA, USA) but accepted the use of the perfluorocarbon (Perftoran®) as an approach [8]. We administered 200ml Perftoran® before and 200ml after the surgery and did not give additional doses due to the absence of tachycardia, no ischemia on ECG and stable lactate levels.

To minimize blood loss during surgery our approach was: the use of the spinal anesthesia [9], administration of intravenous tranexamic acid as an antifibrinolytic agent [10], the use of the tourniquet and meticulous surgical hemostasis. As a result, the blood loss was 30ml and there was no important hemoglobin decrease after surgery (Figure 1).

From the third day, we continued iron therapy orally in a dose of $300\text{mg}\cdot\text{day}^{-1}$ (using a polypill with 100mg ferrous sulfate, 5mg folic acid and 10mcg vitamin B12, that was administered three times a day). Our argument was the lack of the source of infection. The presence of the infection is actively contributing to the synthesis of hepcidin in considerable concentrations, a protein that prevents the absorption of iron in the gut. It has also been observed that a single dose of erythropoietin could rapidly decrease the concentration of hepcidin [11]. Our patient has received more than one.

The hemoglobin level increased on the seventh day after the surgery up to $6.8\text{g}\cdot\text{dL}^{-1}$ (or + $2\text{g}\cdot\text{dL}^{-1}$).

Conclusions

A comprehensive, multidisciplinary and multimodal blood management program is efficient when patients refuse blood transfusions. Critical anemia of $5\text{g}\cdot\text{dL}^{-1}$ is not always an absolute contraindication for surgery in those patients.

Using a multimodal blood management approach was possible to perform the leg amputation in a patient with severe anemia and to discharge her home one week after the surgery.

References

1. Religious and Ethical Position on Medical Therapy and Related Matters. Watch Tower Bible and Tract Society of Pennsylvania. 2012.
2. Carson JL, Noveck H, Berlin JA, Gould SA. Mortality and morbidity in patients with very low postoperative Hb levels who decline blood transfusion. *Transfusion*. 2002; 42: 812-8.
3. Shander A, Javidrooz M, Naqvi S, Aregbeyen O, Caylan M, et al. An update on mortality and morbidity in patients with very low postoperative hemoglobin levels who decline blood transfusion. *Transfusion*. 2014; 54: 2688-95.

4. Shander A, Goodnough TL. Management of anemia in patients who decline blood transfusion. *Am J Hematol.* 2018; 93: 1183-1191.
5. Charles A, Purtill M, Napolitano LM. Recombinant human erythropoietin in severe anaemia: issues of dosing and duration. *Anaesth Intensive Care.* 2006; 34: 793-796.
6. Blaustein DA, Schwenk MH, Chattopadhyay J, Avram MM. Recent experience with high-dose intravenous iron administration. *Kidney International.* 2006; 70: S26-S29.
7. Spahn DR, Schoenrath F, Spahn GH, Seifert B, Stein P, et al. Effect of ultra-short-term treatment of patients with iron deficiency or anaemia undergoing cardiac surgery: a prospective randomised trial. *Lancet.* 2019; 393: 2201-2212.
8. Maevsky E, Ivanitsky G, Bogdanova L, Axenova O, Karmen N, et al. Clinical results of Perftoran application: present and future. *Artif Cells Blood Substit Immobil Biotechnol.* 2005; 33: 37-46.
9. Richman JM, Rowlingson AJ, Maine DN, Courpas GE, Weller JF, et al. Does neuraxial anesthesia reduce intraoperative blood loss? A meta-analysis. *J Clin Anesth.* 2006; 18: 427-435.
10. Ker K, Edwards P, Perel P, Shakur H, Roberts I. Effect of tranexamic acid on surgical bleeding: systematic review and cumulative meta-analysis. *BMJ.* 2012; 344: e3054.
11. Ashby DR, Gale DP, Busbridge M, Murphy KG, Duncan ND, et al. Erythropoietin administration in humans causes a marked and prolonged reduction in circulating hepcidin. *Haematologica.* 2010; 95: 505-8.