

## Case Report

# One Case of Unilateral Intractable Localized Plaque Psoriasis Treated by Herbal Thread Moxibustion Combined with Blood Pricking

Jing LJ<sup>1\*</sup>, Yiqian L<sup>2</sup> and Qiong XZ<sup>1</sup>

<sup>1</sup>Department of Acupuncture and Rehabilitation, The First Affiliated Hospital of Guangzhou Medical University, Guangzhou 510000, Guangdong, China

<sup>2</sup>Guangzhou University of TCM, Guangzhou 510000, Guangdong, China

\*Corresponding author: Dr. Lu Jing Jing, Department of Acupuncture and Rehabilitation, the First Affiliated Hospital of Guangzhou Medical University. Guangzhou 510000, Guangdong, China

Received: August 30, 2022; Accepted: October 03, 2022; Published: October 10, 2022

## Abstract

Chronic plaque psoriasis is an inflammatory disease. Due to the complex interaction of genetic and environmental factors, immune related cytokine imbalance leads to abnormal epidermal proliferation. A 73 year old female patient with 20-year-old intractable psoriasis improved significantly after 2 weeks of treatment with traditional Zhuang medicine. Moxibustion with medicinal thread combined with pricking and bloodletting may be a good choice for the treatment of psoriasis in the future.

**Keywords:** Psoriasis; Zhuang medicine

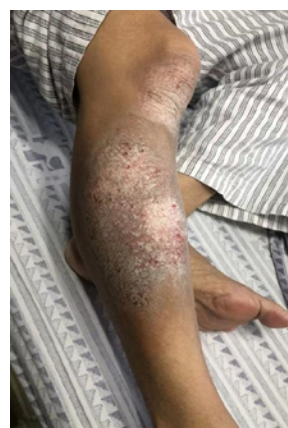## Case Report

Plaque psoriasis lesions are characterized by symmetrical distribution and rarely occur on one side. In the treatment process, the skin lesions on the trunk subside quickly, and the skin lesions on the limbs, especially the lower leg, subside slowly because of resistance to treatment [1]. One case of unilateral localized plaque psoriasis was treated in our department. The report is as follows.

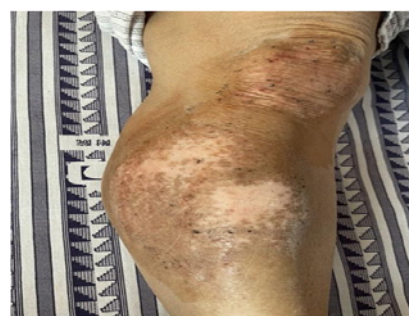A 73 year old female, visited the Department of acupuncture and moxibustion of our hospital on January 4, 2022 because of repeated erythema, scale and itching of the right leg for 20 years. 20 years ago, the patient had no obvious inducement to develop a rash on the right leg extension side. At first, it was the size of soybeans, and then it gradually expanded to the knee and back of the foot, accompanied by scale and pruritus. He was once diagnosed as “psoriasis” in the dermatological hospital, and no obvious relief was found after medication (the specific medication is unknown). In the past 20 years, he has been seen in the outpatient department for many times, and the above symptoms still recur after improvement. There were no patients with similar diseases in the family who had undergone cholecystectomy before.

Physical examination: Generally speaking, no obvious abnormality is found in all system examinations. Dermatological examination: dark red spots and papules on the extended side of the right leg, covered with thick layer of white scales, the skin lesion extends to the knee and 1/3 of the lower leg, and drip like bleeding can be seen by scraping the scale gently (Figure 1A).

Laboratory and auxiliary examinations: routine blood, urine and feces, coagulation function, blood biochemistry and serum protein electrophoresis showed no obvious abnormalities. Chest CT plain scan considered bronchiectasis of both lungs, and the combined infection was better than the previous absorption. Histopathological examination of skin lesions: incomplete keratinization of epidermis, neutrophil infiltration in local areas, thinning of granular layer,



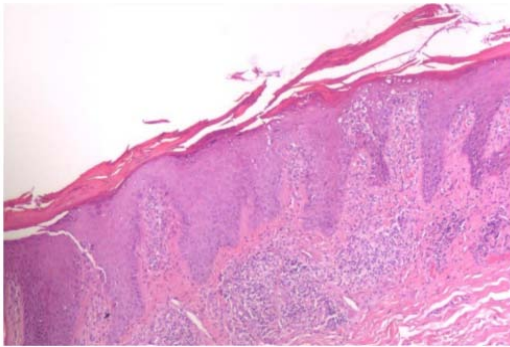
**Figure 1A:** Dark red maculopapular rash on the extended side of right lower leg, covered with thick layer of white scales, with the lesion extending to the knee and lower 1/3 of the lower leg.



**Figure 1B:** After 2 weeks of treatment, the skin lesions subsided significantly.

pestle like elongation of epithelial feet, and a large number of chronic inflammatory cells in the superficial dermis (Figure 2).

**Diagnosis:** psoriasis of right lower leg **Treatment:** Zhuang medicine thread moxibustion (Figure 3) combined with blood



**Figure 2:** Epidermal keratinization is incomplete, neutrophil infiltration is seen locally, the granular layer is thin, the epithelial foot is elongated like a pestle, and a large number of chronic inflammatory cells are infiltrated in the superficial dermis.

pricking therapy, once a day, five times a week (qw1-qw5), for 2 weeks. After treatment, the skin lesions at the affected area were significantly improved, the scales were basically completely shed, and the normal skin was exposed at the rash site, leaving only pigmentation and white spots (Figure 1B). After 2 months of follow-up, there was no recurrence, and the skin pigmentation gradually subsided after 1 month of continuous intermittent treatment (1-2 times a week). This patient is still in follow-up.



**Figure 3:** Zhuang medicine thread moxibustion.

### References

1. Wang Na, Shan Xiaofeng, Yang Baoqi, Wu Weizhi, Liu Suqin, Yan Shifu. Evaluation of the efficacy of NB-UVB combined with 8-MOP PUVA in the treatment of leg plaque psoriasis. *Chinese Journal of leprosy dermatology*. 2016; 32: 351-353.