

Case Report

A Rare Fracture of OS Trigonum, Treated by Posterior Ankle Arthroscopy

Zhong T, Wang Z*, Jin P, Zhu Y and Zhang J

Department of Foot & Ankle Surgery, the Third People's Hospital of Dalian, Dalian 116033, China

*Corresponding author: Zhijian Wang, Department of Foot & Ankle Surgery, The Third People's Hospital of Dalian, No.40 Qianshan Road, Ganjingzi District, Dalian 116033, China

Received: January 24, 2022; Accepted: February 15, 2022; Published: February 22, 2022

Abstract

The main cause of the posterior ankle impingement is due to the injury of the os trigonum and the posterior process of the talus. Excessive plantar flexion of the ankle will cause injury of the os trigonum. We report a case of a female patient with the fracture of os trigonum, which is extremely rare. The patient underwent arthroscopic excision of the os trigonum through the posterior ankle arthroscopy in the prone position. After 3 weeks, the pain of the ankle joint disappeared and was able to walk normally. The symptoms did not relapse until 34 months after the operation.

Keywords: Fracture; Talus; Arthroscopy

Introduction

The os trigonum is the one of largest and most common accessory bones in the foot and ankle and is located behind the talus. The probability of occurrence is 1-25% [1-3]. Usually, the os trigonum does not cause symptoms. It is occasionally found in the X-ray examination of the ankle joint. Sometimes it is confused with the talus posterior process fracture. When the ankle is excessive plantar flexion, the posterior border of the tibia and the calcaneus impact and result in symptoms behind the ankle joint. The symptoms have been referred to by a variety of names, including talar compression syndrome, posterior ankle impingement syndrome, posterior tibiotalar impingement syndrome, nut-cracker type impingement, os trigonum syndrome, and hindfoot impingement syndrome. In all patients with the os trigonum syndrome, the fracture of the os trigonum is extremely rare. Computed tomography (CT) and Magnetic resonance imaging (MRI) are helpful for the diagnosis of the fracture of the os trigonum. Although conservative treatment can achieve good therapeutic effect, the recovery time may be longer. We report a case of the fracture of the os trigonum, which is treated with posterior ankle arthroscopy.

Case Presentation

In 2015, a 56-year-old female patient sprained his right ankle while running. She described the hyper-plantarflexion of the ankle joint during a sprain. She had pain in posterior ankle and was unable to bear weight. The symptoms were not relieved after 1 weeks of rest.

Physical examination revealed swelling and tenderness in the posterior ankle. The pain was aggravated when the ankle joint was passively flexed.

Lateral radiograph of the ankle showed free bone with sharp edge behind the talus (Figure 1). But this bone mass was unable not to be distinguished from the fracture of the posterior process of the talus. CT and MRI were required to identify them. Sagittal scans of CT showed the fracture of the os trigonum. The os trigonum was divided into two parts. The fracture surfaces were neat and sharp (Figure 2). MRI showed soft tissue edema behind the ankle, and high signal

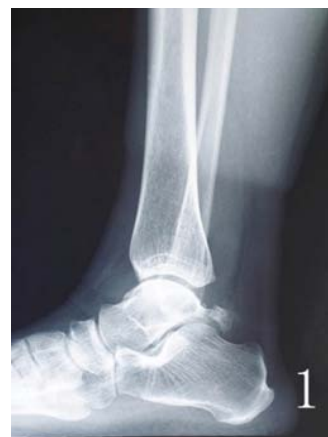

Figure 1: Lateral radiograph showing free bone behind the talus.

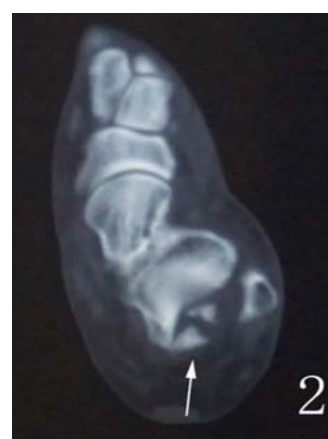

Figure 2: CT axial scans showing the neat and sharp fracture surface.

intensity was seen in the os trigonum, accompanied by the fracture. But there was no abnormal signal in the talus (Figure 3).

The patient was taken prone position, and posterolateral and

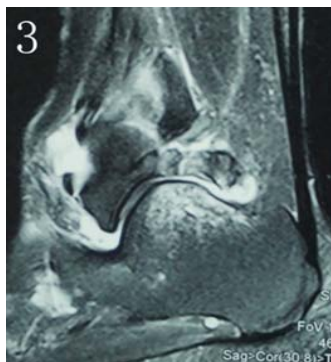

Figure 3: MRI showing high signal in the os trigonum and the normal signal in the talus.

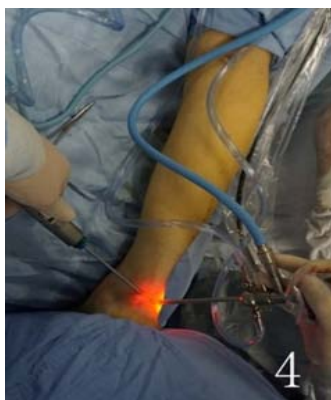

Figure 4: Posterior ankle arthroscopy.

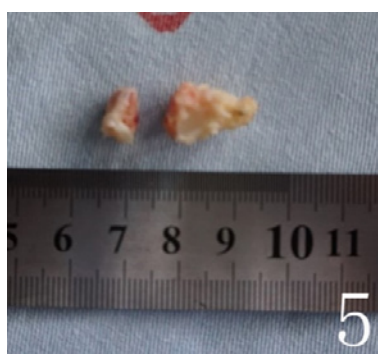


Figure 5: Two parts of the os trigonum.

posteromedial approaches were performed with posterior ankle arthroscopy (Figure 4). The soft tissue around the os trigonum was loosened with a shaver, and one bone fragment was removed every time (Figure 5). Attention should be paid to identifying the flexor hallucis longus tendon and operating on the lateral side of the flexor pollicis longus tendon, so as to avoid injuring the posterior tibial vessels and nerves. Fluoroscopy confirmed the posterior triangle bone was completely removed (Figure 6 and 7).

The patient was able to walk with weight after 3 days. After 3 weeks, the pain disappeared and was able to walk normally. The symptoms did not relapse for 34 months of follow-up.

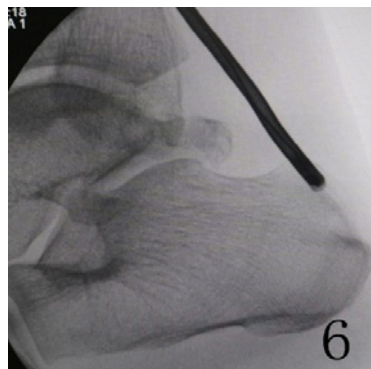


Figure 6: Fluoroscopy before surgery.

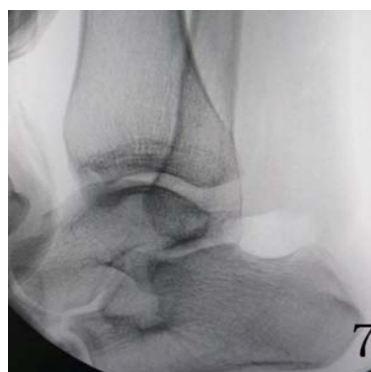

Figure 7: Fluoroscopy after surgery.

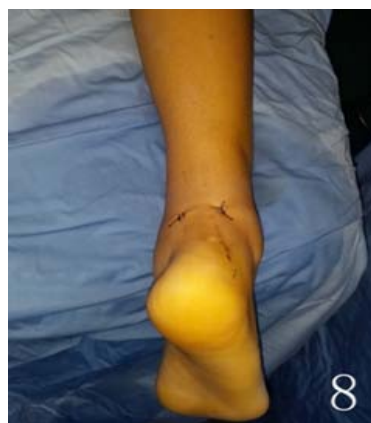

Figure 8: The incisions of surgery.

Discussion

The os trigonum is located at the posterolateral side of the talus, the largest and most common accessory bone in the foot and ankle region. Excessive plantar flexion of the ankle, the posterior tibia and calcaneus will impact on the os trigonum, resulting in pain and other symptoms. The symptoms are known as “os trigonum syndrome”, and there will be persistent pain in the posterior ankle. In all patients with os trigonum syndrome, the fracture of the os trigonum is extremely rare [4-7]. For differential diagnosis, CT and MRI examination are

necessary. It can show that the fracture line is clear, and its edges are neat and sharp.

Conservative treatment can cure the fracture of the os trigonum successfully. But it may lead to nonunion, and rehabilitation takes a long time. Posterior ankle arthroscopy for the treatment of os trigonum syndrome has been widely used recently because it gives a good visualization of lesions and working space. The posterolateral and posteromedial approaches of posterior ankle arthroscopy were first described by Van Dijk [8]. Through these approaches, satisfactory results can be achieved and the incision is small (Figure 8). The posterior ankle arthroscopy can remove the fractured fragments of the os trigonum and relieve symptoms quickly.

Conclusion

The fracture of the os trigonum is extremely rare and can cause os trigonum syndrome. The posterior ankle arthroscopy can remove the fractured fragments and achieve satisfactory results.

References

1. Mellado JM, Ramos A, Salvado E, Camins A, Danus M, Sauri A. Accessory ossicles and sesamoid bones of the ankle and foot: imaging findings, clinical significance and differential diagnosis. *Eur Radiol*. 2003; 13: L164-177.
2. Anwar R, Nicholl JE. Non-union of a fractured os trigonum. *Injury*. 2005; 36: 267-270.
3. Bureau NJ, Cardinal E, Hobden R, Aubin B. Posterior ankle impingement syndrome: MR imaging findings in seven patients. *Radiology*. 2000; 215: 497-503.
4. Mouhsine E, Djahangiri A, Garofalo R. Fracture of the non fused os trigonum, a rare cause of hindfoot pain. A case report and review of the literature. *Chir Organi Mov*. 2004; 89: 171-175.
5. Lapidus PW. A note on the fracture of os trigonum. Report of a case. *Bull Hosp Joint Dis*. 1972; 33: 150-154.
6. Kose O, Okan AN, Durakbasa MO, Emrem K, Islam NC. Fracture of the os trigonum: a case report. *J Orthop Surg (Hong Kong)*. 2006; 14: 354-346.
7. Escobedo EM, MacDonald TL, Hunter JC. Acute fracture of the os trigonum. *Emerg Radiol*. 2006; 13: 139-141.
8. Van Dijk CN, Scholten PE, Krips R. A 2-portal endoscopic approach for diagnosis and treatment of posterior ankle pathology. *Arthroscopy*. 2000; 16: 871-876.