

Clinical Image

Foreign Body Aspiration as a Cause of Hemoptysis

Almeida S*, Valentim M, Neto C, Cerol M,
Gameiro A and Cabrita M

Department of Internal Medicine, Hospital Distrital de
Santarém, Portugal

*Corresponding author: Almeida S, Avenida Bernardo
Santareno, Santarém, Portugal

Received: January 30, 2019; Accepted: February 11,
2019; Published: February 18, 2019

Clinical Image

A 55-year-old female with no previous significant medical history was admitted to the emergency department presenting hemoptoic cough for the last 2 days.

On presentation she was tachypneic (22 breaths/min), with mild hypoxaemia (95% oxygen saturation on room air) and with abolished murmur in the lower right hemithorax. Her complete blood count (white blood cell $7.4 \times 10^9/L$, hemoglobin 13.7 g/dL, platelet $211 \times 10^9/L$) and C reacting protein (0.19 mg/dL) were normal, but the thoracic X-ray showed atelectasis of the lower right lung.

The suspicion of a lung neoplasm motivated the performance of a CT scan that showed signs of a chronic inflammatory process (Figure 1).

She underwent bronchoscopy for definitive diagnosis, and the procedure revealed the presence of a foreign body that was removed (Figure 2) without complications.

After bronchoscopy, the patient's symptoms improved rapidly and she was discharged.

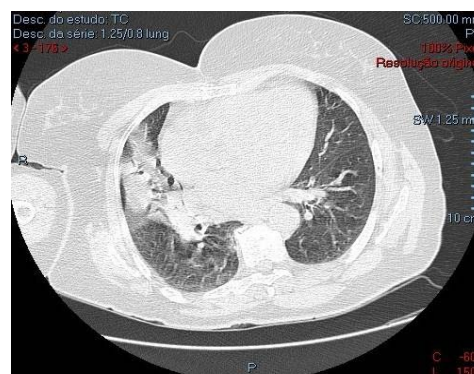


Figure 1:

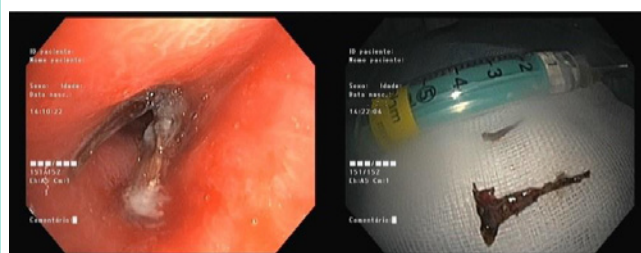


Figure 2: